UNIVERSITY MICROFILMS, INC., ANN ARBOR, MICH.

L. C. Card no. Mic 58-7796

VOTAW, Charles Lesley. CERTAIN ANATOMICAL AND PHYSIOLOGICAL RELATIONS OF THE HIPPOCAMPUS.

University of Michigan, Ph. D., 1958
Anatomy

Negative microfilm received from University.

CERTAIN ANATOMICAL AND PHYSIOLOGICAL RELATIONS OF THE HIPPOCAMPUS

by

Charles L. Votaw

A dissertation submitted in partial fulfillment
of the requirements for the degree of
Doctor of Philosophy in the
University of Michigan
1958

Doctoral Committee:

Professor Elizabeth C. Crosby, Chairman
Professor Burton L. Baker
Associate Professor Lee O. Case
Professor Wilfrid T. Dempster
Professor Bradley M. Patten
Professor Konstantin Scharenberg
Professor Russell T. Woodburne

Abstract

CERTAIN ANATOMICAL AND PHYSIOLOGICAL RELATIONS OF THE HIPPOCAMPUS

by Charles L. Votaw

This experimental investigation has been concerned with the possible production of somatic motor movements by stimulation of the hippocampus, and with the effects of the removal of portions or of all of this area. As an essential part of the program, the fiber connections of the hippocampus have been studied. The main objects of this investigation have been to ascertain whether this brain region can act as an independent second motor area, and to increase our present knowledge of its functions.

Twelve monkeys (Macaca mulatta and Macaca cynamolgus) were subjected to sterile operative procedures. Stimulation of the hippocampus was carried out both by direct application of the electrode and with the use of a stereotaxic apparatus. The movements obtained were noted and photographed. Selected lesions were placed in the hippocampus following which the animal was observed for any behavioral or motor defects in the postoperative period. After suitable survival times, the animals were sacrificed, and the brain prepared according to the Marchi technique. A microscopic study of the degenerated myelinated fiber paths was then carried out.

It was observed, upon proper stimulation, that there

was a pattern of somatic movements on the hippocampus. The region concerned with face responses occupied the anterior two thirds of this structure. Movements of the neck and the upper extremity were obtained from the caudodorsal one third. On stimulation, the anterior part of the hippocampus gave primarily ipsilateral movements, while the posterior two thirds gave no evidence of laterality, the movements being either ipsilateral or bilateral. An arousal response was obtained from stimulation (at higher stimulus levels) over the middle third of the hippocampus. These movements were not eliminated with fornix lesions, but did disappear on separating the hippocampus from the subiculum.

Partial lesions of the hippocampus, even when bilateral, had no effect on the performance of the animals. With the complete removal of the hippocampus bilaterally, the animals became apathetic, lethargic, and lacked spontaneous movement during the postoperative period. Upon external stimulation, however, these operated monkeys reacted violently, showing an attitude of attack, which was poorly oriented and misdirected. All other functions of the animal appeared normal.

Lesions of the hippocampus produced degeneration in the body of the fornix which could be traced to the mammillary, ventromedial hypothalamic, habenular, and lateral septal nuclei, and to the diagonal band of Broca. A much larger percentage of fibers entered the precommissural than the postcommissural fornix. Intrahippocampal and interhippo-

campal connections were also found. An important efferent pathway was demonstrated going from the hippocampus to the hippocampal gyrus and other areas of the temporal lobe.

It was concluded that the hippocampus can act as an independent second motor area and that there is reflected, on the surface of this structure, a pattern of somatic motor movement. It is suggested that the discharge path for these movements is not by way of the fornix, but through connections with the temporal lobe. In addition, then, to the many fiber paths already reported, this study adds evidence for a definite hippocampal-temporal association system which constitutes an efferent pathway from the hippocampus to the temporal lobe. Finally, it is proposed that the hippocampus is concerned in the overall balance of discharges associated with visceral-somatic associations and in the emotional orientation of the animal to its environment.

PREFACE

The writer wishes to express his appreciation to the University of Michigan Medical School and to Lederle Laboratories Division, American Cyanamid Company for granting him, respectively, a summer research fellowship and a Lederle Foundation fellowship, both of which made possible the initiation of a graduate and a research program. The monkeys used in this series of experiments were a very generous gift from Parke Davis Pharmaceutical Company. Other necessary supplies and equipment were paid for from the Walter L. Hill Medical Research Fund. For all of this assistance, in its various forms, the author extends his sincere thanks.

The writer would like to thank his doctorate committee for their advice and encouragement, and especially Dr. Elizabeth C. Crosby for her valuable assistance in carrying out this program. Appreciation is also extended to Mr. James Turley, Mr. Paul Szönyi, the late Mr. George Smith, and to members of the anatomy and graduate staff for their assistance in the operative procedures and their help in the preparation of the technical material.

TABLE OF CONTENTS

	Page
INTRODUCTION	1
MATERIALS AND METHODS	4
EXPERIMENTAL OBSERVATIONS	11
Acute Experiments	11
Animal No. 1	11
Animals Nos. 2 and 3	14
Survival Experiments After Craniectomies	20
Animal No. 4	20
Animal No. 5	27
Animal No. 6	32
Animal No. 7	37
Animal No. 8	46
Animal No. 9	54
Survival Experiments After Stereotaxic Procedures	59
Animal No. 10	59
Animal No. 11	64
Animal No. 12	70
RÉSUMÉ OF EXPERIMENTAL OBSERVATIONS	73
DISCUSSION	78
SUMMARY	105
LITERATURE CITED	107

LIST OF FIGURES

Figure		Page
1.	Photograph of left side of normal Macaca mulatta brain with hippocampus, fornix, and septal area exposed	5
2.	Artist's drawing of figure 1 with terminology added	5
3.	Photograph of side and back view of No. 4 Lab-Tronics stereotaxic apparatus with needle electrode in place	8
4.	Same as figure 3 and showing method of obtaining the electrode coordinates	8
5.	Diagramatic illustration showing locations where movements were obtained in animal 1	13
6.	Photographs taken from motion picture film demonstrating the types of movement obtained in these experiments	13
7.	Diagramatic illustration showing locations where movements were obtained in animals 2 and 3 . . .	19
8.	Same as figure 6, but showing hand movements .	19
9.	Diagramatic illustration showing locations where movements were obtained in animal 4	25
10.	Photomicrograph showing degeneration in bodies of fornices of animal 4	25
11.	Photomicrograph showing degeneration in septal area of animal 4	26
12.	Photomicrograph showing lesion on right of animal 4	26
13.	Diagramatic illustration showing where movements were obtained in animal 5	30
14.	Photomicrograph showing degenerated fibers in septal area and going to diagonal band of Broca in animal 5	31

Figure		Page
15.	Photomicrograph showing degeneration in left hippocampus of animal 5	31
16.	Photomicrograph showing fornix of animal 6 . .	35
17.	Photomicrograph showing septal area of animal 6	35
18.	Photomicrograph showing degeneration in right and left mammillary body of animal 6	36
19.	Photograph of surface lesions of brain of animal 7	43
20.	Photomicrograph of lesion of the left side of animal 7	44
21.	Photomicrograph of fornix of animal 7	44
22.	Photomicrograph of mammillary bodies of animal 7 showing degenerated endings of fornix fibers	45
23.	Photomicrograph of degenerated perforating and alvear paths on the right side of animal 7 . .	45
24.	Photographs of surface lesions of brain of animal 8	51
25.	Photomicrograph of the left anterior hippocampus of animal 8 showing degenerated fibers coming from the amygdala and located medially in the fimbria	52
26.	Photomicrograph of the left fornix of animal 8 showing degenerated fibers in medial portion	52
27.	Photomicrograph of mammillary bodies of animal 8 showing terminal degeneration of fornix fibers	53
28.	Photographs of brain of animal 9 showing surface lesions	57
29.	Photomicrograph of the left lesion of animal 9 showing degeneration entering the alvear path	58
30.	Photomicrograph of the left hippocampus of animal 9 showing terminal degeneration in the hippocampus and the dentate gyrus	58

Figure		Page
31.	Diagramatic illustration showing locations where movements were obtained in animal 10	62
32.	Photomicrograph of right anterior hippocampus of animal 10 showing electrode path	62
33.	Photomicrograph of right posterior hippocampus of animal 10 showing electrode path	63
34.	Photomicrograph of right posterior-superior hippocampus of animal 10 showing electrode path	63
35.	Diagramatic illustration showing locations where stimulation produced movements in animal 11	67
36.	Photomicrograph showing the lesion in the left hippocampus of animal 11	68
37.	Photomicrograph showing degenerated fibers coming from the lesion of animal 11 and entering the white matter of the temporal lobe lateral to the lateral ventricle	68
38.	Photomicrograph showing degenerated fibers lateral to the lateral ventricle in animal 11 with some fibers turning off into temporal lobe areas	69
39.	Diagramatic illustration showing the location where stimulation produced movement in animal 12	71
40.	Photomicrograph showing position of the electrode path in the left septal area of animal 12	72
41.	Diagramatic résumé of positions where stimulation gave movements in these experiments .	74

INTRODUCTION

It is recorded by Lewis ('22) that Julius Caesar Arantius, in the year 1587, described a structure in the human brain which he likened, for some unknown reason, to a sea horse. Thus he named this structure the hippocampus. Since that time, this part of the anatomy of the central nervous system and its connections has been of major concern to neuroanatomists and, more recently, to neurophysiologists.

Many of the early neuroanatomists studied this section of the brain. Golgi ('03) described the fine histologic structure of the region. Ramón y Cajal ('01, '11) carried this investigation into the very fine details of the structure, and it is to his study that we owe much of our knowledge about the fine structure and connections of the hippocampus. Further observations were made by M. Rose ('27) and by Lorente de No ('33, '34). The last author confirmed much of the earlier work and extended previous studies by subdividing the hippocampal area into various parts according to the fiber connections.

Recently, physiologists (to be quoted in more detail in the discussion) have reported conflicting findings on the function of the hippocampus. The general opinion is that the hippocampus is involved, in some way, in somato-visceral association and is concerned with emotion itself or in emotional expression. Our present anatomical information does

not seem to explain adequately these differing opinions.

If the hippocampus does have some relation to emotion, or to the expression of emotion, and if, as Brodal ('47) has concluded on histological grounds, the hippocampus is an effectory structure, it would seem possible that this structure could be considered as a second or additional motor area. Such an additional motor region is a cortical area, other than area 4, which on stimulation produces muscular movements. Ferrier (1886) reported that stimulation of the hippocampus in experimental animals gave movements of the mouth, similar to licking or smacking responses, and interpreted these as feeding responses, showing that the hippocampus took part in such reactions. More recently Penfield ('55, and in Penfield and Erickson, '41) has denied that such stimulation in man gives any sort of movement. Most of the remainder of the literature does not consider this problem.

Thus, in this project, the hippocampus has been investigated to determine if it could act as a second motor area, and if it did so, to demonstrate, if possible, over what anatomical paths the impulses mediating this function passed. Further functional data was obtained by the study of experimental animals after various lesions had been placed in the hippocampus or its related structures.

For the purposes of this paper, any further consideration of, or correlation with, the pertinent literature will be deferred to the discussion. The terminology used for the

hippocampus and its related structures is that employed by Ramón y Cajal ('01, '11) and by Lorente de No ('33, '34). The terminology used for the structures found within the hypothalamic area is that suggested by Rioch, Wislocki, and O'Leary ('39) except for the mammillary body, for which reference was made to the very complete study of J. Rose ('39).

MATERIALS AND METHODS

The area of concern in this study is the hippocampal formation of the monkey. Figures 1 and 2 show a view of the lateral surface of the brain of an experimental animal with a portion of the temporal, parietal, and frontal lobes removed and the lateral ventricle opened. The hippocampal formation constitutes the medial and inferior wall of the temporal horn of the lateral ventricle; the fornix can be seen in its relation to the hippocampus. A simplified copy of this illustration is used to report the results of the individual experiments.

There were three main stages in this study. The first of these dealt with electrical stimulation of the hippocampus and direct observation of any possible movements resulting from such stimulation. The second phase was concerned with the observation of the experimental animals after removal of parts of the hippocampus. The final phase was a study of slides made from the brains of the operated animals.

Stimulation of the hippocampus was carried out by two different methods. In some of the animals the hippocampus was exposed by surgical procedures and the electrode applied directly to it. In other monkeys, the electrode was placed by means of a stereotaxic instrument.

The animals employed were Macaca mulatta and Macaca cynamolgus. The weight of the animals varied from about 2.4



Figure 1. Photograph of left side of normal Macaca Mulatta brain with hippocampus, fornix, and septal area exposed.

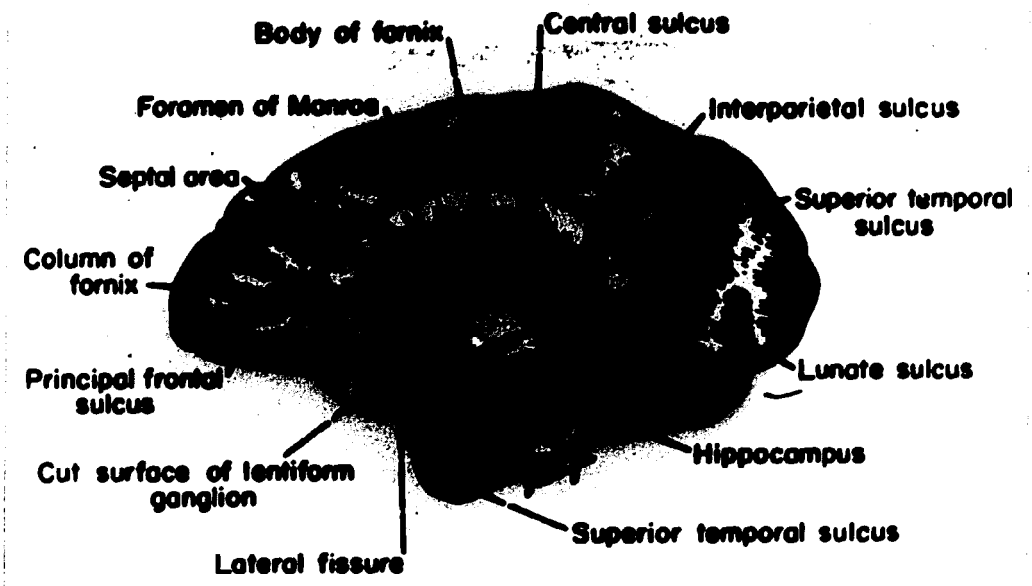

Figure 2. Artist's drawing of figure 1 with terminology added.

to 16.3 kilograms. Either sex was used. The animals were free of any observable disease and of neurologic symptoms. They underwent no training before the experiments were carried out.

All animals used were subjected to a sterile surgical procedure. Animals to be operated upon were not fed for approximately 12 hours before the procedure was to be carried out. The animal was anesthetized with ether and, under anesthesia, the hair over the cranium was clipped and shaved, and then the skin of the scalp scrubbed with phisoderm and prepared with alcohol and zepharin. The animal was then placed on the operating rack. A semicircular incision was made through the skin over the parietal-frontal-temporal area with the convex side of the incision toward the midline. The resulting skin flap was relfected laterally to below the zygomatic arch. The underlying connective tissue was likewise reflected. The temporalis muscle was severed at its origin from the temporal bone, and reflected laterally until the zygomatic bone could be visualized. A sizeable craniectomy was made through the parietal-temporal region, extending to the level of the zygomatic arch. The cranial dura was reflected to reveal the temporal and frontal regions of the cortex. Entrance to the temporal pole of the lateral ventricle was made by removing the midportions of the superior and the middle temporal gyri until the lateral wall of the temporal horn of the lateral ventricle was removed, exposing the hippocampus directly. If the fornix was to be exposed,

the opening in the cortex was extended. Bleeding was controlled by an electrosurgical bovie or by gell foam.

By means of a rectal electrode and a stimulating electrode, connected to a Grass 3C stimulator, the hippocampus was stimulated directly, and the body movements noted. The stimulus strength varied from 2 to 12 volts. A stimulus duration of one millisecond and a stimulus frequency of 40 per second were constant throughout all of the experiments. Motion pictures were taken of any movements resulting from the stimulation.

After stimulation, either a lesion was placed in the hippocampus, or all of the hippocampus was removed. Gell foam was left within the lesion, the dura closed with interrupted sutures, the temporalis muscle sutured across the craniectomy lesion, and then the skin incision repaired. Pencillin was given prophylactically to most animals, and normal saline was administered subcutaneously if the estimated blood volume loss made it advisable.

The above described method results in destruction of a goodly portion of the hemisphere not of direct concern in this project. The stereotaxic apparatus allows stimulation of the deeper structures with the minimum of damage to the surface cortex or the underlying tissue. Therefore a No. 4 Lab-Tronics stereotaxic instrument (figure 3) was employed for some of the experimentation. The readings for the location of the electrode were obtained by direct measurement. To do this the head of an autopsied monkey of approximately



Figure 3. Photograph of side and back view of No. 4 Lab-Tronics stereotaxic apparatus with needle electrode in place.



Figure 4. Same as figure 3 and showing method of obtaining the electrode coordinates.

the size of that of the monkey to be studied, with the hippocampus exposed, was placed in the stereotaxic apparatus. The tip of the electrode, fastened into the carrier of the instrument, was placed on the points to be stimulated, and the coordinates taken directly (figure 4). The electrode, which had been previously treated so that all of the electrode in contact with the brain, except for the stimulating tip, was insulated, was not removed from its carrier until after the operative procedure. At operation, the head was placed in the apparatus and, using sterile technique, the skin was reflected, a small burr hole made in the bone, and the needle electrode passed through the opening according to the previously obtained readings. Stimulation was carried out as before. Since at operation the tip of the electrode can not be seen, its location is determined by placing a lesion electrically, and then studying the brain microscopically after preparation by the Marchi technique. The lesion was made by using 0.3 m. amp. of direct current (the stimulating electrode serving as the cathode) for a duration of one minute. The surgical lesion in the skin was then repaired and the monkey cared for as before.

All the experimental animals were checked daily for the first 7 days postoperatively, and then periodically as necessary up to the time of sacrifice. The animal was observed for activity, possible paralysis or paresis, signs of spasticity, possible changes of mood, and general behavior. In most of the animals stimulation was carried out and destruc-

tive lesions were placed bilaterally but only on one side at a time. Occasionally an acute experiment was carried out where the monkey was never brought out of anesthesia, but sacrificed with an overdose of the anesthetic at the end of the operative procedure.

After variable survival periods, the animals were perfused with 10% formalin intracardially following an overdose of a barbiturate anesthetic (evipal). The brain was then removed and slides prepared by the Marchi technique as modified by Swank and Davenport ('35). A study of these slides indicates the position of the Wallerian degeneration following the lesion.

EXPERIMENTAL OBSERVATIONS

Acute Experiments

Animal No. 1

Procedure and Results of Stimulation

This Macaca mulatta was a male weighing 6.8 kilograms. The left hippocampus was exposed in its entirety, except for the most posterior and superior portion, by a left craniectomy and removal of the superior and middle temporal gyri. Stimulation was then carried out. During the procedure, the brain herniated moderately on opening the dura, and bleeding was very difficult to control. It appeared, after stimulation, that the animal was in poor condition because of the loss of too much blood. For this reason, and because of the herniation, the experiment was terminated as an acute procedure, and the animal was sacrificed with an overdose of the anesthetic (ether).

The results of stimulation were as follows (figure 5). Most anteriorly on the hippocampus, stimulation resulted in ipsilateral retraction of the corner of the mouth, ipsilateral flaring of the external nares, and partial closing of the ipsilateral eyelid. Stimulation more caudally gave a bilateral retraction of the corners of the mouth, bilateral flaring of the external nares, and ipsilateral partial closing of the eyelid. Still farther caudally stimulation pro-

duced bilateral face movements as above, including both eyelids, with turning of the head to the side opposite stimulation (contraction of the ipsilateral sternocleidomastoid muscle), elevation of the ipsilateral shoulder, and an apparent depression of the contralateral shoulder. Still farther caudally the movements obtained were bilateral face as before, extension of the neck (bilateral contraction of the posterior neck muscles), and elevation of both shoulders. At the posterior part of the exposure, there was a marked decrease in the amount of movement of the face (although it was still present), a strong neck extension, strong bilateral shoulder elevation, and moderate flexion of the ipsilateral elbow. Figure 6 shows examples of the movements obtained in this and the following experiments. These photographs are reproductions of selected frames of 16 mm. motion picture film taken during the stimulation procedure. The left side shows the position of the animal at rest, before the application of the stimulus, while the right shows the movement during the stimulation. Ipsilateral face and bilateral face movements are shown.

These stimulations were carried out at a stimulus strength of between 4 and 6 volts. The points of stimulation were marked by a destructive direct current. After the animal had been sacrificed, the brain was removed and the points stimulated were accurately localized, and graphed as in figure 5.

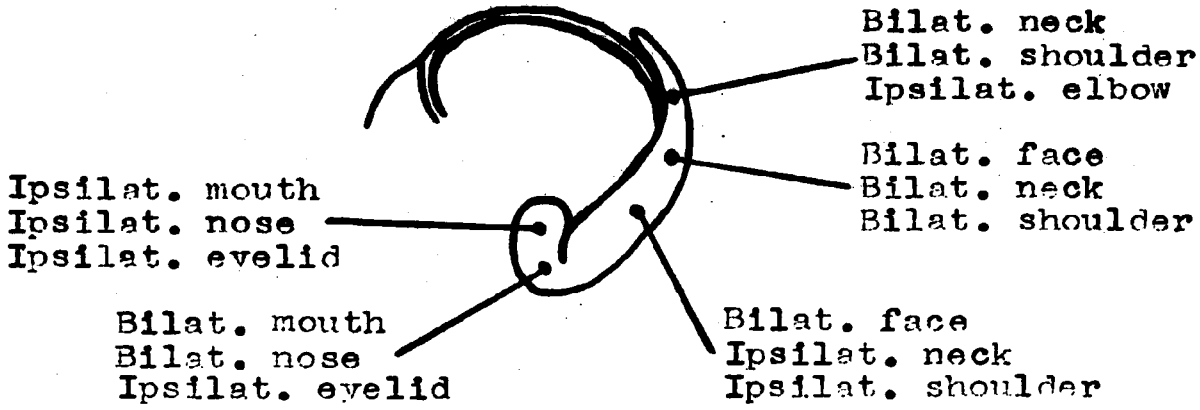

Figure 5. Diagrammatic illustration showing locations where movements were obtained in animal 1.



Figure 6. Photographs taken from motion picture film demonstrating the types of movement obtained in these experiments.

Animals Nos. 2 and 3

Procedure and Results of Stimulation

These animals were male Macacae mulattae, one weighing 11 kilograms, the other 11.6 kilograms. The procedures were designed as a series of acute experiments, the second series being an elaboration of the first. Since the results in both cases either were the same or complimented each other, and since the extra procedures in the second animal were suggested by the results obtained from the first monkey, these two operations will be discussed together. The first animal was put under ether anesthesia, and the entire left hippocampus, fimbria, and body of the fornix were directly exposed through a parieto-temporal craniectomy and the removal of the superior and middle temporal gyri, as well as a part of the island and of the parietal cortex.

Stimulation was first carried out over the entire length of the hippocampus, from anterior to posterior (figure 7). At the most anterior tip of the pes hippocampi, stimulation at 3.5 volts gave an ipsilateral retraction of the corners of the mouth and an ipsilateral flaring of the ala of the nose. Farther inferior on the pes hippocampi, stimulation resulted in bilateral movements of the mouth and nose, and an ipsilateral narrowing of the interpalpebral fissure. At the junction of the pes with the body of the hippocampus, the results obtained on stimulation were bilateral movements of the mouth and nose with bilateral partial closing of the eyelids.

From the next few points, located in the middle third of the hippocampus, face movements such as those described above were obtained. Whether they were ipsilateral, bilateral, or very occasionally contralateral depended on the strength of stimulus and/or the position of the electrode. Using the same strength of stimulus (voltage) but shifting the electrode only slightly (1 mm. along the surface of the hippocampus or 1 mm. deeper) an ipsilateral movement went over into a bilateral or a bilateral movement substituted for an ipsilateral response. Similarly, if the electrode was not moved but the strength of stimulus changed slightly (½ volt), the same result was obtained. Occasionally an isolated contralateral movement was elicited, but this was not a consistent result of the stimulation. Usually whenever the contralateral side responded, it was a part of a bilateral movement. Stimulation along the middle third of the hippocampus also consistently resulted in a slowing of respiration or a ceasing of respiration at deep inspiration. Finally, if the stimulus strength along the middle of the hippocampus was increased to a range of 6-8 volts, and allowed to continue for about 15 seconds, the animal appeared to go into an "arousal" state. This was characterized by coordinated movements of all four extremities as in running and a rapid respiration. An extension of the neck occurred, the eyelids opened widely, the lower jaw moved in a chewing fashion, and a periodic to-and-fro movement of the head developed. The animal acted as if he were coming out of deep

anesthesia. However, after cessation of stimulation, the animal gradually returned, over a period of 1.5 to 3 minutes, to the anesthetic level maintained before the stimulation began, even though no additional anesthetic was administered. Constant and repeated stimulation at this voltage, however, resulted in a lasting awakening response, so that more ether had to be given the animal before further procedures could be carried out.

Still more posteriorly on the hippocampus stimulation gave the same face movements as before, but with an associated ipsilateral contraction of the sternocleidomastoid muscle, so that the head turned away from the side of the stimulation, and an elevation of the ipsilateral shoulder. Then farther back there was an extension of the neck (due to bilateral contraction of the posterior neck muscles), an elevation of both shoulders, and a flexion of the ipsilateral elbow. At the most posterior and superior region of the hippocampus, stimulation resulted in an absence of face movements, an extension of the neck, a bilateral elevation of the shoulders and a swinging forward of the arms, a flexion of both elbows, a flexion of both wrists and a closing of both hands.

At this point in the procedure, the fimbria of the fornix was stimulated and a modified pattern demonstrated across this structure. Stimulating medially on the fimbria gave bilateral face movements as above. Stimulation laterally gave weaker face movements, which were bilateral, and accompanied by bilateral neck, shoulder, and arm responses as described

previously. The electrode diameter was 1.0 to 1.5 mm. The relatively small fimbria contains the accumulated fibers arising or terminating around the cells of a large structure, the hippocampus. It is thus impossible to get a pattern of separate movements such as were obtained when stimulating along the hippocampus.

The body of the fornix has an even more compact fiber arrangement than does the fimbria. Stimulation of it gave a generalized response with all the movements (bilateral face, neck, shoulder, arm, elbow, wrist, and hand) which had been obtained separately from the hippocampus being present simultaneously.

The body of the fornix was then severed completely just posterior to the area stimulated above and the hippocampus restimulated along its length. Except for the arousal response, there was no change in the results described for the same stimulation before the section of the fornix. The effect on respiration was less than evident previously. Only a very minimal arousal response could be elicited and this was of very short duration.

Stimulation of the body of the fornix anterior to the lesion within it (where movements had been obtained before) gave no response at this time. Stimulation of the fimbria posterior to the cut in the fornix showed no change from the results of the similar stimulation described above.

At this point in the operation, the animal had undergone an extensive procedure and, due to the loss of blood, length

of time under anesthesia, and the continued stimulation, which had resulted in much trauma to the brain tissue, it was decided that further experimentation would not give reliable results. Therefore the animal was sacrificed with an overdose of anesthetic.

The left hippocampus of the second animal was exposed as in the first monkey. Check stimulation along the hippocampus, fimbria, and fornix gave the same results as had been obtained before. The hippocampus was then carefully separated from the subiculum and lifted out of the surgical wound. Care was taken not to injure the fimbria or the fornix. Stimulation along the length of the hippocampus failed to give any evidence of movement. No effect on respiration was noted and there was no indication of arousal. Stimulation was then carried out along the subiculum from which the hippocampus had been removed. The same movements were obtained as had been elicited on stimulation of the hippocampus before the separation from the subiculum. However, again, no effect was noted on respiration, and no indication of arousal was present.

Gross Study

After these procedures the animals were sacrificed with an overdose of ether. The brains of both animals were removed and studied for the completeness of the proposed sectioning of tracts during the operative procedures. It was found that the fornix of the first animal had been completely severed. In the second animal the hippocampus had been

removed over its entire length without injury to the hippocampal gyrus and the presubiculum. The subiculum had sustained moderate damage.

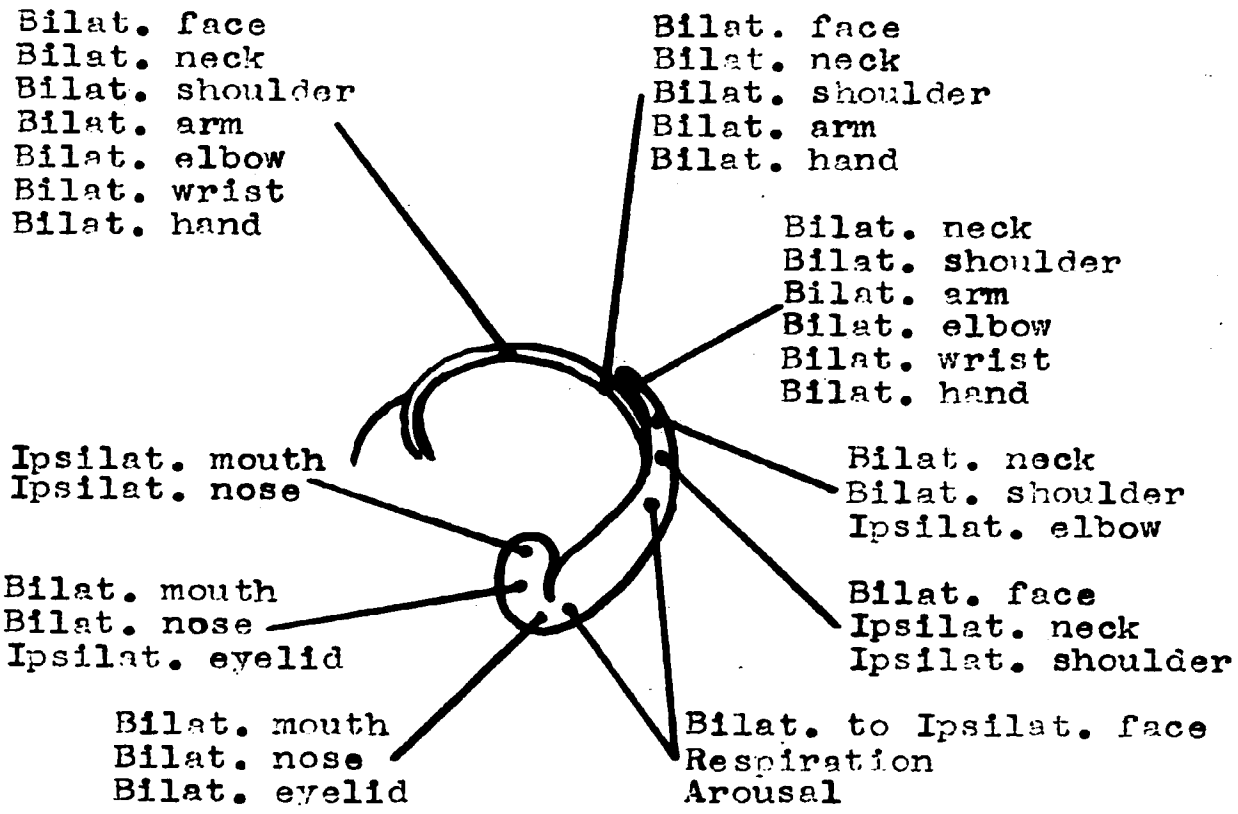

Figure 7. Diagramatic illustration showing locations where movements were obtained in animals 2 and 3.



Figure 8. Same as figure 6, but showing hand movements.

Survival Experiments After Craniectomies

Animal No. 4

Procedure and Results of Stimulation

The male Macaca mulatta used weighed 5.5 kilograms. The left hippocampus was exposed through a left craniectomy and the superior and the middle temporal gyri removed. It was adjudged that the exposure was over the middle third of the hippocampus. Stimulation was then carried out with a unipolar electrode with a rectal plug used as the indifferent electrode.

The results of the stimulation were as follows (figure 9): Stimulation at the anterior part of the exposed hippocampus gave ipsilateral movements which consisted of a retraction of the corner of the mouth, a flaring of the ala of the nose, and a partial closure of both eyelids. No effect was noted on eye movement itself. Farther caudally on the hippocampus, ipsilateral contraction of the sternocleidomastoid occurred so that the head turned toward the side opposite stimulation. The unilateral facial movements noted previously also appeared at this point. Still farther caudally, the facial movements became bilateral but the contraction of the sternocleidomastoid muscle remained ipsilateral. Stimulation in a position caudal to the last level produced flexing of the left wrist and the left elbow, an elevation of both shoulders, an extending of the neck, and a bilateral grimacing of the face. All these movements were

obtained at voltages between 4.5 and 9.

The wound was closed surgically after cutting through the hippocampus, the alveus, and the fimbria at the midpoint of the exposure. The animal was closely followed for 14 days. No apparent defect resulted from the experimentation, the monkey appearing normal in all respects.

Twentyone days later the right hippocampus was exposed in the manner just described, but the exposure was much smaller and made at about the junction of the anterior and middle thirds of the length of the hippocampus. Using the same voltage and frequency as before, ipsilateral facial movements of the same type as seen previously were obtained (point marked "X" on figure 9). The wound was closed and the animal allowed to recover.

As a result of these operations the animal had lost a major part of the superior and the middle temporal gyri on the left and a small portion of the same gyri on the right side. He also had a lesion in each hippocampus. In spite of these relatively large injuries, after the effects of the anesthetic had worn off, the animal appeared quite normal. His general behavior did not alter, he fed himself quite well and maintained his ability to move with great agility. His mood apparently did not change.

Fourteen days after the second operation the animal was given an overdose of evipal and perfused with 10% formalin. The brain was immediately removed and the material prepared according to the Marchi technique.

Gross and Microscopic Study

There are the operative lesions on both sides of the brain. A large part of the superior and the middle temporal gyri have been destroyed bilaterally. These lesions, beginning just short of the tip of the temporal pole, extend the entire length of the temporal lobe. The inferior portion of the island cortex is also destroyed on both sides.

Microscopically, lesions are present in the hippocampus of each side. The lesion on the left is large, covering all of the middle third and considerable part of the anterior portion of the posterior third of the hippocampus. Anteriorly this lesion involves only the alveus and a small amount of the polymorphic cell layer of this structure. It does not enter the dentate gyrus. In the posterior third of the hippocampus, the lesion goes deeper, including, as well as the layers mentioned above, the remaining layers of Ammon's horn and all of the dentate gyrus for a short distance.

The lesion on the right is much smaller, involving only the anterior portion of the posterior one third of the hippocampus. It extends somewhat deeper than the left, including the pyramidal cell layer of the hippocampus as well as the alveus and polymorphic cell layer. For a short distance it has also destroyed all layers of the dentate gyrus.

There is Marchi degeneration in the fornix of both sides. The number of Marchi granules is much greater on the left, where the degeneration can be followed through the precommissural division of the fornix column to end with a high

concentration of Marchi granules in the lateral septal nucleus, and with a small concentration of granules in the medial septal nucleus and the diagonal band of Broca. Evidence of the involvement of the postcommissural fornix column by the lesion is much more difficult to demonstrate, but sparsely scattered granules can be followed along it and into the medial mammillary nucleus. It could not be determined with certainty whether any degenerating fornix fibers terminate in other hypothalamic nuclei. No granules are present in the lateral mammillary nucleus and no postmammillary degeneration is evident. There appears to be a small number of granules in the stria medullaris which can be followed to terminal degeneration in the habenular nuclei of both sides. The distribution of the degeneration on the right is similar to that on the left, although the amount of such degeneration is much greater on the left. The degeneration in the postcommissural fornices, mammillary nuclei, striae terminales, and habenular nuclei is comparable on the two sides. There is greater terminal degeneration in the left than in the right lateral septal nucleus (figures 10, 11).

On the right, in the posterior regions of the hippocampus, the degeneration in the fimbria is very marked, much greater than in the body of the fornix on the same side (figure 12). Degeneration granules can be followed from the right fimbria into the pyramidal cell layer and the radiate layer of the hippocampus, and in to the granular cell layer of the dentate gyrus at the level of, and just anterior to, the lesion.

Some degeneration can also be traced into the hippocampal gyrus at the same levels. Still anterior to the lesion on the right, degeneration granules are found in the fimbria, alveus, pyramidal cell layer of the hippocampus, and granular cell layer of the dentate gyrus. Degeneration of this nature is seen also on the left. Since the lesions are very large in the lateral parts of the hemispheres, the origin of these degenerated fibers can not be determined with certainty.

The stria terminalis was severed in the process of opening the lateral ventricle during the operation. Degeneration can be followed throughout the whole course of this path, and degenerated fibers can be seen going from it to the preoptic area, lateral septal area, and crossing in the anterior commissure.

Degenerated temporotegmental and temporopontine fibers pass from the temporal lobe lesions to the tegmentum and the pons, respectively. Degeneration is also found in the lateral nuclear group of the thalamus, and is very heavy in the pulvinar. Degenerated corticothalamic fibers are seen coming from the lesion and distributing to the whole length of the lateral thalamic nuclei. There is a heavy degeneration in the pyramidal layers of the island cortex on the right and in the cingulate gyrus cortex on the left, but because of the size of the lesions, the significance of these can not be determined. Finally, there is a considerable degeneration in the components of the anterior commissure coming from the anterior temporal lobe areas.

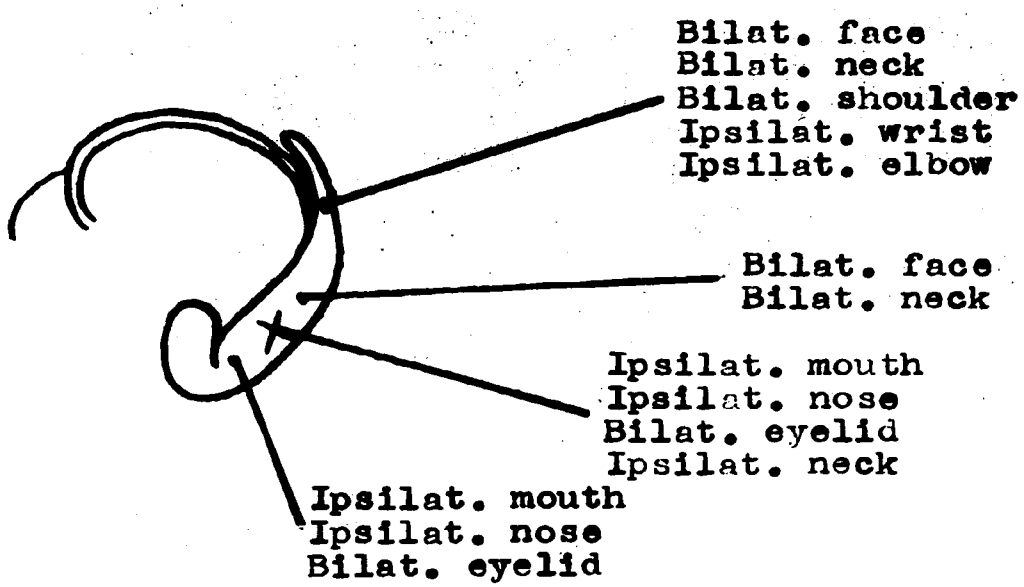

Figure 9. Diagramatic illustration showing locations where movements were obtained in animal 4. "X" represents a position on both left and right sides.

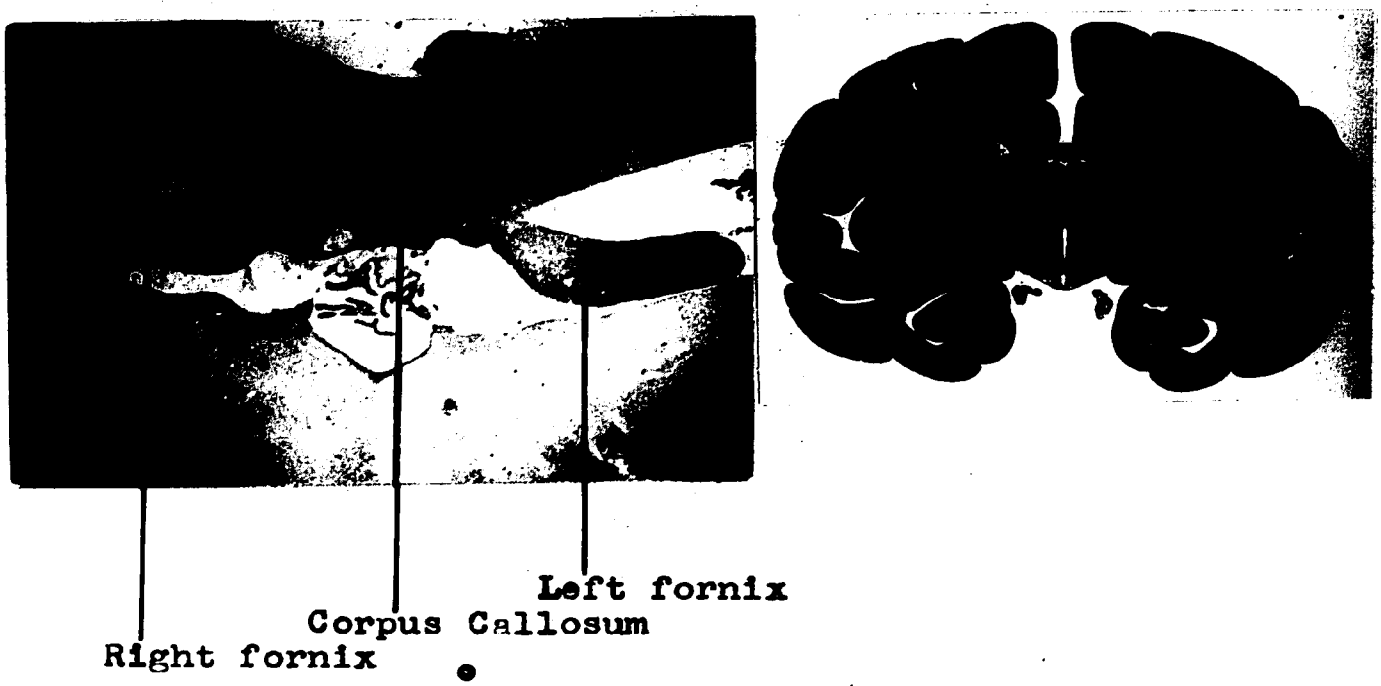

Figure 10. Photomicrograph showing degeneration in bodies of fornices of animal 4. Note larger number of degeneration granules on the left. (Marchi stain, X 17.5) For this and following photomicrographs, the position of the section is blocked out on the accompanying Weil stained section (X 1).

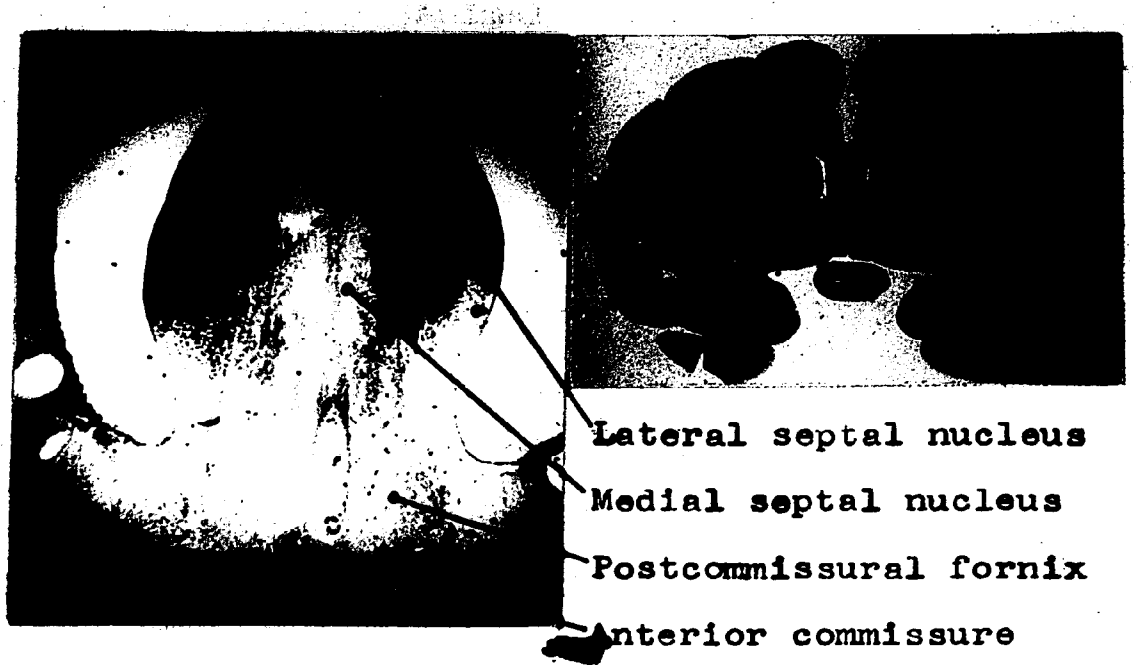

Figure 11. Photomicrograph showing degeneration in septal area of animal 4. Note relative lack of degeneration in the postcommissural fornix. (Marchi stain, X 17.5)

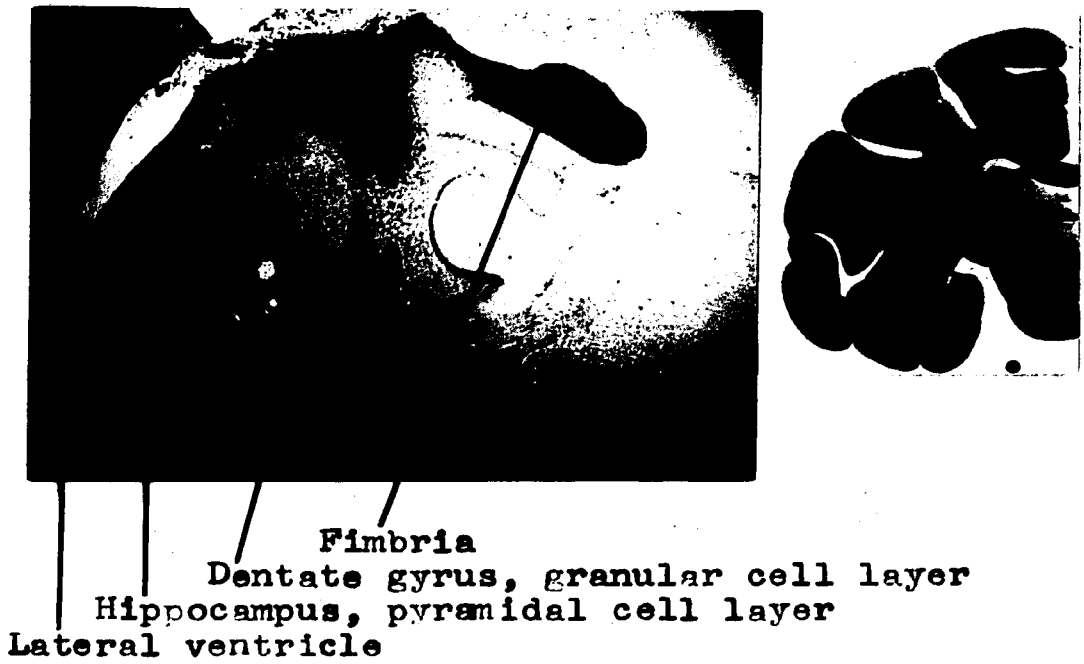

Figure 12. Photomicrograph showing lesion on right of animal 4. Compare amount of degeneration in fimbria to that of fornix in figure 10. (Marchi stain X 17.5)

Animal No. 5

Procedure and Results of Stimulation

The Macaca cynamolgus used in this experiment weighed 3.2 kilograms. The right hippocampus was exposed through a right craniectomy and the superior and the middle temporal gyri removed. The exposure was over the anterior half of the hippocampus. This area of the exposed hippocampus was stimulated with a unipolar electrode (rectal plug used as the indifferent electrode) using a stimulus strength of from 3 to 6.5 volts.

Stimulation at the lower levels of the stimulus strength gave ipsilateral movements of the face, including drawing back of the corner of the mouth, opening of the jaw, opening of the nostril, and a partial closure of the eyelid. No eye movements were noted. Stimulation at higher voltages produced bilateral movements. If the electrode was moved slightly, but the same stimulus strength employed, the ipsilateral movements often became bilateral. Similarly, changing the stimulus strength in a stationary electrode might shift the response from an ipsilateral to a bilateral movement. During the course of this experiment, isolated contralateral movements were not obtained (figure 13).

A portion of the hippocampus in the area stimulated was removed and the surgical lesions were repaired. After the anesthesia had worn off, the animal reacted quite normally. No defects of any sort were noted.

Fourteen days after this surgical procedure, the animal

was sacrificed with an overdose of evipal. The brain was removed and prepared according to the Marchi technique.

Microscopic Study

Microscopically there is a lesion in the superior and the middle temporal gyri on the right. This lesion is located in the midregion of these two gyri with destruction in the middle gyrus extending anterior and posterior to that in the superior. In the region of the hippocampus, the area destroyed extends anteriorly and posterior-superiorly to the lesion in the lateral part of the temporal lobe. Thus, the entire amygdala on this side has been destroyed, as well as all layers of the superior lateral extent of the anterior two thirds of the hippocampus. In the midregion of the hippocampal lesion there is destruction of the molecular and granular layers of the dentate gyrus.

Degenerated fibers can be followed from the region of the lesion through the fimbria and to the fornix. These fibers continue forward, entering, in most part, the precommissural part of the fornix, and then ending in the lateral septal and the medial septal nuclei, and extending into the diagonal band of Broca on both sides (figure 14). The amount of degeneration appears to be equal on the two sides, the crossing taking place just anterior to the septal area in the region of the anterior commissure. No degenerated fibers can be followed with certainty in the postcommissural fornix, but terminal degeneration granules can be identified in the medial mammillary nucleus of each side in equal concentration.

No true degeneration is seen in the lateral mammillary nucleus and there is no postmammillary degeneration.

In the region of the lesion, there are widespread terminal Marchi granules in the polymorphic and pyramidal cell layers of Ammon's horn and in the polymorphic and granular cell layers of the dentate gyrus. This same degeneration extends behind the region of the lesion in the hippocampus. In this posterior region, fibers are seen turning out of the alveus and the molecular layer of the hippocampus to enter these regions of terminal degeneration.

On the right, degenerated fibers are found in the white matter, in the region of transition between the hippocampal gyrus and the hippocampus, and also in the white matter of the inferior temporal gyrus. Because of the presence of the lesion in the lateral hemisphere wall as well as in the hippocampus, it is not possible to determine from which area these degenerated fibers originate, or whether they may arise from both regions. On the left side, terminal degeneration is noted in the polymorphic and pyramidal cell layers of the hippocampus and in the polymorphic and granular cell layers of the dentate gyrus. There are also some Marchi granules in the hippocampal gyrus on the left. This is true over the entire extent of these structures but the origin of the degenerated fibers can not be determined. Some degenerated fibers are present in the hippocampal commissure. There is no definite degeneration in the stria medullaris or in the habenular nuclei (figure 15).

The stria terminalis contains degenerated fibers on both sides, but in greater number on the right. Granules are scattered diffusely throughout all of the thalamic nuclei and much of the hypothalamic nuclei. Since these can not be followed from any common path, and since they have no characteristic distribution, they must be considered to be artefact. Though there is a wide lesion in the lateral part of the temporal lobe, there is no distinctly degenerated temporotegmental or temporopontine paths.

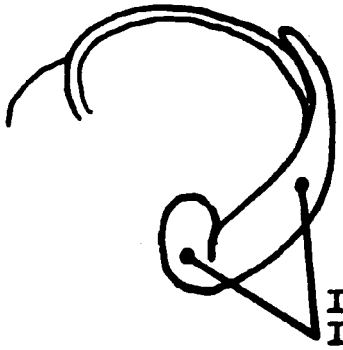

Figue 13. Diagramatic illustration showing where movements were obtained in animal 5.

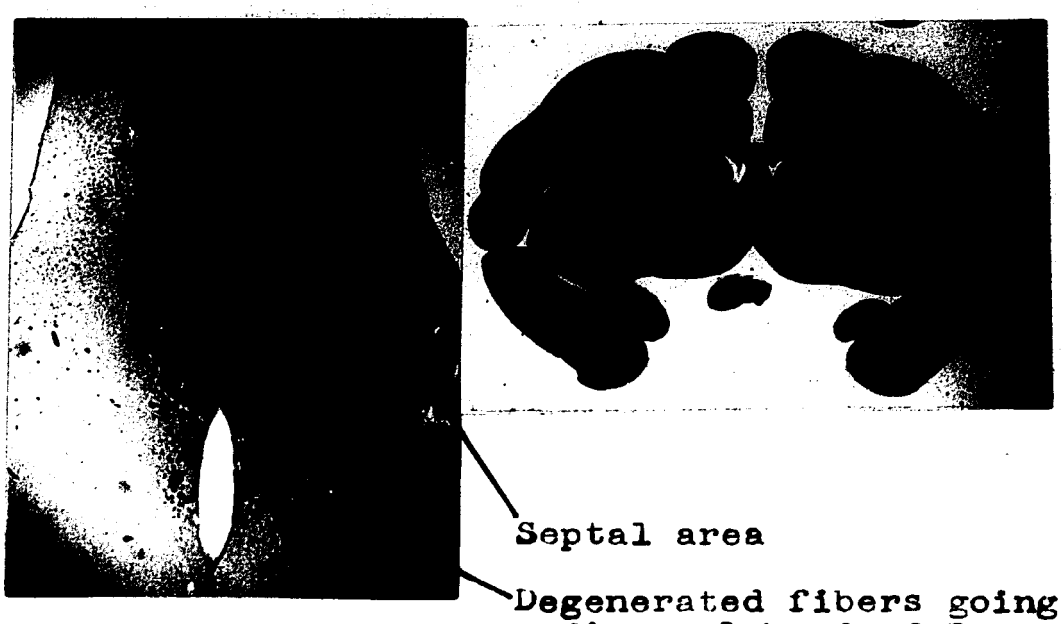

Figure 14. Photomicrograph showing degenerated fibers in septal area and going to diagonal band of Broca in animal 5. (Marchi stain, X 17.5)

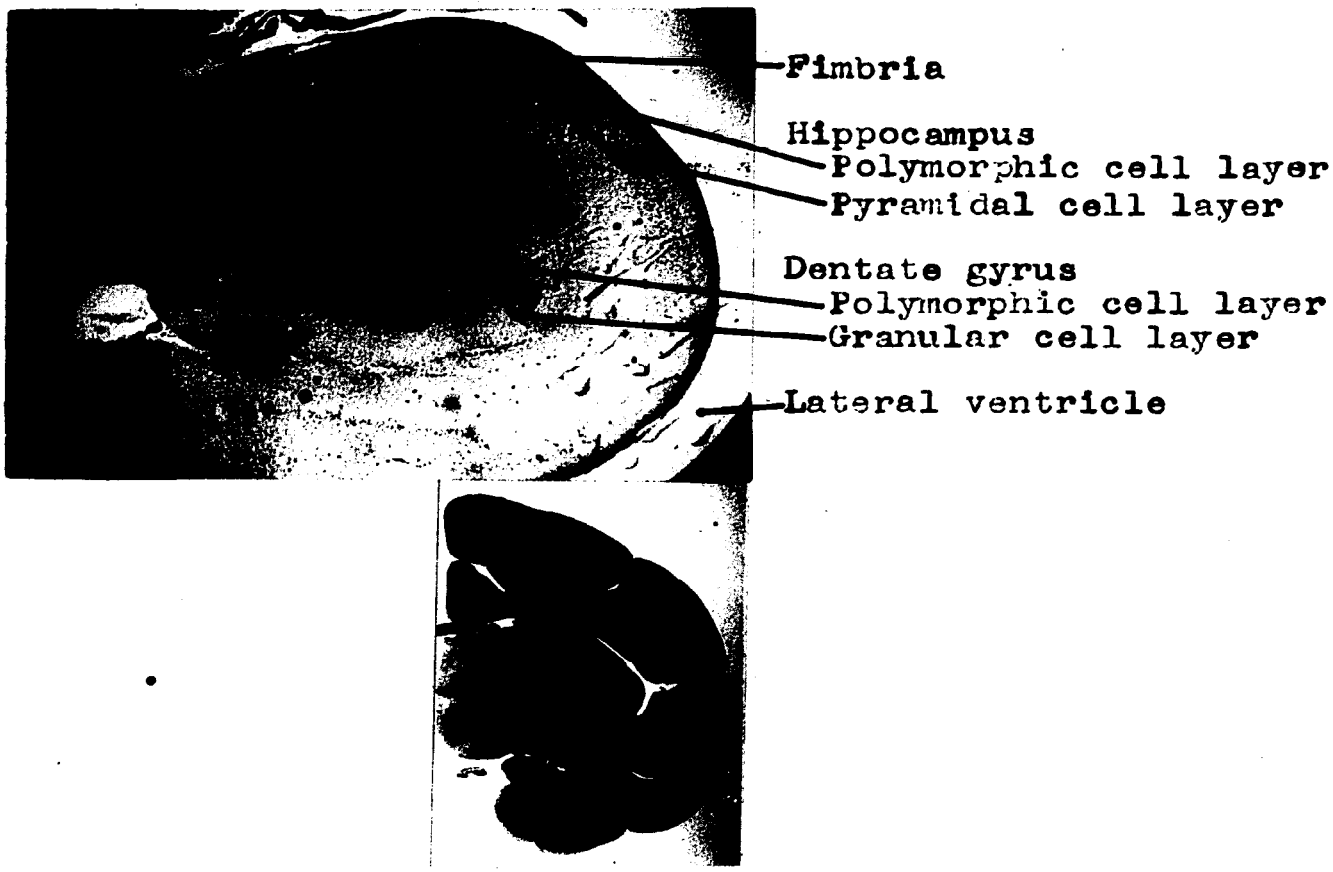

Figure 15. Photomicrograph showing degeneration in left hippocampus of animal 5. (Marchi stain, X 17.5)

Animal No. 6

Procedure and Results of Stimulation

This female Macaca cynamolgus weighed 9.2 kilograms. At attempt was made to study the effects of complete extirpation of both hippocampi by the surgical removal of them through the lateral hemisphere walls. Through a craniectomy, the right hippocampus was exposed and stimulated. The results of this stimulation were similar to those in the preceding experiments. The hippocampus was then removed as completely as possible with a brain sucker. Gell foam was left in the wound. The surgical lesions in the dura, the temporalis muscle, and the skin were repaired. The animal was returned to her cage.

On the days following the operation, after sufficient time had been allowed for recovery from the anesthetic, the animal acted more docile, although in some respects she appeared more aggressive. When the keeper entered her cage, the animal would stand in a corner, bare her teeth, sometimes vocalize and appear excited. She acted as a normal monkey does just before he attacks or runs from his keeper. This animal, however, did not run, and offered only slight resistance to being caught. No paralysis, no paresis, and no spasticity could be found. The animal was able to move around well, although she appeared to have less inclination to do so than does the ordinary monkey. She had normal feeding habits.

Seven days following the first operation, the left hip-

pocampus was exposed through a craniectomy. Stimulation again gave the same results as previously, despite the absence of the right hippocampus. On returning to the cage, the animal did poorly from the begining. She never regained consciousness, and was fed by subcutaneous fluids for one week. She reacted only to the most severe stimuli. She appeared to be completely paralyzed on the right, and partially so on the left. There was a right spasticity, and a left partial spasticity.

Gross and Microscopic Study

Fourteen days after the first operation the animal was sacrificed, and then perfused with 10% formalin. The brain was removed, hardened in formalin, and then studied grossly. The surgical lesion on the right involved the central part of the superior temporal gyrus, a small adjoining area of the middle temporal gyrus, the inferior parietal gyrus, and a small adjoining area of the pre- and postcentral gyri. The inferior part of the island cortex had been destroyed. The hippocampus had been completely removed with some damage to the hippocampal gyrus.

On the left the direction of the surgical lesion had been miscalculated and much additional cortex had been taken out. The superior temporal gyrus was completely destroyed except for its anterior quarter, and the adjoining temporal gyrus, mostly middle temporal gyrus, was partially destroyed over the same area. The inferior lateral parietal lobe had been damaged, as had the inferior lateral half of the post-

central gyrus. A small area of the precentral gyrus near the lateral fissure had been destroyed and, in addition, all of the island cortex removed. The lesion extended into the posterior limb of the internal capsule, and also into the lateral fields of the thalamus, which were largely destroyed. The hippocampus had been removed only partially.

Microscopically only a central block of tissue bordered by the corpus callosum, the external capsule, and the inferior surface of the diencephalon and brain stem was prepared according to the Marchi technique and studied. Degeneration is massive, as was expected from the rather massive cortical lesions. There is diffuse degeneration throughout all of the thalamus. The internal capsule of both sides is severely degenerated, accounting for the paralysis. The lateral field of the left thalamus is completely destroyed. Hemorrhage has extended beyond the grossly described lesions. Supprisingly there is only a small amount of degeneration in the body of the fornix of either side, a little more on the right than on the left. There are degeneration granules in the lateral septal nucleus of each side. The postcommissural fornix can be followed to the mammillary body. It shows relatively only a small amount of degeneration as compared to the rest of the field. Terminal degeneration is found in the mammillary bodies. No further conclusions can be made from a study of this brain material because of the extensive degeneration present. (figures 16-18).



Figure 16. Photomicrograph showing fornix of animal 6. Note relative absence of degeneration in fornix as compared to corpus callosum. (Marchi stain, X 17.5)

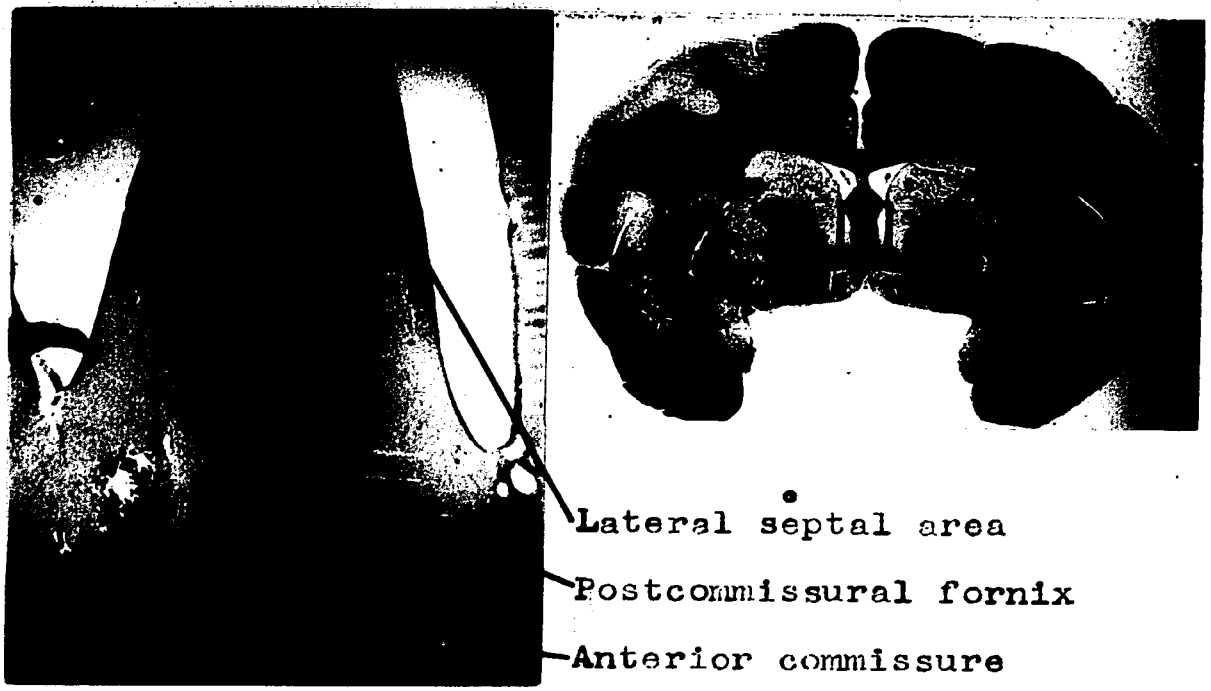

Figure 17. Photomicrograph showing septal area of animal 6. Note relative absence of degeneration in postcommissural fornix as compared to lateral septal area. (Marchi stain, X 17.5)



A B

Figure 18. Photomicrograph showing degeneration in right (A) and left (B) mammillary body of animal 6. (Marchi stain, X 50)

Animal No. 7

Procedure

This female Macaca mulatta weighed 16.3 kilograms. The object of this experiment was to determine the effect of complete bilateral removal of the hippocampus. This was attempted through a lesion placed in the lateral hemisphere. Accordingly the animal was anesthetized, a left craniectomy performed, the middle and the superior temporal gyri removed in their central areas, and the hippocampus exposed. Stimulation was carried out as a check on previous results, and the pattern was found to be the same. Then, with the use of a brain sucker, a lesion was made throughout the hippocampus. Gell foam was left in the lesion, and the animal returned to her cage.

After allowing one day for the effects of the anesthetic to wear off, the animal was closely observed for 14 days. She appeared to be more hostile and agressive, but less fearful of the experimenter than before the operation. When an attempt was made to catch her, she would back into a corner, bare her teeth, vocalize in a low gutteral voice, but neither attack nor run as an unoperated monkey will do. However, when she was touched, she reacted violently, bit if possible, tried to escape, and in general reacted as does a normal unoperated monkey. A bilateral piloerection was noted over the upper half of the body. There were no signs of spasticity or paralysis. She fed herself normally.

Eleven weeks after the first operation, the right hip-

pocampus was removed in a similar fashion. Gell foam was again left in the lesion, and the animal returned to the cage. After the effects of the anesthetic had worn off, the monkey acted very docile, with brief intermittent periods of violent activity. She exhibited very little ordinary spontaneous activity, though she did feed herself. There was no evidence of paralysis or spasticity. If the experimenter disturbed her, she would take notice of his presence, but appeared to be unconcerned about it. Upon the application of a strong stimulus, such as a sharp needle or a severe pull on her neck chain, she would go into a brief period of violent activity, biting anything close at hand, and attempting to attack or escape. However, she then quickly returned to a condition in which she exhibited no spontaneous activity. During the activity, the attack was often misdirected or disoriented. During the survival period up to the time of sacrifice, there was a gradual return of some spontaneous activity, but she remained definitely less excitable than a normal monkey.

Gross and Microscopic Study

Seven weeks after the second operation the animal was sacrificed and the brain removed and hardened in 10% formalin. The lesions were then noted grossly and pictures taken (figure 19). The lesion on the left involved the adjoining area of the midregion of the superior and the middle temporal gyri and extended for a short distance posteriorly and superiorly, involving the middle temporal gyrus. The lesion on the right was similarly placed. The island cortex was not included

directly in the gross lesion on either side of the brain. The lesion on the right was slightly more superior than that of the left, and involved the stria terminalis and the tail of the caudate. The lesion on the left extended slightly more anteriorly than that on the right.

The brain was then prepared according to the Marchi technique. Microscopically the lesion on the left extends to the anterior tip of the amygdaloid nucleus, and has destroyed the superior aspect of this nucleus. The superior and middle temporal gyri have been removed as just described. There is a lesion along the superior lateral aspect of the hippocampus, which completely interrupts the alveus and all the underlying layers of the hippocampus. Only the most lateral aspect of the dentate gyrus is involved and only minimally so. This lesion extends the entire length of the hippocampus. On the right, the lesion is not so far anterior as on the left, although the posterior superior part of the amygdaloid nucleus has been involved. The lesion on the right side is on the superior aspect of the hippocampus, and again completely interrupts all of its layers. It also extends deep enough to include a considerable part of the dentate gyrus as well (figure 20).

On each side, degenerated fascicles can be traced from the lesion through the alveus bundles, to the fimbria and the body of the fornix. This degeneration is more concentrated on the left. Degeneration granules extend anterior to the anterior commissure, where fibers are seen entering

the precommissural and the postcommissural fornix columns and the stria medullaris.

The degenerated fibers pass, in large numbers, in front of the anterior commissure into the lateral septal nucleus, and terminal degeneration granules are found in this nucleus in high concentration. Evidences of a smaller terminal degeneration are also present in the medial septal nucleus. Some degenerated bundles can be followed through the medial septal area into the diagonal band of Broca, where terminal degeneration granules are again found.

The postcommissural fornix column has degenerated granules which are easily followed to the medial mammillary nucleus, where marked terminal degeneration is seen in the form of granules diffusely scattered over the entire nucleus (figures 21, 22). There is a small amount of terminal degeneration in the lateral mammillary nucleus as well. Along the path of the postcommissural fornix, fibers can be seen to turn off into the anterior hypothalamic area and to the ventromedial hypothalamic nucleus, but there are a very few terminal granules in these latter two nuclei. There are some granules posterior to the mammillary body, reaching the areas about the superior and medial aspect of the red nucleus, but they can not be followed with certainty from the postcommissural fornix column.

The stria medullaris contains a small number of degenerated fibers, which reach the habenular nucleus. There is some terminal degeneration in the habenular nucleus of each

side. Though the amount of degeneration in the right fornix is less than on the left side, the amount of terminal degeneration in the striae medullares and the postcommissural part of the fornices is the same on the two sides. The precommissural part of the left fornix has a much higher concentration of granules than does the corresponding bundle on the right. The hippocampal commissure has a large number of degenerated crossing fibers. Though the lesion in both hippocampi was quite extensive, it is to be noted that less than 50% of the fibers of the fornix body degenerated. A comparison of the concentration of Marchi granules in the body of the fornix, with that of the postcommissural column of the fornix on either side, indicates that at least three fourths or more of the degenerated fibers end in the septal area (figure 21).

Both medial and lateral to the lesions in each hippocampus, terminal degeneration granules are present in the stratum lucidum, stratum radiatum, and the polymorphic cell layer. Terminal degeneration is also seen in the granular and polymorphic cell layers of each dentate gyrus. There is fiber degeneration in the alveus and in the tangential layer of the hippocampus, both of which are continuous with degenerated fasicles in the perforating and alvear pathways from the hippocampal gyrus (figure 23). Degeneration granules are found in the alveus both medial and lateral to the lesion in the hippocampus. Because of the nature of the lesion, it can not be determined whether the degeneration in the alveus

lateral to the lesion, in the perforating path, and in the tangential layer of the hippocampus are from the injury in the lateral hemisphere wall or from the hippocampus, or from both areas.

Degenerated fibers are found entering the indusium griseum and traveling the entire length of this structure. The granules are followed around the genu of the corpus callosum and into the anterior reaches of the hippocampal rudiment. A few fibers turn off into the cingulate gyrus along this path and a few terminal granules are found scattered through the layers of this gyrus.

Temporotegmental and temporopontine fibers from the middle and superior temporal gyri can be followed to their destination. There is also a marked degeneration of corticothalamic fibers passing from the injured temporal lobe area to the anterior and lateral nuclei of the thalamus and especially to the pulvinar. The stria terminalis has been interrupted on each side and degenerated fibers can be followed along this path to the amygdaloid nucleus in one direction, and to the anterior commissure, the preoptic area, and, possibly, to the septal nuclei in the other direction. From the region of involvement in the amygdaloid nucleus, degenerated fibers enter the alveus on the anterior aspect of the hippocampus. There is a marked amount of terminal degeneration in the island cortex and degenerated fibers are present in the internal, the external, and the extreme capsules. There is a large amount of degeneration in the anterior commissure

which can be followed to the area of the lesion in the anterior temporal lobe. This degeneration in the anterior commissure is the same as described by Fox, Fisher, and DeSalva ('48).

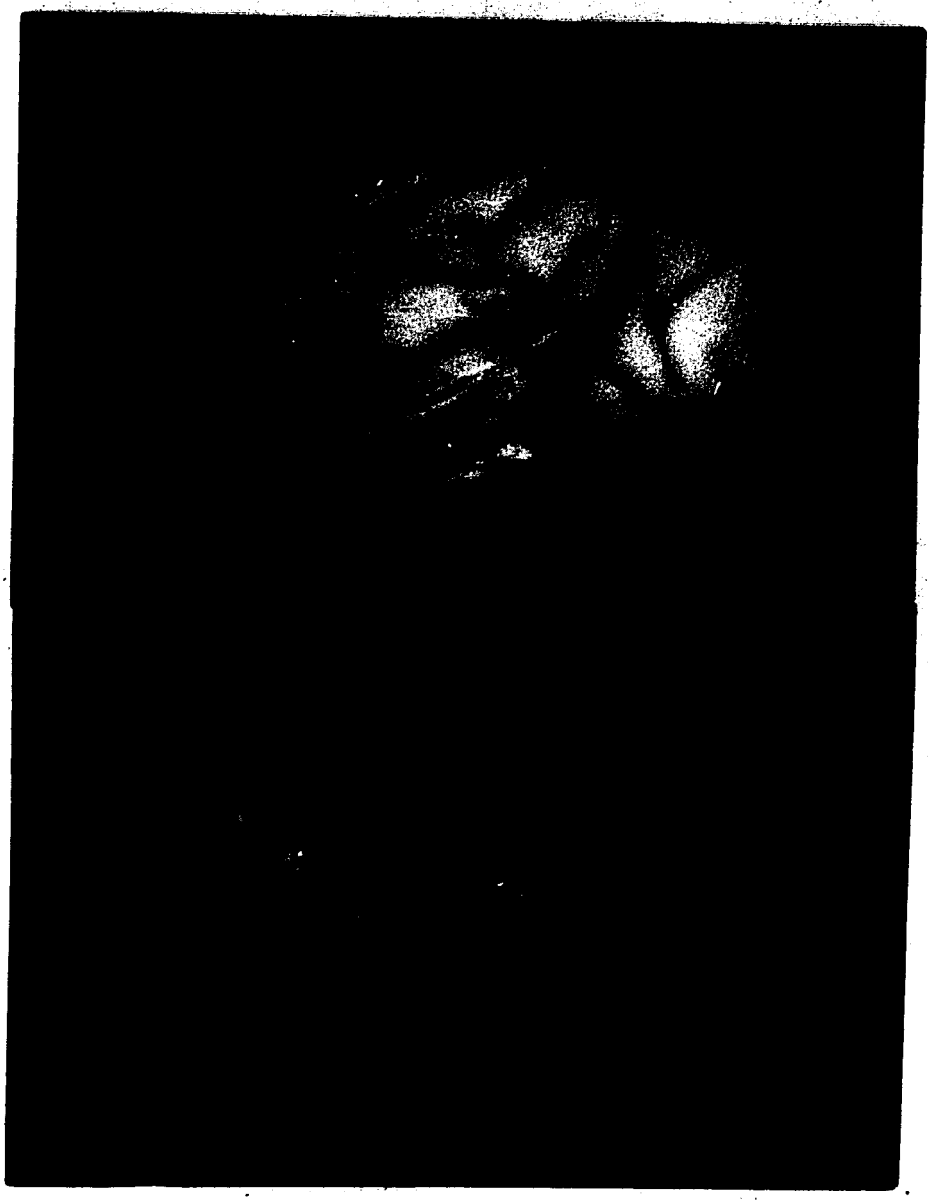

Figure 19. Photograph of surface lesions of brain of animal 7.

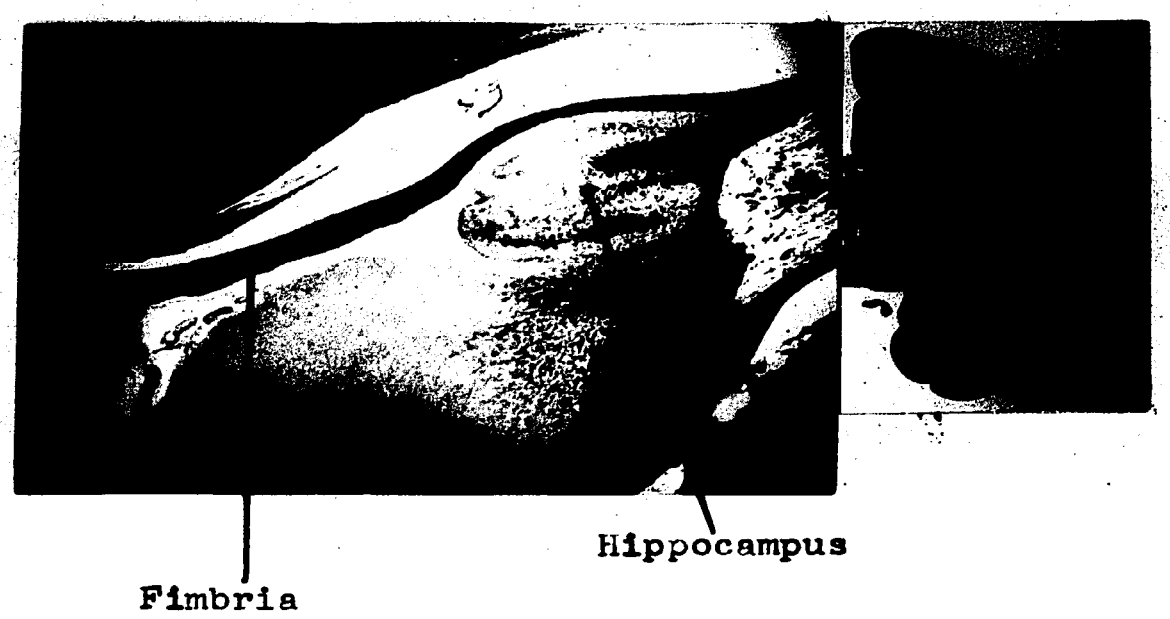

Figure 20. Photomicrograph of lesion of the left side of animal 7. (Marchi stain, X 17.5)

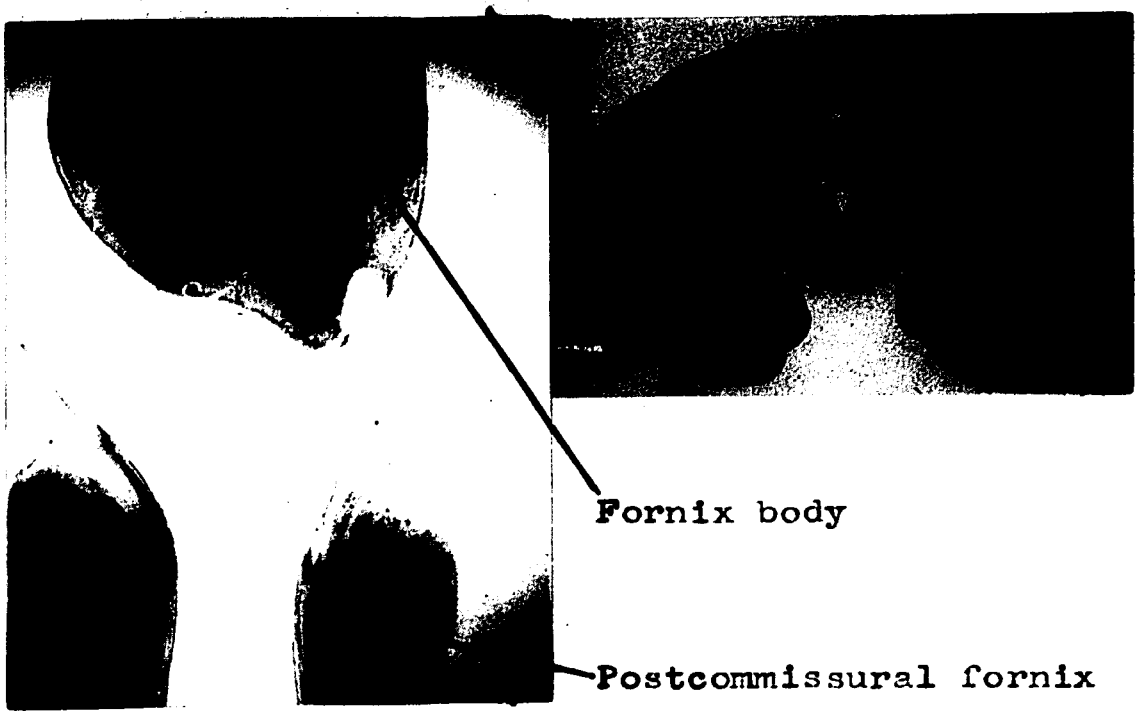

Figure 21. Photomicrograph of fornix of Animal 7. Compare small amount of degeneration in postcommissural fornix to that in the fornix body. (Marchi stain, X 17.5)



Figure 22. Photomicrograph of mammillary bodies of animal 7 showing degenerated endings of fornix fibers. (Marchi stain, X 17.5)

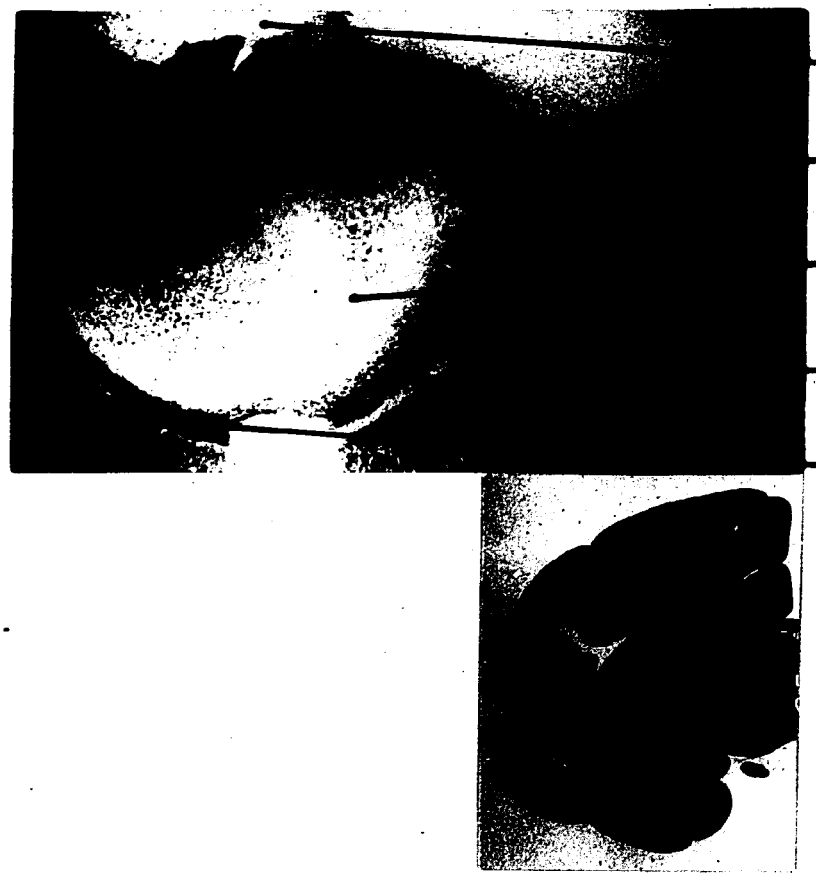

Figure 23. Photomicrograph of degenerated perforating and alvear paths on the right side of animal 7. (Marchi stain, X 17.5)

Animal No. 8

Procedure

This female Macaca mulatta weighed 14.1 kilograms. The experiment was designed to act as a control for animal no. 7. Thus, an attempt was made to remove the same areas of the lateral hemispheres, and to expose the hippocampus as before, but without making a lesion in the hippocampus itself. Accordingly, the animal was anesthetized, and through a left craniectomy the left hippocampus was exposed by removing a part of the superior and the middle temporal gyri. The exposure was enlarged so that the entire hippocampus could be visualized. Every precaution was taken not to disturb the hippocampus in any way. Stimulation was not attempted.

The animal was returned to her cage. After the effects of the anesthetic had disappeared, she acted quite normally. There was no evident defect of any sort. She exhibited the normal amount of activity, and a normal amount of hostility toward her keeper.

Eleven weeks following the first operation, the right hippocampus was exposed similarly. Again, although the hippocampus was exposed over its entire length, care was taken not to injure it in any way. Stimulation was not attempted.

On returning to the cage, the animal recovered from the anesthesia very well. On the days following the operation and up to the time of sacrifice, the monkey showed an increased amount of spontaneous activity, a lack of fear, and a very high degree of curiosity. She would place anything

she could pick up by hand in her mouth. However, after doing so, she would reject anything that was not the normal type of monkey food. She would approach any person without fear. She would put the keepers hand in her mouth, but would never bite hard. It was discovered that you could handle her without gloves, something which is never permitted in the University of Michigan Anatomy laboratory in handling the normal unoperated animal. She appeared to be less vocal than before operation. This condition remained for the seven weeks prior to sacrifice.

Gross and Microscopic Study

Seven weeks after the second operation the animal was sacrificed with an overdose of evipal and perfused with 10% formalin. The brain was removed and hardened in formalin. Pictures were taken and a study of the gross brain followed (figure 24). The lesion on the right affected the midregion of the superior and the middle temporal gyri. It extended slightly more anterior and not quite so far posterior as did the corresponding lesion in monkey no. 7. The lesion on the left was similarly placed, but did not extend so far posterior as the corresponding lesion in monkey no. 7, though its anterior extent was about the same. Grossly the anterior inferior part of the island cortex was slightly involved on the right, but not so on the left.

The brain was then prepared according to the Marchi technique and studied microscopically. The lesion on the left extends to the tip of the temporal lobe, involving the sup-

erior and the middle temporal gyri. The superior and the lateral parts of the amygdaloid nucleus are severely affected. The lateral wall of the temporal horn of the lateral ventricle is open over the entire length of the hippocampus. There is no lesion in the hippocampus anywhere along its course. There is some minimal damage to the most inferior part of the island cortex. The lesion on the right is similar to that on the left; it can be followed to the tip of the temporal lobe in microscopic material. The inferior portion of the island cortex is destroyed. The stria terminalis and the tail of the caudate are completely severed. The amygdaloid nucleus on the right is less severely damaged than that on the left, the lesion destroying only the basolateral part of the nucleus. There is one small lesion in the hippocampus located in its posterior third. This lesion completely divides the alveus on the superior and lateral aspect of the hippocampus and extends into the polymorphic and the pyramidal layers of Ammon's horn but not into the molecular layer.

Degenerated fibers can be followed on both sides from the amygdaloid nucleus into the alveus of the anterior hippocampus where they occupy a medial position (figure 25). Along the course of the hippocampus degenerated fibers from the area of the lesion were traced in the white matter of the temporal lobe, through the inferior temporal and the hippocampal gyri to the alveus and also to the tangential fibers of the molecular layer of the hippocampus. Those fibers which entered the alveus are located medially in the fimbria

and can be followed in this position to the bodies of the fornices (figure 26). The degeneration is also located in the medial half of the body of the fornix. The degeneration is more marked on the left than the right. Degenerated fibers can be followed anteriorly to the region of the anterior commissure where most of the fibers enter the precommissural fornix column to pass to the lateral septal nucleus. There is terminal degeneration in this nucleus and more on the left than on the right. There is a very small amount of terminal degeneration in the medial septal nucleus and a very few degenerated fibers are seen on the left going through the medial septal nucleus to the region of the diagonal band of Broca where some terminal degeneration is found.

The postcommissural components of the fornix columns have a very small amount of degeneration, and of equal amount on each side. The fibers can be followed posteriorly to the mammillary body (figure 27). Terminal degeneration is found in the medial mammillary nucleus. It can not be determined whether there are any fibers turning off and ending in other hypothalamic nuclei. No degeneration is found in the lateral mammillary nucleus and no postmammillary degeneration is seen. The stria medullaris contains a very small number of degenerated fibers which can be traced back to the fornix body. There is a surprisingly large amount of terminal degeneration in the habenular nuclei with relation to the stria medullaris. Other corticohabenular fibers can be seen entering this nucleus from the lateral thalamic fields as well.

Again it is noted that the degeneration in the septal areas remains lateralized with relation to the amount of degeneration in the body of the fornix, but that in the postcommissural and habenular components is of about equal in amount on each side, regardless of the lateralization in the body of the fornix. It appears that 80% or more of the degenerated fibers in the fornix end in the septal area or beyond it, only a very small proportion entering the stria medullaris and the postcommissural fornix columns.

Some of the degenerated fibers of the tangential fiber layer of the subiculum can be followed to the stratum lucidum, the stratum radiatum, and the polymorphic cell layer of Ammon's horn. Terminal degeneration is found in these layers. Some degenerated fibers in the alveus turn off into these same layers. Terminal Marchi granules are also found in the granular layer and polymorphic layer of the dentate gyrus, the fibers reaching this area mostly from the tangential fibers of the molecular layer of the hippocampus. The terminal degeneration about the pyramidal cells of the hippocampus is found in greater amounts on the right. (It will be remembered that there is a lesion in the alveus bundle posteriorly on the right.)

Degenerated fibers enter the indusium griseum. These can be followed superior to the corpus callosum and then, circling around the genu of this body, enter the region of the anterior extent of the hippocampal rudiment. Some of these fibers turn off into the cingulate gyrus along their

path.

Degenerated temporotegmental, temporopontine, and temporothalamic fibers come from the region of the lesion. All of these can be followed to their respective terminations. On the right, the stria terminalis is degenerated and can be easily followed. There is a marked amount of terminal degeneration in the island cortex. A very large proportion of the fibers of the anterior commissure have degenerated, and these can be seen to come from, or go to, the anterior part of the lesion in the temporal lobe on each side.



Figure 24. Photographs of surface lesions of brain of animal 8.

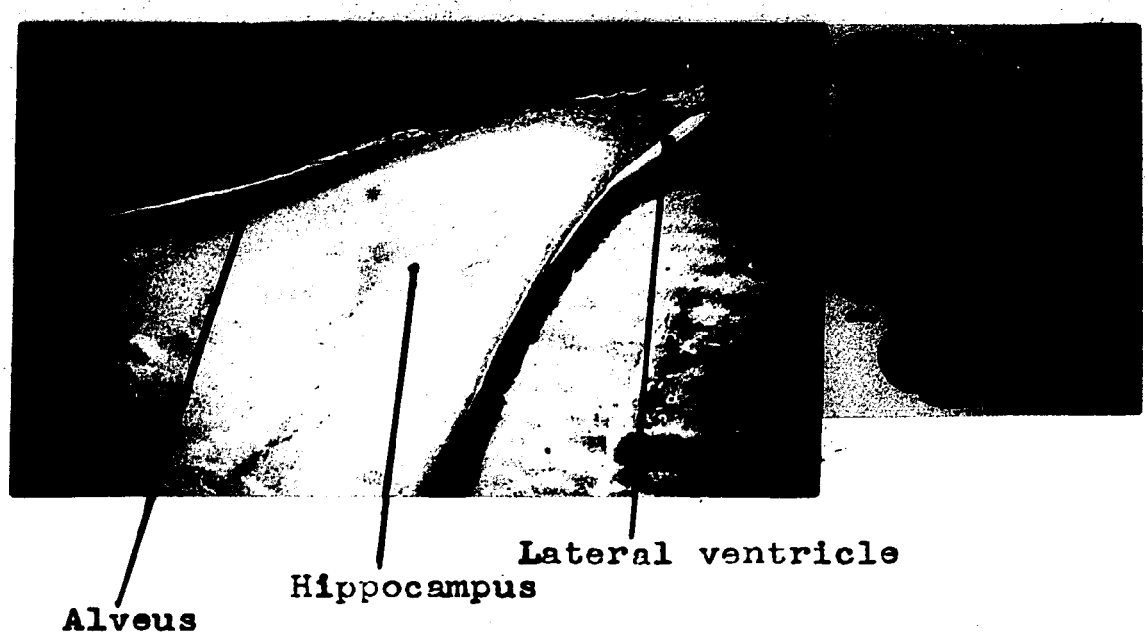

Figure 25. Photomicrograph of the left anterior hippocampus of animal 8 showing degenerated fibers coming from the amygdala and located medially in the fimbria. (Marchi stain, X 17.5)



Figure 26. Photomicrograph of the left fornix of animal 8 showing degenerated fibers in medial position. (Marchi stain, X 50)



Figure 27. Photomicrograph of mammillary bodies of animal 8 showing terminal degeneration of fornix fibers. (Marchi stain, X 17.5)

Animal No. 9

Procedure

This male Macaca mulatta weighed 8.3 kilograms. An attempt was made to study the degeneration results of a relatively small lesion in the cortex in the immediate proximity of the hippocampus, but not involving it directly. After anesthesia was begun, a left craniectomy was performed. With a brain sucker, an attempt was made to make a lesion on the inferior surface of the temporal lobe with the object of destroying the hippocampal gyrus. No stimulation was carried out at this time. After recovery from the anesthetic, the animal showed no defect of any sort.

Fourteen days later a similar lesion was attempted on the right side. After sufficient time was allowed for recovery from the anesthetic, the animal appeared to react normally in all respects. There was no sign of a paralysis or a spasticity. The normal amount of spontaneous activity and hostility were present. He fed himself quite well.

Gross and Microscopic Study

Twenty five days after the second operation the animal was sacrificed as in previous exporiments. The hardened brain was studied for location of the defects (figure 28). On the left the lesion had destroyed the anterior one third of the middle and inferior temporal gyri, and extended into the lateral border of the hippocampal gyrus. From this area there is a posterior extension of the destruction along the infer-

ior temporal gyrus. On the right, the lesion is more circumscribed, being located in the midregion of the inferior temporal gyrus and extending to the adjoining area of the middle temporal and the hippocampal gyri.

The brain was then prepared according to the Marchi technique. Microscopically the lesion extends over a much wider area than is grossly evident. Probably during the operative procedure, retraction of areas of the brain caused sufficient trauma to produce permanent damage. Thus, on the left there is an area of destruction in the inferior part of the superior temporal gyrus, a much wider area of destruction extending both anterior and posterior to the grossly evident lesion in the middle and inferior temporal gyri, and an area of destruction in the cortex of the uncus. Only the most lateral parts of the hippocampal gyrus, for a very short distance in the midregion of the lesion, are involved. On the right, the lesion is located over a smaller area, along the posterior part of the middle third of the inferior temporal gyrus. The adjoining areas of the middle and the superior temporal gyri have been injured. There is slight damage to the most lateral part of the hippocampal gyrus for a very short distance in the midregion of the lesion. The lesion on both sides interrupts the continuity of the cortical layers of the areas described. On the left, the lesion includes the white matter of the inferior temporal gyrus posteriorly and, on the right, the white matter of the inferior temporal gyrus is injured anteriorly. The hippocampi are nowhere involved

in the lesions.

Degenerated fibers can be followed from the area of the lesion of each side, through the white matter of the inferior and hippocampal gyri to both the alveus and the tangential division of the molecular layers of the hippocampus (figure 29). This is true over the entire length of the lesion. However, where the lesion has been deep enough to injure the white matter of the inferior temporal gyrus, there are many more such fibers entering the hippocampal region. The degenerated fibers can not be followed into the fimbria, nor are there any degenerated fibers in the fornix of either side. There are some few granules noted in the septal nuclei, but no degenerated fibers can be followed into these nuclei and this small number of granules can not be clearly differentiated from artefact. There is no significant degeneration in the mammillary nuclei, other hypothalamic nuclei, stria terminalis, habenular nuclei, or indusium griseum.

Marked terminal degeneration is seen in the hippocampus and dentate gyrus. In the hippocampus this is noted in the stratum lucidum and polymorphic cell layers; in the dentate gyrus it is present in the granular and polymorphic cell layers (figure 30). It is most marked in the region where the lesion in the lateral hemisphere extends into the white matter of the inferior temporal gyrus. It is present not only over the entire length of the lesion, but both anterior and posterior to it.

Temporotegmental, temporopontine, and temporothalamic

fibers are degenerated. They come from the area of the lesions and pass to their respective destinations. There are degenerated fibers in the external and extreme capsules. A large number of the fibers of the anterior commissure are degenerated and can be traced to the lesions in the temporal lobes.



Figure 28. Photographs of brain of animal 9 showing surface lesions.

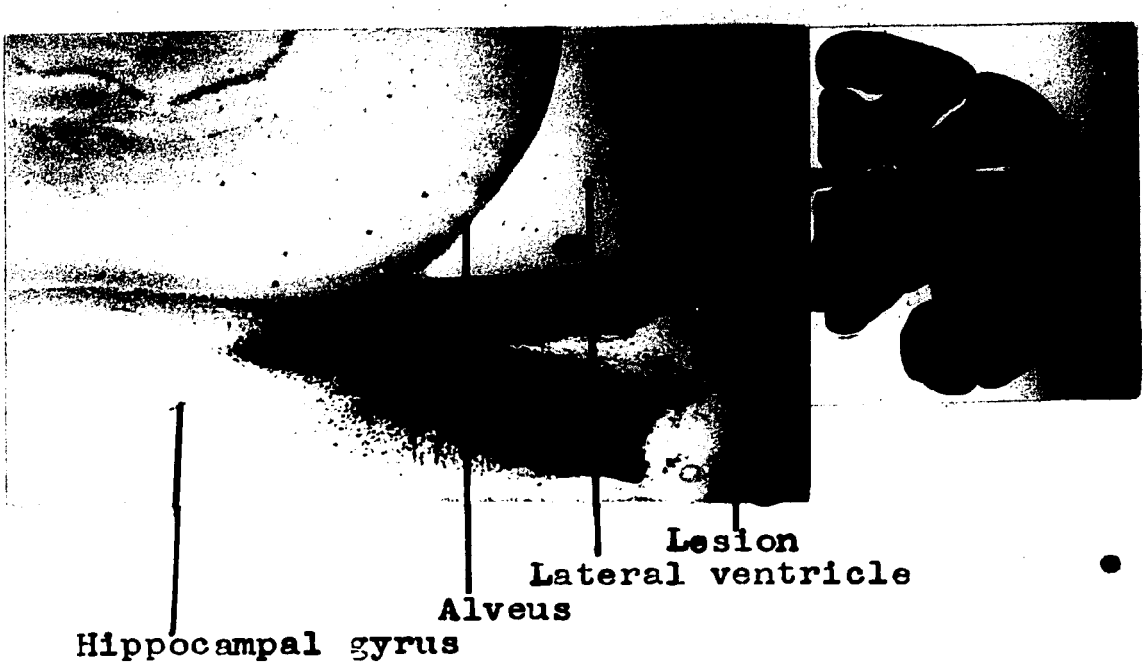

Figure 29. Photomicrograph of the left lesion of animal 9 showing degeneration entering the alvear path. (Marchi stain, X 17.5)

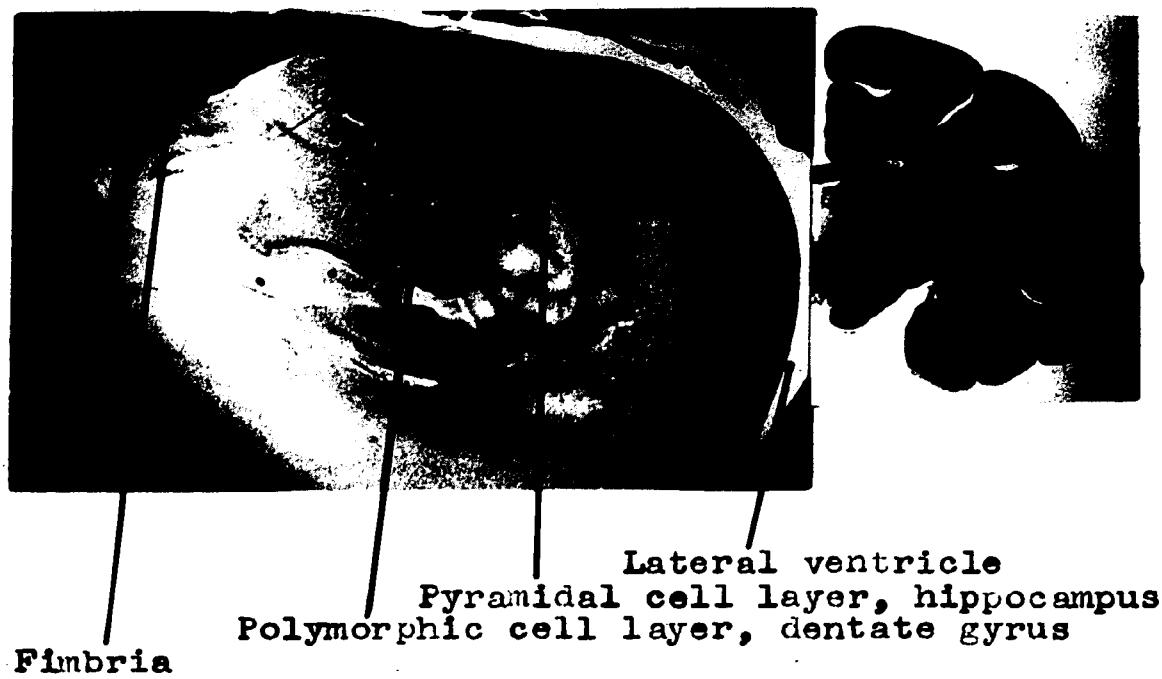

Figure 30. Photomicrograph of the left hippocampus of animal 9 showing terminal degeneration in the hippocampus and the dentate gyrus. (Marchi stain, X 17.5)

Survival Experiments After Stereotaxic Procedures

Animal no. 10

Procedure and Results of Stimulation

This male Macaca mulatta weighed 2.6 kilograms. A stereotaxic operation was performed on the left side by making trephine holes in the skull and the electrode inserted in accordance with predetermined readings. Though movements were obtained, they are invalidated for this study by the microscopic examination of the brain (see below).

Fourteen days after the first operation, the animal was again placed in the stereotaxic apparatus and the electrodes inserted on the right side according to predetermined readings obtained on an autopsied head. Two areas were stimulated and marked with a lesion; one anterior on the hippocampus, just posterior to the pes hippocampi, the other at the posterior-superior levels of the hippocampus. One other area near the posterior point was stimulated but not marked with a lesion.

Stimulation at the anterior point produced bilateral retraction of the corners of the mouth, bilateral opening of the external nares, and bilateral partial closing of the eyelids. While stimulating this area the animal gave a loud, long continued cry of high pitch. With cessation of stimulation this vocalization ceased at once but was repeated each time the stimulation was applied. Stimulation at the posterior point gave weak bilateral face movements similar to

those produced at the anterior point, an extension of the neck, a bilateral elevation of the shoulders, and bilateral flexion of the elbows. Stimulating just superior to this posterior point produced no face movements, but the same movements of neck, shoulder, and elbows as before and, in addition, the closing of both hands. The strength of stimulus employed with the stereotaxic needle electrode was 8 volts.

If the stimulus strength at either of the anterior two points was increased to a range of 10 to 12 volts, and allowed to continue for about 15 seconds, an arousal state, as noted in animal no. 2 appeared. This had the same characteristics as before, except that, with the animals head locked in the stereotaxic apparatus, the movements of the neck and head did not appear to be as definite.

A small destructive lesion was placed with a direct current at the two places stimulated (0.3 mm. amps. for one minute). The surgical lesions were repaired, and the animal returned to his cage. After the effects of anesthetic had worn off, the monkey exhibited no apparent defects. Fourteen days after the second operation the animal was sacrificed, the brain removed, and the material prepared according to the Marchi technique.

Microscopic Study

A microscopic search was made for the electrode paths. On the left two were found, both of which had missed the hippocampus. The anterior one enters the amygdaloid nucleus (where contralateral face movements were obtained) and a

posterior one is located in the region of the external capsule, putamen, and lenticular fasciculus (where gross movements of the arms and legs were noted).

On the right, an electrode path ends in the hippocampus just posterior to the pes hippocampi. It is evident that the tip of the electrode entered the pyramidal cell layer. Another area of stimulation is seen in this same area and it is evident that in this case the molecular layer of the hippocampus had been stimulated. A very small lesion is located in this anterior area. Further posteriorly, at the junction of the third and fourth quarters of the hippocampus, a needle tract leads to a small lesion which destroyed a small area of the hippocampus (polymorphic and pyramidal layers) and the adjoining isthmus fornicatus. Just superior to this point a needle path ends in the pyramidal cell layer of the hippocampus but no lesion was placed here. The points of stimulation are represented in figure 31 and photomicrographs of the electrode paths are seen in figures 32 through 34.

A thorough search of the slides showed no significant Marchi degeneration other than at the sites of the lesion and the electrode paths. Thus a study of the fibers leading from the areas stimulated is not possible.

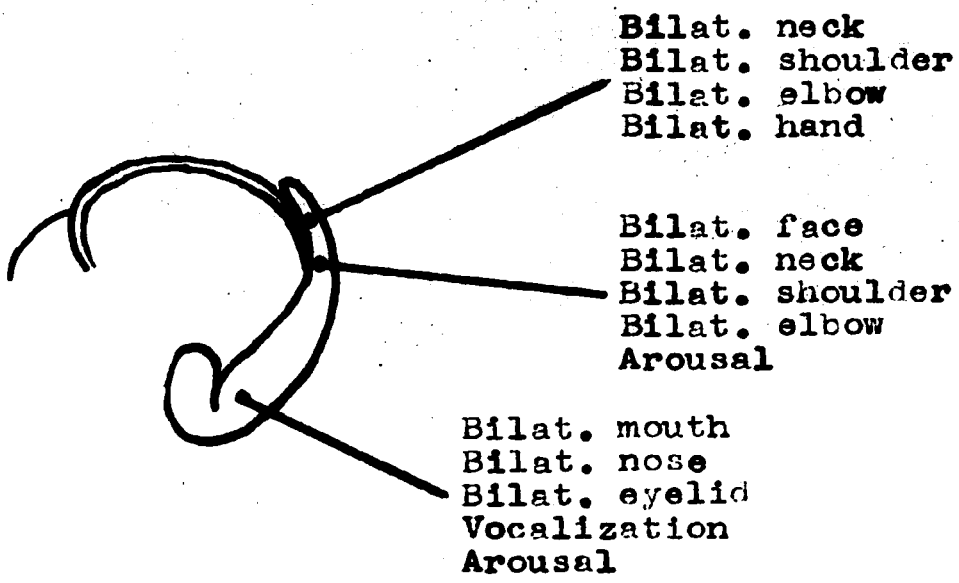

Figure 31. Diagramatic illustration showing locations where movements were obtained in animal 10.

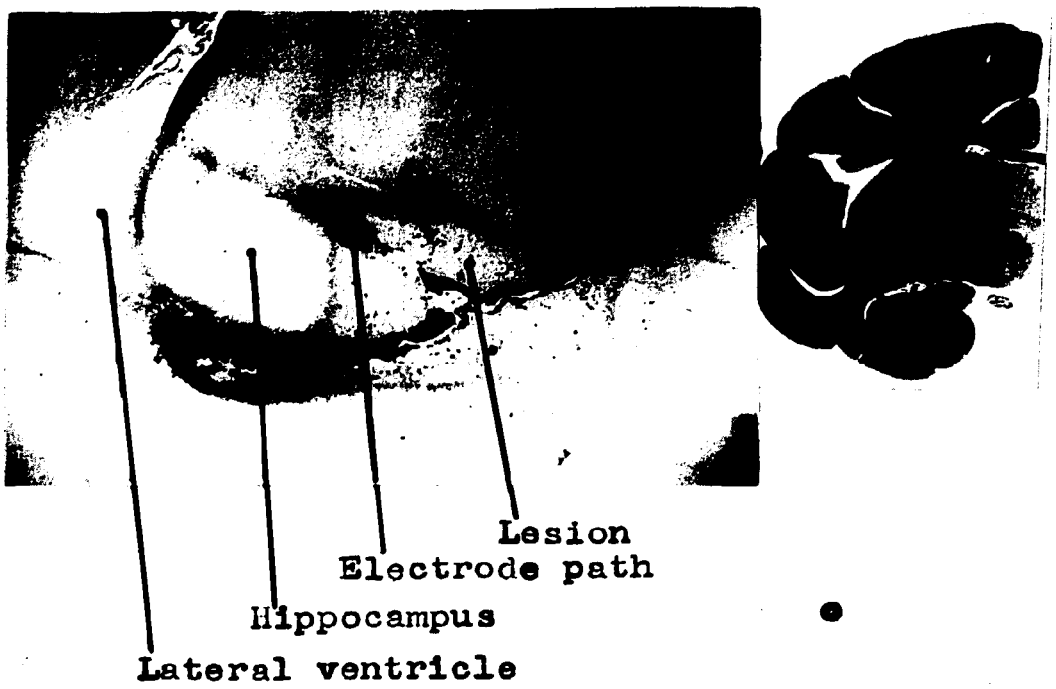

Figure 32. Photomicrograph of right anterior hippocampus of animal 10 showing electrode path. (Marchi stain, X 17.5)

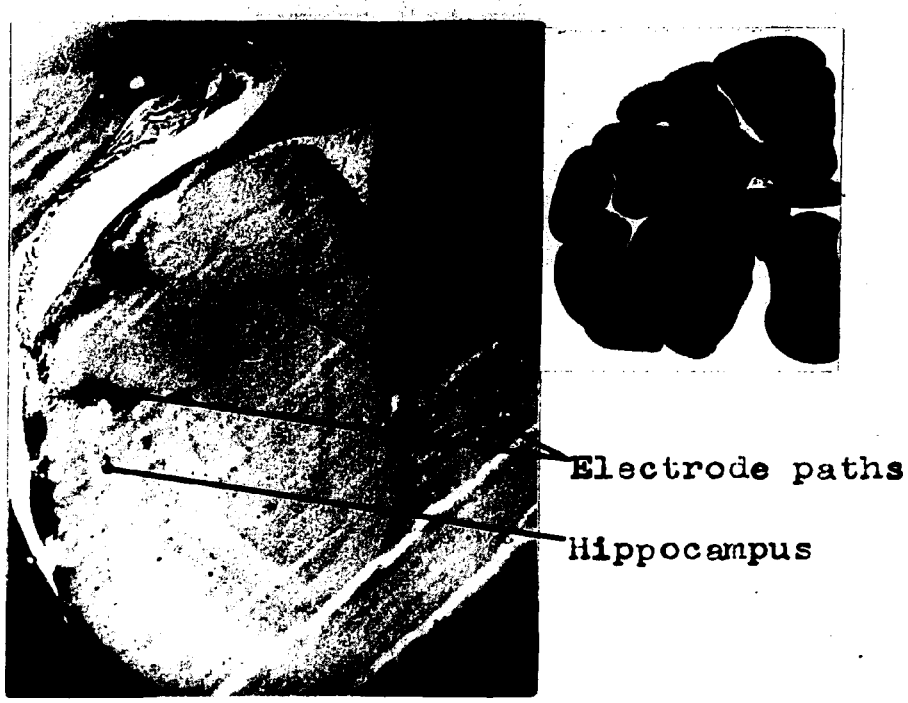

Figure 33. Photomicrograph of right posterior hippocampus of animal 10 showing electrode paths. (Marchi stain, X 17.5)

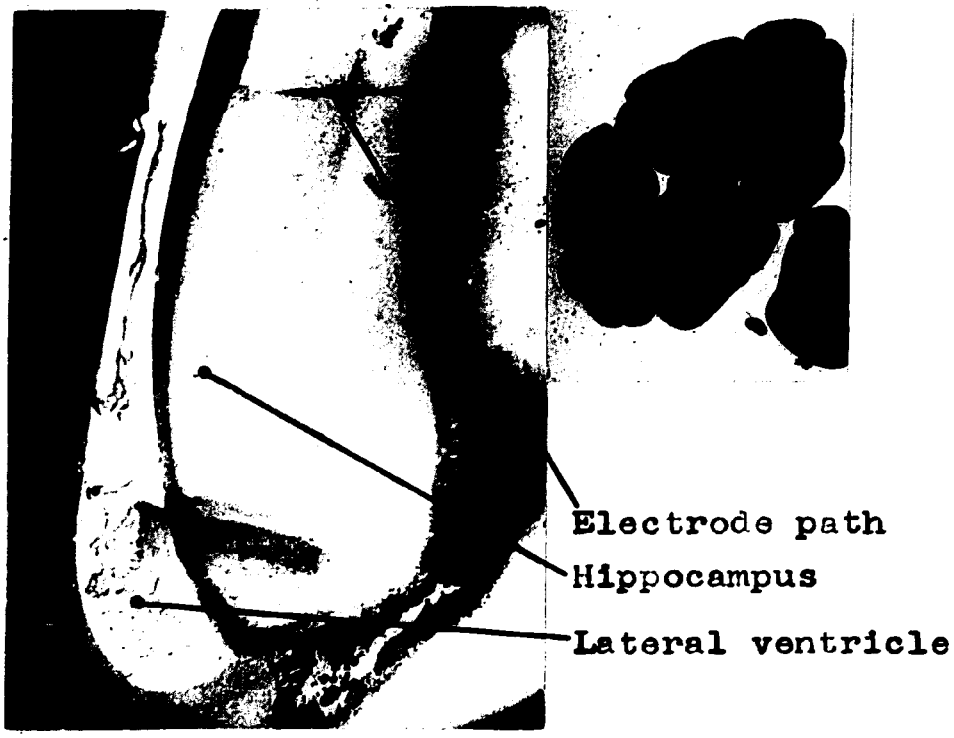

Figure 34. Photomicrograph of right posterior-superior hippocampus of animal 10 showing electrode path. (Marchi stain, X 17.5)

Animal No. 11

Procedure and Results of Stimulation

This male Macaca mulatta weighed 2.7 kilograms. Through trephine holes in the right side of the skull, electrodes were inserted with the aid of the stereotaxic apparatus. Stimulation was then carried out. For control purposes, one insertion was made anterior on the hippocampus, near the pes hippocampi. Two other points were used, both aimed at the most posterior parts of the hippocampus.

Stimulation results were as follows (figure 35): At the anterior point bilateral face movements were obtained as in previous experiments. Farther posterior on the hippocampus stimulation resulted in ipsilateral elevation of the shoulder, ipsilateral flexion of the elbow, and ipsilateral flexion of the wrist. The electrode was placed more superiorly on the hippocampus and stimulation at this time gave the same type of movements as before, but bilateral. Also bilateral face movement, though weak, was noted at this point. Stimulation at all areas was at 7 volts. Small lesions (0.3 mm. amps. for one minute) were placed at the latter two points. The surgical lesions were then repaired and the animal returned to the cage.

Twentyone days later electrodes were placed in a similar manner on the left side of the brain. The hippocampus was stimulated at 4 different points (marked by X's in figure 35). The anterior three points repeated the ipsilateral and bilateral face movements as before. The posterior point repeated

those results obtained on the right side as described above. Stimulation was at 7 volts. However, if voltage was increased to 8.5 at the three anterior points, and allowed to continue for 9 to 12 seconds, an arousal reaction was noted. The movements in this reaction were similar to those in the previous experiments where arousal was obtained. In addition, occasional vocalization occured. It was noted, that with cessation of the stimulation which had caused arousal, the leg movements gradually diminished until no movement was present, over a period of 15 to 30 seconds, but otherwise the animal did not return to a prestimulation condition for 60 to 90 seconds. A lesion (3.0 mm. amps for one minute) was placed at all areas where arousal was obtained.

The surgical lesions were repaired and the animal returned to the cage. After sufficient time had been allowed for recovery from the anesthetic, the animal showed no defects whatsoever. Nineteen days after the second operation the animal was sacrificed by perfusion with 10% formalin, the brain removed, and the material prepared according to the Marchi technique.

Microscopic Study

Microscopic examination was then carried out. A search was made for the electrode paths. Several were found and were used to locate the points of stimulation, as shown in figure 35. Most of such electrode paths pass through all the layers of the hippocampus. Since, during the operation, stimulation is carried out at 1 mm. intervals after the elec-

trode is placed deep enough to enter the hippocampus, it is evident that all layers of the hippocampus were stimulated in its posterior regions, and at some levels the subiculum as well. The results as reported were the same, regardless of the layer stimulated. In the anterior regions, some of the electrode paths enter through the alveus, the polymorphic cell layer, and the stratum lucidum of the inferior aspect of the hippocampus, and then the subiculuar region of the hippocampal gyrus. Again, where movements were obtained, they were the same, whether stimulating the hippocampus or the subiculum.

There is a lesion on the left, destroying the lateral aspect of all layers of the anterior two thirds of the hippocampus. In the midregion of the lesion, the dentate gyrus had been involved. Throughout the whole length of the lesion, there is destruction of the subiculum. There is no significant lesion in the cortex of the temporal lobe except that of the subiculum.

No Marchi granules can be found in the fornix, septal nuclei, diagonal band of Broca, stria medullaris, habenular nuclei, postcommissural fornix, or mammillary bodies. There is terminal degeneration about the pyramidal and polymorphic cell layers of the hippocampus medial to the lesion and also in the region of, and posterior to, this lesion. Degenerated fibers are present leading from the lesion and extending into the white matter of the temporal lobe (figures 36 to 38). Some turn off in fairly large numbers to the hippocampal

gyrus; others enter the superior, the middle, and the inferior temporal gyri. These last are diffuse, small in number, thinly medullated, in small fasciculi, and are spread over a wide area.

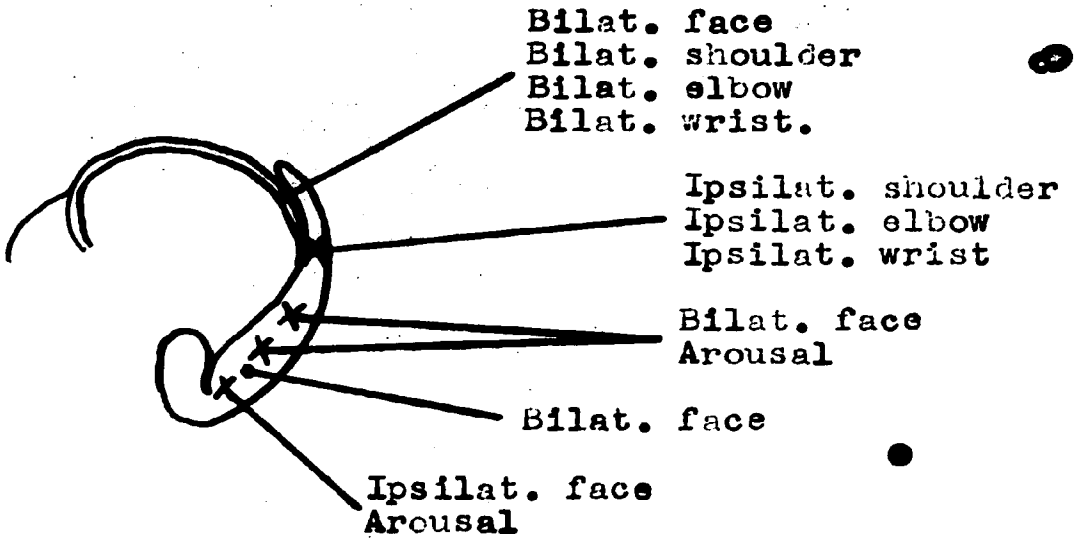

Figure 35. Diagramatic illustration showing locations where stimulation produced movements in animal 11. "•" represents points on the right side; "X" on the left.

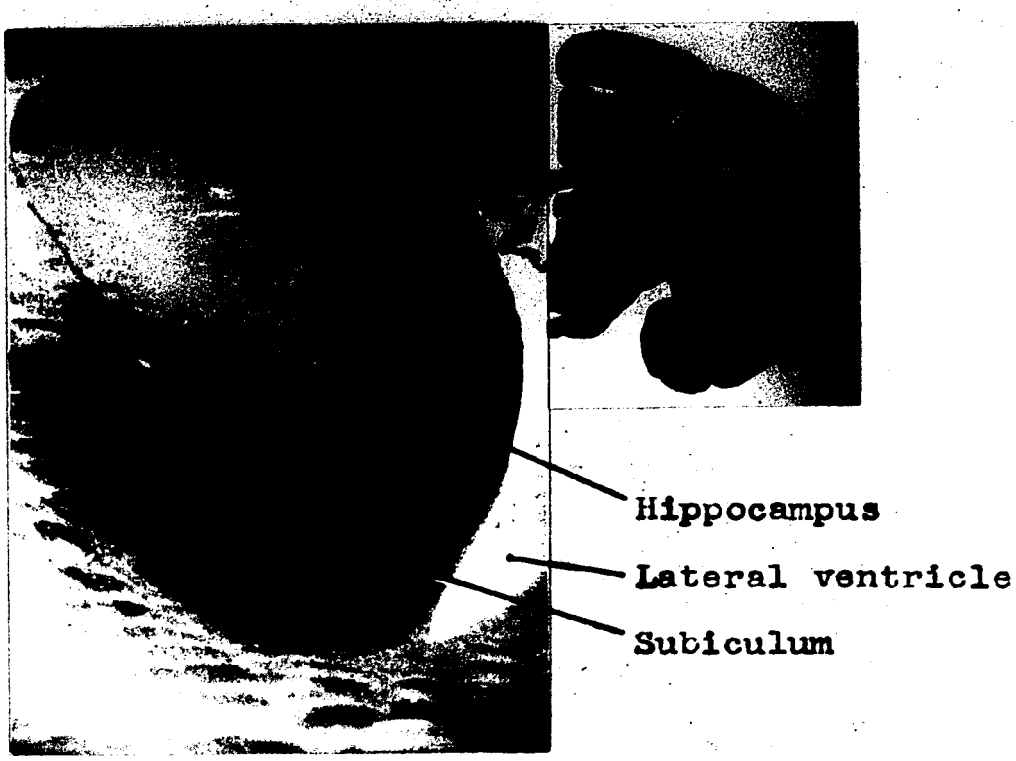

Figure 36. Photomicrograph showing the lesion in the left hippocampus of animal 11. (Marchi stain, X 17.5)

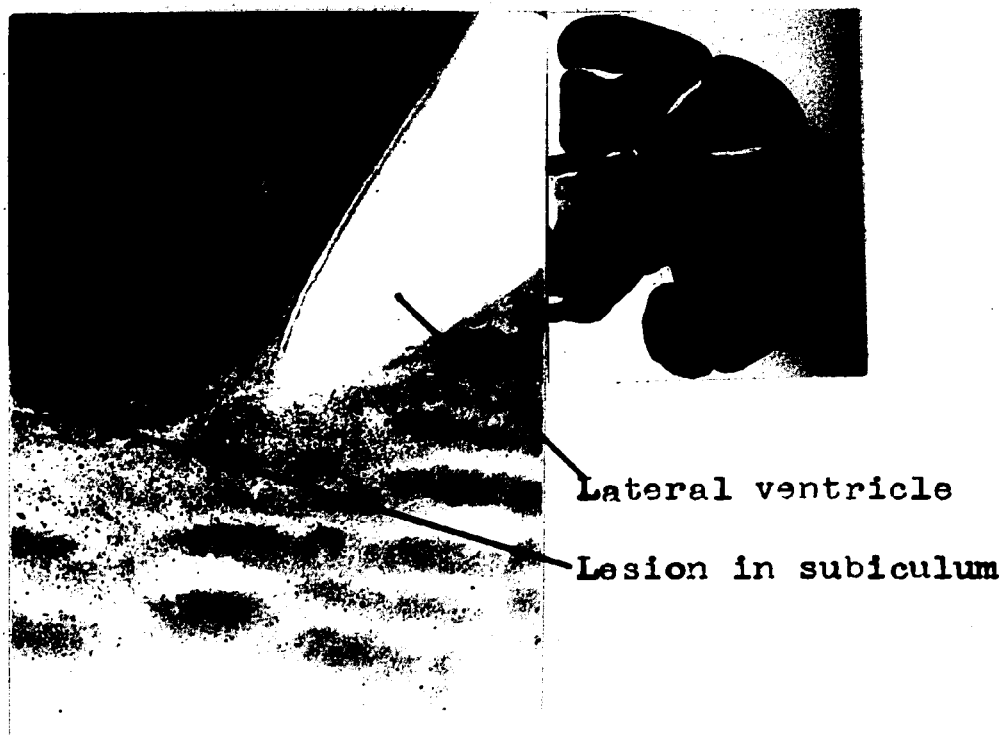

Figure 37. Photomicrograph showing degenerated fibers coming from the lesion of animal 11 and entering the white matter of the temporal lobe lateral to the lateral ventricle. (Marchi stain, X 50)

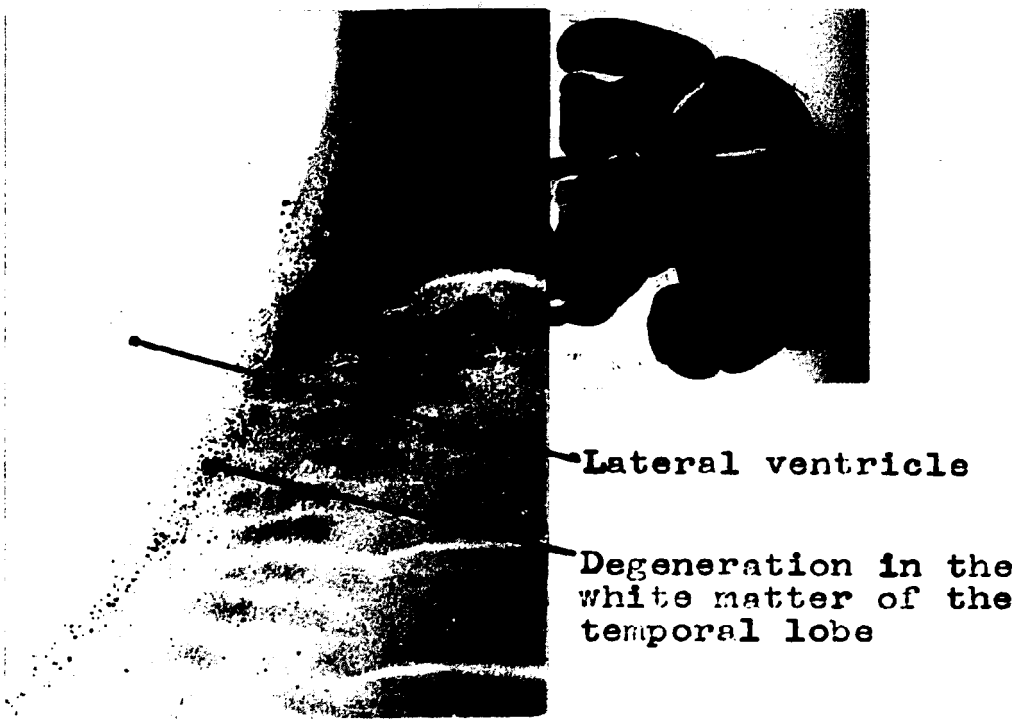

Figure 38. Photomicrograph showing degenerated fibers lateral to the lateral ventricle in animal 11 with some fibers turning off into temporal lobe areas. (Marchi stain, X 50)

Animal No. 12

Procedure and Results of Stimulation

This male Macaca mulatta weighed 2.8 kilograms. An attempt was made to stimulate, with the aid of a stereotaxic apparatus, the region of the anterior column of the fornix or the septal nuclei. The animal was anesthetized, a trephine hole made in the cranium, and the electrode inserted. Stimulation was then carried out.

Stimulation at this one setting caused a bilateral retraction of the corners of the mouth, bilateral flaring of the external nares, a partial closing of both eyes, extension of the neck (bilateral contraction of the deep neck muscles), and some slight elevation of both shoulders. Other than the apparent ease with which the animal aroused from the anesthetic during this stimulation, he showed no signs of arousal. Stimulation was at a range of 6 to 8 volts. A small lesion (0.3 mm. amps. for one minute) was placed at the point stimulated. The surgical lesions were repaired and the animal returned to his cage.

After recovery from the anesthetic, the animal reacted normally in all respects. Sixteen days after the operation he was sacrificed, the brain removed, and the material prepared by the Marchi technique for microscopic study.

Microscopic Study

Due to a technical error in the preparation of the material, the brain tissue became very brittle and sectioning

shattered it badly, making any study of the fiber path degeneration impossible. However, the location of the electrode could be determined. During stimulation the tip of the electrode had been located in the left lateral septal nucleus, anterior to the column of the fornix (figure 40).



Figure 39. Diagramatic illustration showing the location where stimulation produced movement in animal 12.

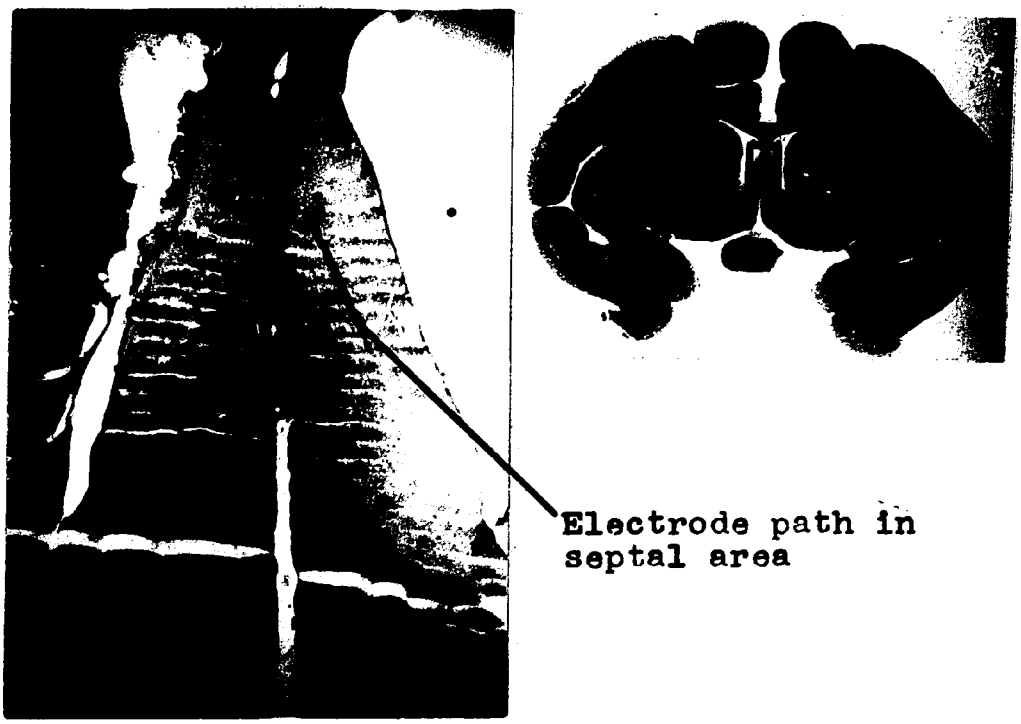

Figure 40. Photmicrograph showing position of the electrode path in the left septal area of animal 12. (Marchi stain, X 17.5)

RÉSUMÉ OF EXPERIMENTAL OBSERVATIONS

By combining the stimulation results of all the experiments, we have obtained a pattern, which is demonstrated in figure 41. The following facts should be brought to mind concerning the pattern of movements obtained.

1. The face area, including ipsilateral and bilateral movements, occupies the entire anterior two thirds of the hippocampus.

2. Other than during arousal, lower extremity movement was not obtained.

3. Arousal is elicited over the middle third of the hippocampus.

4. Stimulating the fornix gives the same responses as stimulating the hippocampus.

5. Severing the fornix does not alter the stimulation pattern on the hippocampus.

6. Severing the fornix eliminates the responses resulting from stimulating the fornix anterior to the cut, but does not eliminate the responses from stimulation posterior to the cut.

7. Severing the hippocampus from the subiculum eliminates the results of stimulation along the hippocampus.

8. There is a pattern from medial to lateral across the fimbria-fornix, the same responses obtained anteriorly on the hippocampus being obtained medially on the fimbria-fornix.

9. Temporary effects were noted on respiration.

10. Vocalization was obtained in one animal only and this was from the center of the face region.

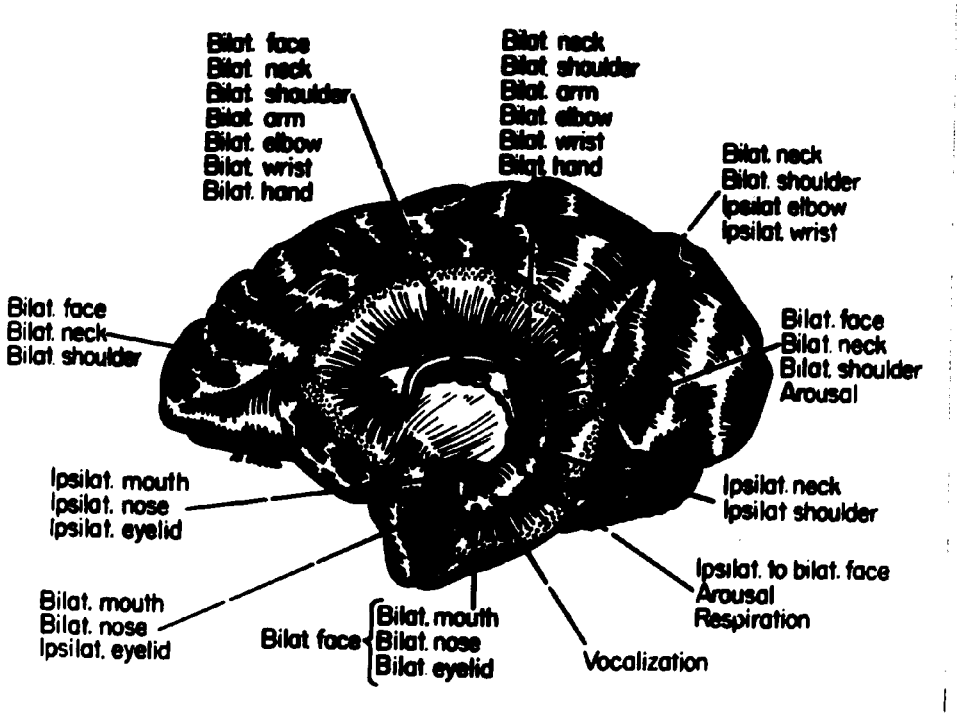

Figure 41. Diagramatic résumé of positions where stimulation gave movements in these experiments.

On combining all of the Marchi studies, we note the following facts.

1. Lesions of the hippocampus result in degeneration of fibers within the fornix.

2. Even with complete removal of the hippocampus, the amount of degenerated fornix fibers is less than 50% of the total number of fornix fibers.

3. The largest proportion of degenerated fibers in the fornix as a result of hippocampal lesions enters the precommissural fornix column.

4. The degenerated fibers in the precommissural fornix column, which are continuous with the degenerated fornix fibers, end mainly in the lateral septal nucleus. There is also a small distribution to the medial septal nucleus and the diagonal band of Broca.

5. The smaller proportion of degenerated fibers in the fornix, as a result of hippocampal lesions, enters the postcommissural fornix column.

6. The degenerated fibers in the postcommissural fornix column, which are continuous with the degenerated fornix fibers, end chiefly in the medial mammillary nucleus. There is also a small distribution to the hypothalamus anterior to the mammillary body and to the habenular nuclei.

7. None of the fibers in the postcommissural fornix column, which degenerated as a result of hippocampal lesions, pass posterior to the mammillary body.

8. Fibers arising anteriorly in the hippocampus lie medially

in the body of the fornix, and fibers arising posteriorly lie laterally in the fornix body.

9. There are intrahippocampal degenerated fibers found in the fimbria, both anterior and posterior to lesions in the hippocampus.

10. The intrahippocampal fibers turn out of the fimbria and end in the stratum lucidum and stratum radiatum of the hippocampus, and in the granular and polymorphic cell layers of the dentate gyrus.

11. Lesions in the hippocampus result in commissural degenerated fibers, ending in the stratum radiatum and stratum lucidum of the hippocampus of the opposite side, and in the granular and polymorphic cell layers of the dentate gyrus on the opposite side.

12. Degenerated fibers resulting from hippocampal lesions turn out into the white matter of the temporal lobe and end in the hippocampal gyrus, the inferior and middle temporal gyri, and in the superior temporal gyrus.

13. Lesions of the hippocampal gyrus and the lateral temporal area of the hemisphere result in degenerated fibers, which enter the hippocampus via the perforating and the fimbrial paths, and end in stratum lucidum and statum radiatum of the hippocampus and in the granular and the polymorphic cell layers of the dentate gyrus.

It is also observed that partial lesions of the hippocampus, even when bilateral, have no effect on the behavior of the animal. However, complete bilateral removal of the

hippocampi produces an apathetic and lethargic animal who lacks spontaneous activity and reacts inappropriately to external stimuli.

DISCUSSION

For the microscopic portion of this study, the Marchi technique as modified by Swank and Davenport ('35) has been used. This will then necessarily limit the study to the degenerated myelinated paths of the central nervous system. It will be noted in these studies that the survival times in most of the experiments are much longer than the usually accepted times of 14 to 21 days. Those specimens which came from the animals having long survival periods following the surgical procedure are mostly better in quality than those from animals with short survival times. This is quite in accord with a recent study by Smith ('56a) who has noted the differences in the staining resulting from different survival periods. He concludes that probably not all fibers, for reasons unknown, degenerate at the same speed. Certainly, from the study at hand, it would seem that the degeneration, at least in the hippocampal system, occurs later than has been usually expected for the primate brain.

Artefacts are a common finding in the use of this technical method. These can be controlled, as was suggested by Davenport and Swank ('35) and Smith ('56b). Smith has listed some of the artefacts and the precautions to be used in both preparing and reading the slides. In this study, these suggestions were followed as closely as possible.

Probably because the early studies of the hippocampus

were primarily comparative, and also because most of the early study was on normal material, the hippocampus became associated with the function of olfaction. Indeed, it is a part of the telencephalon which first developes, phylogenectically, in relation to the first, or olfactory nerve. This complete association with the olfactory function has never been properly documented for primates. Even the earlier writers in the field suspected that the hippocampus did not serve solely for olfaction. Ferrier (1886), reporting results of stimulation of the hippocampus, localized in this structure what he termed feeding reactions, basing his conclusions on the type of movement that he obtained.

From a combined phylogenetic (Kappers, Huber, and Crosby, '36; Allison, '53) and ontogenetic (Johnston, '13; Hines, '22; Macchi, '51) point of view, it is found that even in the most primitive vertebrates, there is a section of tissue about the foramen of Monroe, or its primitive representative, that contains most of the characteristic connections of the primate hippocampus. On this basis this area has been called the primordial hippocampus. This primordial hippocampus is only one of the many components of the rhinencephalon of the mammals. Thus Humphrey ('36), Fox ('40), and Jeserich ('45) point out that in the bat, cat, and mink, respectively, the medial septal nucleus, the septal hippocampal nucleus, the anterior continuation of the hippocampus, the indusium griseum, and the hippocampus proper are the more elaborate representation of the primordial rhinencephalon. Of these areas, the

septal and anterior continuation of the hippocampus are the only ones which receive secondary olfactory fibers. It would seem in this respect, then, that the hippocampus is at least one synapse removed from the secondary olfactory fibers, and perhaps more.

As the hemisphere of the telencephalon developes, the hippocampal formation is drawn out and the hippocampus proper comes into close spatial arrangement with the temporal lobe. As one can see, the areas mentioned above, together with the cingulate area which is in close association with the indusium griseum, the diagonal band which is in close relation to the septal and anterior hippocampal areas in the higher vertebrates, and the hippocampal gyrus (entorhinal area) which is in close relation with the hippocampus, form a ring about the medial side of the hemisphere. This ring is what Broca (1878) called the limbic lobe. It appears that only a very small part of the limbic lobe receives secondary olfactory fibers (that is, fibers arising from cells in the olfactory bulb) in the higher vertebrates. This removes the hippocampus from a direct projection of olfactory impulses, but does not, by any means, eliminate the possibility that the hippocampus has something to do with the sense of smell.

One may, on a phylogenetic basis, compare certain anosmatic animals with certain macrosmatic animals. Many studies have been carried out on the Cetaceans, especially by Ries and Langworthy ('37), Langworthy ('32), Breathnach ('53), Breathnach and Goldby ('54) and Addison ('15). These aquatic

mammals are characterized, among other things, by having a very rudimentary or a complete absence of the olfactory nerves. In spite of this, the above authors report that the hippocampus, though comparatively smaller than that in other mammals, is still present, and all layers are recognized. The dentate gyrus in these animals more closely reflects the absence of the olfactory nerve. Steward ('39) reported a case of human archiencephaly where there was an absence of the olfactory bulb and tract. The hippocampus was only slightly reduced, and the fascia dentata was absent. In this same article, the author reviews the literature, where only one such case has been reported in which the dentate fascia was present. All patients reported upon had a fairly normal-appearing hippocampus. In contrast to these results, Clark ('28) studied an insectivore, which is an animal with a very large olfactory nerve. Here the hippocampus also was extremely large so that it even distorted the appearance of the rest of the brain.

Abbie ('42) studied the corticalization in the marsupial, and M. Rose ('27) and S. Rose ('27), both of whom studied the phylogeny of the hippocampus, found that the cortical layering is more complex, more differentiated, and relatively greater in size in primates and in man than it is in subprimate forms. These authors concluded that the hippocampus (that is the cornu Ammonis) reaches its highest development in man.

Associating the combined phylogenetic facts, and thinking in a phylogenetic sense, we can consider that the hippo-

campus probably has no primary olfactory projections in primates but is influenced by secondary olfactory associations.

On purely anatomical grounds, many of the earlier authors doubted the direct connection of the hippocampus to olfaction in primates. Ramón y Cajal ('01, '11), Golgi ('03), and Lorente de No ('33, '34) reported that there were no direct connections to the hippocampus, and indeed, were not even direct connections to the major portion of the piriform (entorhinal) area from the olfactory bulb. They described the entorhinal area as being in intimate connection with the hippocampus. Elliot Smith (1896) in a discussion of the fornix superior, indicated the probable lack of primary olfactory areas in the hippocampus. Several anatomical studies of the telencephalon in various vertebrates are reported (in normal material of the rat by Gurdjian, '25; of the bat by Humphrey, '36; of the rabbit by Young, '36; of the cat by Fox, '40; of the mink by Jeserich, '45; of the rabbit by Clark and Meyer, '47; and in experimental material of the monkey by Meyer and Allison, '49; and of a marsupial by Adey, '53) in which secondary olfactory fibers from the olfactory bulb can not be found to extend to the entorhinal area. Tertiary olfactory projections, however, have been found by some of these authors, in the lower mammals, to the entorhinal area, hippocampus, and dentate gyrus. It should be pointed out that if tertiary olfactory fibers reach the hippocampus, then the hippocampus is no less a projection area than the postcentral gyrus, which also receives tertiary fibers in its own

projection system. Since these connections are far less prominent in primates, probably reflecting the decrease in olfactory function of the animal, the hippocampus evidently takes on new functions. This does not remove the possibility that olfactory impulses still play an important part in the workings of the normal hippocampus.

The above anatomical results have been verified physiologically by the evoked potential technique by Adrian ('42) in the hedgehog, Allen ('43) in the dog, and Fox, McKinley and Magoun ('44), and Berry, Hagamen, and Hinsey ('52) in the cat. By stimulating the olfactory bulb, and recording the potentials resulting, they found that the secondary olfactory fibers arising from the area stimulated ended in the prepiriform cortex, anterior olfactory lobe, olfactory tubercle, and, after longer latency, in the piriform lobe. There were no responses obtained in the septum, diagonal band of Broca, or the hippocampus. Allen also passed air through the nostrils containing different odors, and noted spike potential changes over the same areas. Berry et al did get potentials in the piriform lobe and hippocampus, but only after long latency periods, and concluded that the impulses only reached these areas after going through one or two synapses in passage. Thus the physiologic data upholds largely the anatomical data.

The studies of Ramón y Cajal, Lorente de No, M. Rose, and S. Rose, all mentioned above, clearly demonstrated a prominent and relatively large fiber connection from the

entorhinal area (hippocampal gyrus) to the hippocampus and dentate gyrus by the alveus and perforating paths. Allen ('48) demonstrated these paths by the Marchi technique in dogs. Pribram, Lennox, and Dunsmore ('50) using strychnine physiologic neuronography stimulated the entorhinal area and obtained potentials in the hippocampus. The present experiments 3 through 7 suggest that such a path exists, and experiments 8 and 9 demonstrate its existence. We find that it is a diffuse path and enters the hippocampus along its whole length from all the adjoining extent of the hippocampal gyrus. Experiment 9 also shows that fibers reach the hippocampus from farther distances away, such as the superior and the middle temporal gyri.

Since there is a large connection to the hippocampus from the entorhinal area, it would be of some interest to review the evidence as regards the afferent supply of the entorhinal area. We have already seen that some tertiary olfactory fibers may reach this area in small numbers. Again, Ramón y Cajal reported that fibers reach this area from the cingulum, the adjoining temporal lobe area, and a very few from the prepiriform area. It has already been stated above that Berry et al had obtained evoked potentials in the entorhinal area from stimulation of the olfactory nerve, indicating that they arrived there only after one or more synapses. MacLean, Horwitz, and Robinson ('52) have confirmed this. Anatomical studies concerning these findings are few. After experimental lesions in the monkey, Adey and Meyer ('52a)

found fibers in the cingulum, arising on the medial aspect of the frontal lobes and ending, in part, in the presubiculum. Adey ('55) traced degenerated fibers ending in the subiculum and presubiculum which had reached these areas by way of the cingulum, following lesions of the retrosplenial and posterior cingulate regions of the rabbit. Adey and Meyer ('52b) also found afferent fascicles entering the entorhinal area from the superior temporal gyrus. In a study of the commissural connections of the regions concerned Cragg and Hamlyn ('57) in the rabbit and Blackstad ('56) in the rat reported that the entorhinal area is connected with the same area of the other side by the hippocampal and anterior commissures, and that some fibers arising in the hippocampus of one side end in the entorhinal area of the other side.

Walker ('37) described the primary auditory projection area to the temporal lobe. Mickle and Ades ('54) described a primary vestibular area in the temporal lobe also. With these exceptions, no other part of the temporal lobe appears to be a primary projection area. Because of this, Bucy and Klüver ('40) point out that aside from the auditory (and vestibular) projection areas, the temporal lobe receives no other afferent impulse directly from the thalamus, but any afferent impulses reaching the temporal cortex must arrive there indirectly. They therefore conclude that this area is most aptly called a true association cortex.

Several investigators, using the evoked potential technique, have followed afferent impulses into the entorhinal

area. Thus Patton ('50) and Patton and Amassian ('52) stimulated the chorda tympani nerve, and found impulses (presumably gustatory) in the entorhinal area of the cat. Dell and Olson ('51) had similar results from stimulation of the vagus nerve (visceral afferent). MacLean, Horwitz, and Robinson ('52) and Clark ('52) report such potentials to auditory, visual, and somatic stimulation in rabbits, cats, and monkeys. The former authors report that these responses appear to be similar in all respects to those obtained by stimulation of the olfactory nerve. Other investigators, using the same technique, have followed afferent impulses into the hippocampus itself. Robinson and Lennox ('51) obtained responses in the hippocampus to optic, auditory, and sensory stimuli in the cat, as did Green and Arduini ('53) in the rat, cat, and monkey. These last authors ('54) found that stimulation of certain areas of the brain stem gave arousal responses in the hippocampus. Green and Machne ('55) obtained a field of diffuse but well defined electrical activity of the pyramidal cells of the hippocampus on somatic stimulation.

It would then appear that there is evidence that the hippocampus receives, at least in the higher mammals, much more than just olfactory stimuli and that, in fact, it receives a large variety of afferent stimuli. If this be true, we have then an area representing a somatic-visceral association or correlation region. Such an area might well be related to the building up of emotion or at least of emotional

expression.

In his review, Brodal ('47) concluded from the anatomic and physiologic data at hand, that the hippocampus was an effectory structure. The fornix has been considered for some time as the efferent pathway of the hippocampus. In descriptions of normal material, many of the earlier authors (Ramón y Cajal, '01, '11; Lorente de No, '33, '34; and others reported in Kappers, Huber, and Crosby, '36) described various connections of the fornix to the habenula, anterior thalamic nuclei, septal area, nucleus accumbens, preoptic area, diagonal band of Broca, mammillary body, hypothalamus anterior to the mammillary body, and midbrain posterior to the mammillary body. Nauta ('56), using the silver technique designed by himself, confirmed all of these connections in the rat. Gerebtzoff ('39, '42), in addition to the above connections, found fibers to the pineal, the lateral hypothalamic area, and the tegmentum near the raphe. He found that all such connections were homolateral. Many other observers have studied this system. Observations on normal material have been made by Loo ('31) in the opossum, Marburg ('44) in man, and Jeserich ('45) in the mink. Experimental work has been carried out by Fox ('43) in the cat, Allen ('44) in the dog, Sprague and Meyer ('50) in the rabbit, Morin ('50) in the guinea pig, Crosby and Woodburne ('51) in the monkey, Simpson ('52) in the monkey, Daitz and Powell ('55) in the rat, the rabbit, and the monkey, Powell and Cowan ('55) in the rat, the rabbit, and the monkey, Mclardy

('55a, '55b) in the monkey, and Guillery ('56) in the rat.

In spite of various species differences, all of the above authors are in agreement on most of the findings. All report degeneration of fibers ending in the mammillary body. Sprague and Meyer, and Guillery both suggested that some of the fibers to the mammillary body are crossed. In our experiments it was noted that the degeneration in the mammillary bodies is almost always equal, and indicates a bilateral distribution to this area. Many authors have indicated that there is a postmammillary component of the postcommissural fornix column; however, this varies in size among the mammalian species, being found particularly clearly in the rabbit and the rat. Our own work does not show any evidence for postmammillary fibers in the fornix system of the monkey.

The earlier authors mentioned found fibers of the postcommissural fornix ending in other hypothalamic nuclei as well as the mammillary body. While most of the recent authors neglect to comment on this fact, Powell and Cowan and Crosby and Woodburne found them, Allen suggested that they were present, and Sprague and Meyer denied their existence. Since in the Marchi technique the actual ending of the fibers can not be found, the results are only suggestive, but it is very probable that such fibers extend at least to the ventromedial hypothalamic nucleus.

None of the previous investigators has mentioned the proportion of fibers in the postcommissural fornix which arise in the hippocampus. Certainly, according to our own

experiments, very few fibers of the postcommissural column originate in this area since complete ablation of this structure resulted in only partial degeneration of the column. It is evident that part of the discharge to the mammillary body and other hypothalamic nuclei originates in areas other than the hippocampus.

Many observers have noted a discharge from the fornix into dorsal thalamic structures, mainly the anterior thalamic nuclei. Nauta has recently reported such a connection. Guillery also observed this termination. Other workers have not mentioned it and we must assume that such fibers were not found. Neither are any such fibers degenerated in the present experiments.

Nauta and Marburg are recent experimentalists that have described a habenular connection in the fornix. Sprague and Meyer did not find one. The present experiments show that this connection is small, but present, and is bilateral.

Again, the earlier authors reported precommissural fornix fibers ending in the septal nuclei, the nucleus accumbens, the preoptic area, and the diagonal band of Broca. Fox found Marchi degeneration in the lateral septal nucleus as did Jeserich. McLardy reported a moderate termination in this nucleus after the fornix fibers had crossed, but most observers have found these endings to be homolateral. In the degeneration studies at hand, there is a marked degeneration in the lateral septal nucleus, with a partial degeneration on the opposite side, signifying some crossing of the fibers.

There is also degeneration in the diagonal band of Broca. We did not find any degeneration in the nucleus accumbens or in the preoptic area that we could clearly differentiate as being of fornix origin.

We notice, in this work, that complete transection of the fimbria results in total degeneration of the fimbria only in the immediate region of the lesion. After complete removal of the hippocampus, as in experiments 6 and 7, there are no more than 50% of the fibers of the body of the fornix degenerated. This indicates that some of the fibers in the body of the fornix originate from regions other than the hippocampus. We can then not agree with Allen ('44) that all of the fibers of the fornix are hippocampal in origin. McLardy ('55b) in the monkey and Daitz and Powell ('54) in the rat, the rabbit, and the monkey reported retrograde cell degeneration in the medial septal nucleus after transection of the body of the fornix. Crosby ('17), Kappers, Huber, and Crosby ('36), and Morin ('50) all described septoammonic paths within the fornix. These same paths were denied by Ramón y Cajal and Lorente de No. Most of the present anatomical investigations also deny such fibers. By the evoked potential technique, Campbell and Sutin ('53) and Green and Adey ('56) obtained responses in the hippocampus on stimulation of the septal area. Green and Arduini ('53, '54) noted that the hippocampal responses to brain stem stimulation, and to visual, auditory, and somatic stimuli, were eliminated by lesions of the fornix and the septal region. Cragg and Hamlyn ('57) and

Stoll, Ajmone-Marsan, and Jasper ('51) picked up impulses in the presubiculum and the temporal pole following stimulation of the septal area in the rabbit and the cat. Such observations indicate that the septal area discharges to the hippocampal region and that these discharges take place through the fornix system. Petr, Holden, and Jirout ('49) found a close, two-directional association of the temporal pole with the hippocampus. We can not, then, agree with Allen ('44) that the fornix is, "solely an efferent tract."

As alluded to by some authors (Ramón y Cajal, '11; Lorente de No, '33, '34) we find evidence of intrahippocampal association fibers. Localized lesions of the hippocampus result in degeneration in the hippocampal layers both anterior and posterior to the lesion. Morin ('50) also found such fibers.

Although no precise localization pattern can be mapped from our experiments, we note that there is a definite efferent discharge of the hippocampus which is projected to most of the temporal lobe. This is given further importance when results of stimulation of the hippocampus are eliminated by separating it from the subiculum, but not from the fornix. We can not agree with Sprague and Meyer ('50) that, "The fornix represents the only known efferent pathway of the hippocampus." Morin and Green ('53) and Green and Adey ('56) found, by evoked potential technique, that stimulation of the hippocampus resulted in a discharge into the lateral part of the temporal lobe. Such discharge was not eliminated by fornix

section. It appears that the efferent discharge of the hippocampus by way of the temporal lobe is an important one.

Our experiments show a rather liberal commissural connection between the hippocampi of the two sides. This is in full accord with the recent reports of Blackstad ('56) and Cragg and Hamlyn ('57). These authors report the crossing in the ventral hippocampal commissure. We have found degeneration in this commissure but find it difficult to follow the degeneration from the hippocampus of one side to that of the other. Though we can not confirm these findings completely, our results are in agreement with those of the above authors.

The function of the hippocampus has been rather difficult to determine. In an ateempt to analyse whether the hippocampus had anything to do with olfaction, Swann ('34, '35) conditioned rats to an olfactory stimulus, and then removed large areas of the cerebrum. He found that removing the hippocampus and other rhinencephalic structures did not interfere with the conditioned response. Allen ('38, '39, '41) carried out a series of similar experiments on the dog, using a much more complicated conditioned reflex. He found that removal of the sigmoidal cortex on both sides would affect, but not eliminate, the response. Complete removal of the hippocampus, section of the fornix, and removal of the entorhinal area did not change the conditoned reflexes. From these experiments it is easy to conclude that the hippocampus is not necessary, at least, for the primary olfactory reactions.

This, again, does not eliminate the possibility that the hippocampus serves a higher olfactory association function.

Following these findings, there have been numerous experiments made on this system. Since Papez ('37) developed his theory of emotion which consisted of the reverberating and cooperative connections of the hippocampal formation, septal area, mammillary body, and cingulate gyrus, attention has centered on this rhinencephalon as a whole. It is well known that the mammillary body is connected with the anterior thalamic nucleus, and, as we have seen above, there is a possibility that some of the fornix fibers may end in the anterior thalamic nuclei. The studies of Clark and Boggon ('33) in the cat, Waller ('34) in the rat, Walker ('36) in the monkey, Rose and Woolsey ('43, '48) in the rabbit and the cat, and Meyer, Beck, and McClardy ('47) in the cat have shown a definite topographic connection from the anterior thalamic nucleus to the cingulate gyrus. Some of this work has shown a connection in the reverse direction as well. We know, from a discussion of the anatomy above, that the cingulum, which arises in part from the cingulate gyrus, discharges to the hippocampal formation. Thus, we have a closely interrelated area. Physiologists have been interested in the similarity of findings from the entire limbic lobe. Much of their discussion deals with the limbic area, or the entire rhinencephalon, and is not limited to the hippocampus alone.

Stimulation, neuronographic and electroencephalographic studies have been carried out on the cingulate area by Bailey,

von Bonin, Davis, Garol, McCulloch, Roseman, and Silverira ('44), Ward ('47), Kremer ('47), Sloan and Jasper ('50), and Dunsmore and Lennox ('50). They report a variety of responses including somatic motor responses, supression of motor movement, regulatory action on the cortical electroencephalogram, activation and augmentation responses of the neocortex, and autonomic responses (blood pressure depression and respiratory slowing). Kaada ('51) reviewed most of the work on the cingulate area and confirmed many of these findings. He pointed out that the results of ablation of the area are to be evaluated very carefully since a variety of opposing responses can be obtained from the same area. Glees, Cole, Whitty, and Cairns ('50) reported an increase in tameness, a reduction of agressiveness, and a loss of the sense of danger in monkeys with bilateral removal of the cingulate area.

Having reviewed the physiologic findings of an area associated with the hippocampus, we come now to an evaluation of the work done on the hippocampus itself. Many of the reports on this work are parts of much wider studies on the limbic lobe in general. The two general types of experimentation (ablation and stimulation) which can be carried out on the hippocampus will now be discussed.

Partial removal of the hippocampus on either or both sides appears to have no affect on the behavior of the animals. Their reaction, as can be told by their behavior in the monkey colony, appears to be normal. Complete bilateral removal of the hippocampus, however, results in not a sleepy

but in a lethargic or apathetic animal. Other than lethargy, the animals appear normal and will feed themselves. They carry out basic functional needs. These animals are slow to anger and have only periodic episodes of increased activity.

Simpson ('52) noted in his ablations of portions of the hippocampus in the monkey that no effects were observed in the postoperative period up to the time of sacrifice of the animals. His lesions were small, as those described in the present report of experiments 4, 5, 6, 10, and 11, in which no changed responses of the animals are noted. It is evident that the lesions of the hippocampus must be large and bilateral before symptoms will arise.

In a series of reports, Klüver and Bucy (Klüver, '52; Klüver and Bucy, '38, '39; Bucy and Klüver, '40, '55) described the results of ablation experiments on the monkey. These animals had undergone bilateral temporal lobectomy, with removal of the greater part of the hippocampal formation. They demonstrated what the authors called psychic blindness, oral tendencies, hypermetamorphosis (reacting to every visual stimulus), absence of emotional reations and increased sexual activity. It can be readily seen, that in experiment 8 the monkey showed all the above symptoms except the emotional reactions. The animal was not observed for increased sexual activity. However, when bilateral hippocampal lesions are added to the removal of the temporal gyri (as in experiment 7) the absence of spontaneous activity occurred, though there was never complete absence of emotional reactions.

This animal had periods of great excitability and made angry looking motions although the direction of the attack was not well oriented. This appeared to indicate that the major part of the symptomatology of the Klüver and Bucy animals is due to the loss of the temporal lobe, mostly of the superior and middle temporal gyri. Walker, Thomson, and McQueen ('53) and Garcia-Bengochea, Corrigan, Morgane, Russell, and Heath ('51) carried out selective ablation experiments on the temporal lobe in order to determine more closely the location of the defect which caused the symptoms reported by Bucy and Klüver. Walker et al noted that lesions on the medial surface of the temporal lobe did not result in such symptoms, and Garcia-Bengochea et al noted that severing the fornix from a transfrontal approach did not produce such symptoms.

Bard and Mountcastle ('48) removed all of the neocortex in the cat, leaving the rhinencephalon. The animals developed a very placid temperament. If then, parts of the rhinencephalon, including hippocampus, were added to the lesions, the animals began to show rage reactions, and the larger the lesions in the rhinencephalon, the more prominent the rage reactions. Earlier, Bard and Rioch ('37) had noted that lesions of the rhinencephalon (with part of the neocrotex still present) resulted in rage reactions. Bard and Mountcastle postulated that the neocortex regulates a rage center, which is probably located in the hypothalamus, and that the rhinencephalon inhibits this center. With the neocortex out, the inhibition is still present. If the rhinencephalon is

destroyed, then the inhibition is removed, and there is a lower threshold to stimuli setting up rage responses and a lack of control of emotion. Rothfield and Harman ('54) confirmed these findings, and in addition, noted that complete removal of the neocortex plus bilateral section of the bodies of both fornices resulted in a lowering of the rage threshold. Spiegel, Miller, and Oppenheimer ('40) found that bilateral lesions of the hippocampus and the fornix produced rage reactions in cats. It appears then that the hippocampus, as a part of the rhinencephalon, regulates, to some extent, the emotional expression of the animal.

Cairns and Mosberg ('51) and Dott ('38) have noted that in a man with bilateral fornicotomy (as is necessary in the removal of colloid cyst of the third ventricle) no obvious defects are noted. Milner and Penfield ('55) and Scoville and Milner ('57) reported a series of patients with bilateral hippocampal lesions who had a loss of memory. The latter authors note that following the time of the lesion there was a loss of recent memory and also of retrograde and antegrade memory. The amount of loss was proportional to the amount of hippocampus gone, but the lesion must be bilateral. Nathan and Smith ('50) reported an autopsy of a man who died of a chondrosarcoma. Incidently it was found that the patient had a very degenerated hippocampus with no loss of smell. The record showed that this man was slow to anger, quiet, and had never, to the knowledge of the clinician, lost his temper.

The dissimilar results of a lesion in the hippocampus

giving an animal showing rage reactions on the one hand, and a quiet animal on the other, may not be as incompatable as might appear at first. In our animal with bilateral hippocampal lesions, the animals were quiet, lethargic, and apathetic. However, on stimulation, they gave a rage reaction, often disoriented and not well directed, but persisting for a short time. We propose then that the hippocampus exerts a control over emotional expression, the discharge mediating the control at any one moment being the result of a proper balance of impulses reaching the hippocampus and the hypothalamus. In the lesions described, this balance is upset, and the behavior of the experimental animal reflects the effects of injury not only to the hippocampus but to other brain regions as well. Hippocampal lesions alone do not eliminate cortical influence on the hypothalamus and the animals may well be lethargic, but upon stimulation have a discoordinated response. However, with the absence of both rhinencephalon and neocortex, there may be a complete release of the lower centers, the dishcarge of which results in the outward signs of emotion. Whether the hippocampus has any effect on intellectual functions can not be determined by these experiments.

We have found that stimulation of the hippocampus results in a pattern of somatic motor movements. Since these movements are eliminated when the hippocampus is separated from the subiculum, and since the pattern changes according to a definite plan with only slight movements of the elec-

trode, the resulting movements are not due to current spread from the unipolar electrode, but the result of stimulation of the area directly below the electrode.

Ferrier (1886) reported that stimulation of the hippocampus gave smacking of the lips and certain other facial movements. More recently MacLean ('55) has noted a turning of the head away from the stimulus and a sneering movement of the face when he stimulated the hippocampus. Penfield and Erickson ('41), Kaada ('51), and Penfield ('55) have denied any such movements. In the numerous other studies of the effects of stimulation of the hippocampus (many to be referred to later) no mention is made of actual somatic motor movements according to a pattern. It is possible that the parameters of stimulation were such that movements did not obtain in the experiments.

There is a definite pattern of somatic motor movement found on the hippocampus, and we suggest that the hippocampus can act as an independent second motor area. The term, "second motor area," is used in the sense as defined by Flemming and Crosby ('55). According to the pattern, the area for the face is very large, and for the upper extremity small; no area exists for the lower extremity. Such a result would be logical, if the area deals with emotional expression, since the face and upper extremity are the areas of the body most used in such expression. On raising the stimulus, a convulsive clonic type of movement is seen. Again, this may mean a coordinated mechanism for the running of the animal as in

fear or flight. There is only slight indication that autonomic (respiratory) effects are obtainable since they were not measured.

Electroencephalographic studies of stimulation of the hippocampus by Akert and Andy ('53), Green and Shimamoto ('53), Passouant, Cadilhac, and Vlahovitch ('54), and Andy and Akert ('55) show that the hippocampus has a very low threshold for seizure activity and a characteristicly long after discharge. They note that this seizure activity is spread readily to the rest of the limbic lobe, and then, with a greater latency, to the cortex as a whole. Green and Arduini ('53) have noted an electrical arousal response in the hippocampus as a result of visual, auditory, olfactory, and somatic stimulation. This arousal response is then reflected over the entire cerebral cortex. It can also be elicited by stimulation of the ascending reticular activating system of Magoun.

MacLean and associates have published a series of papers (MacLean, '49, '54, '55, '57a, '57b; MacLean, Flanigan, Flyn, Chul, and Stevens, '55) in which they have stimulated the hippocampus in waking animals (mostly cats). They have confirmed the findings reported above. They note that during the stimulation, and during the rather long latent period of the building up of the convulsive response immediately following stimulation, that, other than the limited movement of contralateral turning away, no movement occured. However, during the long afterdischarge of impulses, the animals

ceased any spontaneous movement and appeared to fix their attention on some object in the environment. On testing, these various observers found that the animal is actually in a state of subconsciousness. He may be stimulated, at which time he appears ready to fight, but the motions are purposeless and disoriented. Gastaut ('53) had also obtained these findings and has correlated this very low seizure threshold with the possibility that the hippocampus is concerned very definitely in temporal lobe epilepsy. This seizure activity takes place in the limbic system without appreciable alteration of the neocortical activity. Akert and Andy ('53) and Andy and Akert ('55) have obtained similar results. The latter state that during hippocampal discharge, a cat is indifferent to a mouse, but will attack as soon as the seizure is completed. Liberson and Akert ('55) also confirmed these results and suggested that this area may be greatly concerned in the epilepsies of disturbances of awareness and mental confusion. In this respect we must mention Hughlings Jackson's famous case Z (Jackson and Colman, 1898; Jackson and Beevor, 1890) in which a human patient could carry on neocortical activity during a seizure for which he had retrograde memory loss of activities occurring during the seizure.

Kaada, Pribram, and Epstein ('49), Green and Arduini ('53), Gastaut ('53), Kaada, Jansen, and Anderson ('53) and Kaada ('51) reported autonomic responses from stimulation of the hippocampus. These are respiratory changes, blood pressure changes (usually depressant) and some cases of pilo-

erection. One of our animals (experiment 7) after removal of the hippocampus showed a piloerection. Other autonomic responses were not measured in this report. However, it is probable that such do occur.

There are an increasing number of reports on human autopsy material from patients with temporal lobe epilepsy. In a significant number of these cases, as reported by Sano and Malamud ('53), Meyer and Beck ('55), Falconer, Denis, Meyer, Mitchell and Pond ('55), and Corsellis ('57), there is a sclerotic condition of both hippocampi. When present, it is of a characteristic nature, and seems to be associated with the severity of the epilepsy. It is, however, not present in all cases. Green, Clemente, and DeGroot ('57) have succeeded in producing an epilepsy in the cat by lesions of Ammon's horn.

It will be remembered that section of the fornix in the experiments did not eliminate or even affect the motor pattern as obtained from the hippocampus. It is evident that the discharge of the somatic motor responses is by way of the temporal lobe. There is also a close association with the tip of the temporal pole, where Youmans ('56) obtained seizures on stimulation with implanted alumina cream. There are several extrapyramidal motor pathways from the temporal lobe as reported by Youmans and also by Schneider and Crosby ('54), Crosby ('55), Mettler ('55), Whitlock and Nauta ('56), and Dejonge ('58). It is then propsed that these movements, obtained from stimulation of the hippocampus are perhaps a part

of the normal functioning of the hippocampus, mediated by way of the temporal lobe and not by way of the fornix.

We have noted that in the slight changes of stimulus there is a change in response obtained with respect to laterality. These do not disturb the basic pattern. If the cellular units for bilateral and unilateral movements are diffusely arranged within the above pattern, then bringing in more cellular units by increasing the stimulus accounts for the differences. There is no laterality to the response of the hippocampus over the posterior two thirds of this structure.

The functions of the fibers in the fornix are more obscure. We remember that there are probably afferent fibers carrying some of the sensory impulses to the hippocampus. However, the fibers in the fornix efferent with respect to the hippocampus are now more obscure as far as function is concerned. No evidence has been presented as to the exact function of these fibers.

The hippocampus, then, is an effectory structure, serving as part of an area of very high associative functions, involving autonomic and somatic impulses. Rather than considering it as a center of emotion, or even as a part of the arc for emotional expression, we would propose that it is a link in the arc used for the proper regulation of the emotional orientation of the individual to himself and to his environment. When functioning properly, the animal will make appropriate responses to external and internal stimuli, but

when it functions improperly, the animal will make inappropriate responses to stimuli, as in the disoriented rage response of the monkey in experiment 7. Strobos ('55) concludes that, "The temporal lobe is involved in orientation in self and in the environment. It regulates alertness, awareness, and state of consciousness. This helps keep the cortex awake." We suggest that this is true for an emotional sense and that the hippocampus and the limbic lobe play an important part in this function.

This being true, then the impulses playing upon the structure of the hippocampus are various, diffuse, and reach the hippocampus by various pathways. Thus the proper balance of all such impulses is necessary for function of the hippocampus. Also, there appears to be more than one discharge pathway from the hippocampus, and these, in association with other discharge pathways of the limbic lobe, must be in proper balance for normal function. Thus, when the hippocampus is removed, the balance of function is disturbed, and the result depends on the weight of the balance that is left behind. This is presented as the cause of the conflicting results of experimentation on the hippocampus.

SUMMARY

1. An investigation of the anatomy and function of the hippocampus in monkeys has been carried out by considering stimulation, ablation, and degeneration experiments.

2. The hippocampus has been shown to represent an independent second motor area.

3. The hippocampus reflects a pattern of somatic motor movement when stimulation is carried out. This pattern is not affected by fornix section, but is completely eliminated by section of the hippocampus from the subiculum.

4. The pattern as reflected from anterior to posterior on the hippocampus relates to movements from face to upper extremity in the animal.

5. Stimulation of the middle third of the hippocampus can cause a generalized arousal response.

6. Ablation of small parts of the hippocampi have no visible behavioral affect on the animal.

7. Complete ablation of both hippocampi in the same animal produces an apathetic, lethargic, and quiet animal. There is a loss of spontaneous movement with intermittent short periods of increased activity, characterized by attack reactions which are poorly oriented.

8. From a study of microscopic material prepared according to the Marchi technique, the following facts were documented.

a. Degeneration is found in the fornix as a result of hippocampal lesions and goes to the areas already mentioned in the literature, except no degeneration was found in the preoptic area, nucleus accumbens, anterior thalamic nucleus, pineal body, or postmammillary areas.

b. A generous commissural connection is present between the hippocampi.

c. There is a definite and important efferent path of the hippocampus discharging to the hippocampal gyrus and to other gyri of the temporal lobe.

d. There is a rich intrahippocampal associative connection.

9. It is proposed that the hippocampus is concerned in the overall balance of discharges associated with visceral-somatic association and in the orientation of the animal with itself and with the environment.

LITERATURE CITED

ABBIE, A. A. 1942 Cortical lamination in a polyprotodont marsupial, Perameles nasuta. J. Comp. Neur., 76: 509-536.

ADDISON, W. H. F. 1915 On the rhinencephalon of Delphinus delphis. J. Comp. Neur., 25: 497-552.

ADEY, W. R. 1953 An experimental study of the central olfactory connexions in a marsupial (Trichosurus vulpecula). Brain, 76: 311-330.

_____ 1955 An experimental study of the hippocampal connexions of the cingulate cortex in the rabbit. Brain, 74: 233-247.

ADEY, W. R. AND M. MEYER 1952a An experimental study of hippocampal pathways from prefrontal and cingulate area in the monkey. J. Anat., 86: 58-74.

_____ 1952b Hippocampal and hypothalamic connexions of the temporal lobe in the monkey. Brain, 75: 358-384.

ADRIAN, E. D. 1942 Olfactory reactions in the brain of the hedgehog. J. Physiol., 100: 459-473.

AKERT, K. AND O. J. ANDY 1953 Experimental studies on the Ammon's formation in cats and monkeys. Trans. Amer. Neur. Soc., 78th meeting: 194-197.

ALLEN, W. F. 1938 Relationship of the conditioned olfactory fore-leg response to the motor centers of the brain. Amer. J. Physiol., 121: 657-668.

_____ 1939 Effect of ablating the frontal lobe, hippocampi, and occipital-parietal-temporal (excepting pyriform areas) lobe on positive and negative olfactory conditioned reflexes. Amer. J. Physiol., 128: 754-771.

_____ 1941 Effect of ablating the pyriform-amygdaloid areas and hippocampi on positive and negative olfactory conditioned reflexes and on conditioned olfactory differentiation. Amer. J. Physiol., 132: 81-91.

_____ 1943 Distribution of cortical potentials resulting from insufflation of vapors into the nostrils and from stimulation of the olfactory bulbs and the pyriform lobe. Amer. J. Physiol., 139: 553-555.

_____ 1944 Degeneration in the dog's mammillary body and Ammon's horn following transection of the fornix. J. Comp. Neur., 80: 283-291.

_____ 1948 Fiber degeneration in Ammon's horn resulting from extirpations of the pyriform and other cortical areas and from transection of the horn at various levels. J. Comp. Neur., 88: 425-438.

ALLISON, A. C. 1953 The morphology of the olfactory system in the vertebrates. Biol. Rev., 28: 195-244.

ANDY, O. J. AND K. AKERT 1955 Seizure patterns induced by electrical stimulation of hippocampal formation in the cat. J. Neuropath. Exp. Neurol., 14: 198-213.

BAILEY, P., G. VON BONIN, E. W. DAVIS, H. W. GAROL, W. S. MCCULLOCH, E. ROSEMAN, AND A. SILVEIRA 1944 Functional organization of the medial aspect of the primate cortex.

J. Neurophysiol., 7: 51-56.

BARD, P. H. AND V. B. MOUNTCASTLE 1948 Some forebrain mechanisms involved in expression of rage with special reference to suppression of angry behavior. Res. Publ. Assc. Res. Nerv. Ment. Dis., 27: 362-404.

BARD, P. H. AND D. MCK. RIOCH 1937 A study of 4 cats deprived of neocortex and additional portions of the forebrain. Bull. Johns Hopkins Hosp., 60: 73-147.

BERRY, C. M., W. D. HAGAMEN, AND J. C. HINSEY 1952 Distribution of potentials following stimulation of olfactory bulb in cat. J. Neurophysiol., 15: 139-145.

BLACKSTAD, T. W. 1956 Commissural connections of the hippocampal regions in the rat with special reference to their mode of termination. J. Comp. Neur., 105: 417-538.

BREATHNACH, A. S. 1953 The olfactory tubercle, prepyriform cortex, and precommissural region of the porpoise (Phocaena phocaena). J. Anat., 87: 96-113.

BREATHNACH, A. S. AND F. GOLDBY 1954 The amygdaloid nuclei, hippocampus, and other parts of the rhinencephalon in the porpoise (Phocaena phocaena). J. Anat., 88: 267-291.

BROCA, P. 1878 Anatomie comaree des circonvolutions cerebrales: le grand lobe limbique et la scissure limbique dans la serie des mammiferes. Rev. Anthrop., 1: 385-498.

BRODAL, A. 1947 The hippocampus and the sense of smell.

Brain, 70: 179-224.

BUCY, P. C. AND H. KLÜVER 1940 Anatomical changes secondary to temporal lobectomy. Arch. Neurol. Psychiat., 44: 1142-1146.

_____ 1955 An anatomical investigation of the temporal lobe in the monkey. J. Comp. Neur., 103: 151-251.

CAIRNS, H., AND W. H. MOSBERG 1951 Colloid cyst of the third ventricle. Surg. Gyn. Obs., 92: 545-570.

CAMPBELL, B. AND J. SUTIN 1953 Excitability states in the hippocampal pyramidal layer. Trans. Amer. Neur. Ass., 80th meeting: 92-95.

CLARK, W. E. LEGROS 1928 On the brain of the macroscelididae (Macroscelides and Elephantulus). J. Anat., 62: 245-275.

_____ 1952 The olfactory brain or so called rhinencephalon. Med. J. Austral., 2: 755-756.

CLARK, W. E. LEGROS AND R. H. BOGGON 1933 On the connections of the anterior nucleus of the thalamus. J. Anat., 67: 215-226.

CLARK, W. E. LEGROS AND M. MEYER 1947 The terminal connections of the olfactory tract in the rabbit. Brain, 70: 304-328.

CORSELLIS, J. A. N. 1957 The incidence of Ammon's horn sclerosis. Brain, 80: 193-208.

CRAGG, B. G. AND L. H. HAMLYN 1957 Some commissural and septal connexions of the hippocampus in the rabbit. A combined histological and electrical study. J. Physiol.,

135: 460-485.

CROSBY, E. C. 1955 The role of the midbrain as a part of the discharge paths from higher centers. Proc. 1st internat. meeting neurobiologists. Progress in Neurobiology. Elsevier Pub. Co., Amsterdam.

CROSBY, E. C. AND R. T. WOODBURNE 1951 The mammalian midbrain and isthmus regions. II. The fiber connections. C. The hypothalamo-tegmental pathways. J. Comp. Neur., 94: 1-32.

DAITZ, H. M. AND T. P. S. POWELL 1954 Studies of the connexions of the fornix system. J. Neurol. Neurosurg. psychiat., 17: 75-82.

DAVENPORT, HA. A. AND R. L. SWANK 1935 Artefacts and the effects of perfusions on the Marchi technique. Stain Tech., 10: 45-52.

DEJONE, B. 1958 Personal communication.

DELL, P. AND R. OLSON 1951 Projections thalamiques, corticales et cerebelleuses des afferences viscerales vagales. C. R. Soc. Biol. Paris, 145: 1084-1088.

DOTT, N. M. 1938 Surgical aspects of the hypothalamus. Found in CLARK, W. E. LEGROS, J. BEATTIES, G. RIDDOCH, AND N. M. DOTT. The hypothalamus. Oliver and Boyd, Pub., Edinburgh.

DUNSMORE, R. H. AND M. A. LENNOX 1950 Stimulation and strychninization of supracallosal anterior cingulate gyrus. J. Neurophysiol., 13: 207-214.

ELLIOT SMITH, G. 1896 The fornix superior. J. Anat.

Physiol., 31: 80-94

FALCONER, M. A., H. DENIS, A. MEYER, W. MITCHELL, AND E. POND 1955 Treatment of temporal lobe epilepsy by temporal lobectomy. Lancet, 1: 827-835.

FERRIER, D. 1886 The functions of the brain. Smith, Elder, and Co., Pub., London.

FLEMING, J. G. R. AND E. C. CROSBY 1955 The parietal lobe as an additional motor area. J. Comp. Neur., 103: 485-512.

FOX, C. A. 1940 Certain basal telencephalic centers in the cat. J. Comp. Neur., 72: 1-62.

_____ 1943 The stria terminalis, longitudinal association bundle and precommissural fornix fibers in the cat. J. Comp. Neur., 79: 277-291.

FOX, C. A., R. R. FISHER, AND S. J. DESALVA 1948 The distribution of the anterior commissure in the monkey (Macaca mullata). J. Comp. Neur., 89: 245-278.

FOX, C. A., W. A. MCKINLEY, AND H. W. MAGOUN 1944 An oscillographic study of olfactory system of cats. J. Neurophysiol., 7: 1-16.

GARCIA-BENGOCHEA, F., R. CORRIGAN, P. MORGANE, D. RUSSELL, AND R. G. HEATH 1951 Studies on the function of the temporal lobes. I. The section of the fornix. Trans. Amer. Neur. Soc., 76th meething: 238-239.

GASTAUT, H. 1953 So-called "psychomotor" and "temporal" epilepsy. Epilepsia, 2: 59-100.

GEREBTZOFF, M. A. 1939 Sur quelques voies d'association de

l'ecorce cerebrale. J. Belge. Neurol. et Psychiat., 39: 205-221.

_____ 1942 Note anatomo-experimentale sur le fornix, la corne d'Ammon et leurs relations avec diverses structures encephaliques, notamment l'epiphyse. Act. Neuro. et Psychiatrica Belge., 42: 199-206.

GLEES, P., J. COLE, C. W. M. WHITTY, AND H. CAIRNS 1950 The effects of lesions in the cingular gyrus and adjacent areas in monkeys. Neurol. Neurosurg. Psychiat., 13: 178-190.

GLOGI, C. 1903 Istologia normale, in Opera Omnia. Ulrico Hoepli, ed. Milano.

GREEN, J. D. AND W. R. ADEY 1956 Electrophysiological studies of hippocampal connections and excitability. Electroencephalog. Clin. Neurophysiol., 8: 245-262.

GREEN, J. D. AND A. A. ARDUINI 1953 Rhinencephalic responses to afferent stimulation. 19th Internat. Physiol. Congress, Abstracts of Communications: 409-410.

_____ 1954 Hippocampal electrical activity in arousal. J. Neurophysiol., 17: 533-557.

GREEN, J. D., C. D. CLEMENTE, AND J. DEGROOT 1957 Expermentally induced epilepsy in the cat with injury of cornu Ammonis. Arch. Neur. Psychiat., 78: 259-263.

GREEN, J. D. AND X. MACHNE 1955 Unit activity of rabbit hippocampus. Amer. J. Physiol., 181: 219-224.

GREEN, J. D. AND T. SHIMAMOTO 1953 Hippocampal seizures and their propagation. Arch. Neurol. Psychiat., 70: 687-702.

GUILLERY, R. W. 1956 Degeneration in the postcommissural fornix and the mammillary peduncle of the rat. J. Anat., 90: 350-371

GURDJIAN, E. S. 1925 Olfactory connections in the albino rat, with special reference to the stria medullaris, and the anterior commissure. J. Comp. Neurol., 38: 127-164.

HINES, M. 1922 Studies in the growth and differentiation of the telencephalon in man. The fissure hippocampi. J. Comp. Neur., 34: 73-171.

HUMPHREY, T. 1936 The telencephalon of the bat. I. The non-cortical nuclear masses and certain pertinent fiber connections. J. Comp. Neur., 65: 603-711.

JACKSON, J. HUGHLINGS, AND C. E. BEEVOR 1890 Case of tumour of the right temporosphenoidal lobe bearing on the localisation of the sense of smell and on the interpretation of a particular variety of epilepsy. Brain, 12: 346-357.

JACKSON, J. HUGHLINGS, AND W. S. COLMAN 1898 Case of epilepsy with tasting movements and "dreamy state"--very small patch of softening in the left uncinate gyrus. Brain, 21: 580-590.

JESERICH, M. W. 1945 The nuclear pattern and the fiber connections of certain non-cortical areas of the telencephalon of the mink (Mustela visaon). J. Comp. Neur., 83: 173-211.

JOHNSTON, J. B. 1913 The morphology of the septum, hippo-

campus, and pallial commissures in reptiles and mammals. J. Comp. Neur., 23: 371-478.

KAADA, B. R. 1951 Somato-motor, autonomic, and electrocorticographic responses to electrical stimulation of the rhinencephalic and other structures in primates, cat, and dog. Acta Physiologica. Scand., 24: Supplementum 83, 1-285.

KAADA, B. R., J. JANSEN, AND P. ANERSON 1935 Stimulation of the hippocampus and medial cortical area in unanesthetized cats. Neurol., 3: 844-857.

KAADA, B. R., K. H. PRIBRAM, AND J. A. EPSTERIN 1949 Respiratory and vascular responses in monkeys from temporal pole, insula, orbital surface and cingulate gyrus. J. Neurophysiol., 12: 347-356.

KAAPERS, C. U. ARRIENS, G. C. HUBER, AND E. C. CROSBY 1936 The comparative anatomy of the nervous system of vertebrates including man. The MacMillan Co., New York.

KLÜVER, H. 1952 Brain mechanisms and behavior with special reference to the rhinencephalon. J. Lancet, 72: 567-574.

KLÜVER, H., AND P. C. BUCY 1938 An analysis of certain effects of bilateral temporal lobectomy in the rhesus monkey, with special reference to "psychic blindness." J. Psychol., 5: 33-54.

_____ 1939 Preliminary analysis of functions of the temporal lobes in monkeys. Arch. Neurol. Psychiat. 42: 979-1000.

KREMER, W. F. 1947 Autonomic and somatic reactions induced by stimulation of the cingular gyrus in dogs. J. Neurophysiol., 10: 371-379.

LANGWORTHY, O. R. 1932 A description of the central nervous system of the porpoise (Tursiops truncatus). J. Comp. Neur., 54: 437-499.

LEWIS, F. T. 1922 The significance of the term hippocampus. J. Comp. Neur., 35: 213-230.

LIBERSON, W. T. AND K. AKERT 1955 Hippocampal seizure states in guinea pig. Electroencephalog. Clin. Neurophysiol., 7: 211-222.

LOO, Y. T. 1931 The forebrain of the opossum, Didelphis virginiana. Part II. Histology. J. Comp. Neur., 52: 1-148.

LORENTE DE NO, R. 1933 Studies on the structure of the cerebral cortex. J. Psychol. u. Neurol., 45: 381-438.

_____ 1934 Studies of the structure of the cerebral cortex. II. Continuation of the study of the Ammonic system. J. Psychol. u. Neurol., 46: 113-177.

MACCHI, G. 1951 The ontogenetic development of the olfactory telencephalon in man. J. Comp. Neur., 95: 245-305.

MACLEAN, P. D. 1949 Psychosomatic disease and the "visceral brain." Recent developments bearing on the Papez theory of emotion. Psychosomatic Med., 11: 338-353.

_____ 1954 The limbic system and its hippocampal formation: Studies in animals and their possible application to man. J. Neurosurg., 11: 29-44.

_____ 1955 The limbic system ("visceral brain") and emotional behavior. Arch. Neurol. Psychiat., 73: 130-134.

_____ 1957a Chemical and electrical stimulation of the hippocampus in unrestrained animals. I. Methods and electroencephalographic findings. Arch. Neurol. Psychiat., 78: 113-127.

_____ 1957b Chemical and electrical stimulation of the hippocampus in unrestrained animals. II. Behavioral findings. Arch. Neurol. Psychiat., 78: 128-142.

MACLEAN, P. D., S. FLANIGAN, J. GLYNN, K. CHUL, AND J. R. STEVENS 1955 Hippocampal function: tentative correlation of conditoning, EEG, drug, and radioautographic studies. Yale J. Biol. Med., 28: 380-395.

MACLEAN, P. D., N. H. HORWITZ, AND F. ROBINSON 1952 Olfactory-like responses in pyriform area to non-olfactory stimulation. Yale J. Biol. Med., 25: 159-172.

MARBURG, O. 1944 The structure of fiber connections of the human habenula. J. Comp. Neur., 80: 211-234.

MCLARDY, T. 1955a Observations on the fornix of the monkey. I. Cell studies. J. Comp. Neur., 103: 305-325.

_____ 1955b Observations on the fornix of the monkey. II. Fiber studies. J. Comp. Neur., 103: 327-244.

METTLER, R. A. 1935 Corticofugal fiber connections of the cortex of Macaca mulatta. The temporal region. J. Comp. Neur., 64: 25-47.

MEYER, M. AND A. C. ALLISON 1949 An experimental investi-

gation of the connexions of the olfactory tracts in the monkey. J. Neurol. Neurosurg. Psychiat., 12: 274-286.

MEYER, A. AND E. BECK 1955 The hippocampal formation in temporal lobe epilepsy. Proc. Roy. Soc. Med., 48: 457-462.

MEYER, A, E. BECK, AND T. MCLARDY 1947 Prefrontal leucotomy: a neuroanatomical report. Brain, 70: 18-49.

MICHLE, W. A. AND H. W. ADES 1954 Rostral projection pathway of the vestibular system. Amer. J. Physiol., 176: 243-246.

MILNER. B. AND W. PENFIELD 1955 The effect of hippocampal lesions on recent memory. Trans. Amer. Neurol. Ass., 80th meeting: 42-48.

MORIN, F. 1950 An experimental study of hypothalamic connections in the guinea pig. J. Comp. Neur., 92: 193-214.

MORIN, F. AND J. D. GREEN 1953 Diffuse after discharges following stimulation of the fimbria hippocampi. Amer. J. Physiol., 175: 251-257.

NATHAN, P. W. AND M. C. SMITH 1950 Normal mentality associated with maldeveloped "rhinencephalon." J. Neurol. Neurosurg. Psychiat., 13: 191-197.

NAUTA, W. J. H. 1956 An experimental study of the fornix system in the rat. J. Comp. Neur., 104: 247-272.

PAPEZ, J. W. 1937 A proposed mechanism of emotion. Arch. Neurol. Psychiat., 38: 725-743.

PASSOUANT, C. G., J. CADILHAC, ET B. VLAHOVITCH 1954 Les

postdecharges par stimulation electrique de la corne D'Ammon chez L'homme. Rev. Neuro., Paris, 90: 265-274.

PATTON, H. C. 1950 Physiology of smell and taste. Ann. Rev. Physiol., 12: 469-484.

PATTON, H. D. AND V. E. AMASSIAN 1952 Cortical projection zone of chorda tympani nerve in cat. J. Neurophysiol., 15: 245-250.

PENFIELD, W. 1955 The role of the temporal cortex in certain psychical phenomenon. J. Ment. Sci., 101: 451-456.

PENFIELD, W., AND T. C. ERICKSON 1941 Epilepsy and cerebral localization: a study of the mechanism, treatment, and prevention of epileptic seizures. Charles C. Thomas, Pub., Springfield, Ill.

PETR., R., L. B. HOLDEN, AND J. JIROUT 1949 The efferent intercortical connections of the superficial cortex of the temporal lobe (Macaca mulatta). J. Neuropath. Exper. Neurol., 8: 100-103.

POWELL, T. P. S. AND W. M. COWAN 1955 An experimental study of the efferent connexions of the hippocampus. Brain, 78: 115-132.

PRIBRAM, K. H., M. A. LENNOX, AND R. H. DUNSOMORE 1950 Some connections of the orbito-fronto-temporal, limbic and hippocampal areas of the Macaca mulatta. J. Neurophysiol., 13: 127-137.

RAMÓN Y CAJAL 1901 Trabajos del laboratorio de investiga-

ciones biologicas de la Universidad de Madrid, tomo I. Parts of which are translated to english by L. M. Kraft in RAMÓN Y CAJAL 1955 Studies on the cerebral cortex, limbic structures. The Year Book Publ., Chicago, Ill.

_____ 1911 Histologie du systeme nerveus de l'homme & des vertebres. A. Maloine, Ed., Paris.

RIES, R. A. AND O. R. LANGWORTHY 1937 A study of the surface structure of the brain of the whale (Balaenoptera physalus and Physeter catodon). J. Comp. Neur., 68: 1-47

RIOCH, D. MCK., G. B. WISLOCKE, AND J. L. O'LEARY 1939 A precís of preoptic, hypothalamic, and hypophyseal terminology with atlas. Res. Pub. Ass. Res. Nerv. Ment. Dis., 20: 3-30.

ROBINSON, R., AND M. A. LENNOX 1951 Sensory mechanisms in hippocampus, cingulate gyrus and cerebellum of the cat. Red. Proc., 10: 110.

ROSE, J. E. 1939 The cell structure of the mammillary body in the mammals and in man. J. Anat., 7: 91-115.

ROSE, J. E. AND C. N. WOOLSEY 1943 A study of thalamocortical relations in the rabbit. Bull. Johns Hopkins Hosp., 73: 65-128.

_____ 1948 Structure and relations of limbic cortex and anterior thalamic nuclei in rabbit and cat. J. Comp. Neur., 89: 279-340.

ROSE, M. 1927 Die sog. Riechrinde beim Menschen und beim Affen. II. Teil des "Allocortex bei Tier und Mensch." J. für Psychol. u. Neurol., 34: 261-401.

ROSE, S. 1927 Vergleichende Messungen im Allocortex bei Tier und Mensch. J. Psychol. u. Neurol., 34: 250-260.

ROTHFIELD, L. AND P. J. HARMAN 1954 On the relation of the hippocampal-fornix system to the control of rage responses in cats. J. Comp. Neur., 101: 265-282.

SANO, K. AND N. MALAMUD 1953 Clinical significance of sclerosis of the cornu Ammonis. Ictal "psychic phenomena." Arch. Neur. Psychiat., 70: 40-53.

SCHNEIDER, R. C. AND E. C. CROSBY 1954 Stimulation of "second" motor areas in the macaque temporal lobe. Neurol., 4: 612-622.

SCOVILLE, W. B. AND B. MILNER 1957 Loss of recent memory after bilateral hippocampal lesions. J. Neurol. Neurosurg. Psychiat., 20: 11-21.

SIMPSON, E. A. 1952 The efferent fibers of the hippocampus in the monkey. J. Neurol. Neurosurg. Psychiat., 15: 79-92.

SLOAN, N. AND H. JASPER 1950 Studies of the regulatory functions of the limbic cortex. Electroencephalog. Clin. Neurophysiol., 2: 317-327.

SMITH, M. C. 1956a Observations on the extended use of the Marchi method. J. Neurol. Neurosurg. Psychiat., 19: 67-73.

_____ 1956b The recognition and prevention of artefacts of the Marchi method. J. Neurol. Neurosurg. Psychiat., 19: 74-83.

SPIEGEL, E. A., H. R. MILLER, AND M. J. OPPENHEIMER 1940

Forebrain and rage reactions. J. Neurophysiol., 3: 538-548.

SPRAGUE, J. M. AND M. MEYER 1950 An experimental study of the fornix in the rabbit. J. Anat., 84: 354-368.

STEWARD, P. M. 1939 Archinencephaly. J. Neurol. Psychiat., 2: 303-312.

STOLL, J. C., AJMONE-MARSAN, AND H. H. JASPER 1951 Electrophysiological studies of subcortical connections of anterior temporal regions in cat. J. Neurophysiol., 14: 305-316.

STROBOS, R. 1955 The temporal lobe. N. C. Med. J., 16: 563-566.

SWANK, R. L. AND H. A. DAVENPORT 1945 Chlorate-osmic-formalin method for staining degenerating myelin. Stain Tech., 10: 87-90.

SWANN, H. G. 1934 The function of the brain in olfaction. II. The results of destruction of olfactory and other nervous structures upon the discrimination of odors. J. Comp. Neur., 59: 175-201.

_____ 1935 The function of the brain in olfaction. The effects of large cortical lesions on olfactory discrimination. Amer. J. Physiol., 111: 257-262.

WALKER, A. E. 1936 An experimental study of the thalamocortical projection of the macaque monkey. J. Comp. Neur., 64: 1-40.

_____ 1937 The projection of the medial geniculate body to the cerebral cortex in the macaque monkey. J. Anat.,

71: 319-331.

WALKER, A. E., A. F. THOMSON, AND J. D. MCQUEEN 1953 Behavior and the temporal rhinencephalon in the monkey. Bull. Johns Hopkins Hosp., 93: 65-93.

WALLER, W. H. 1934 Topographical relations of cortical lesions to thalamic nuclei in the albino rat. J. Comp. Neur., 60: 237-269.

WARD, A. A. 1947 The anterior cingulate gyrus and personality. Res. Pub. Ass. Nerv. Ment. Dis., 27: 438-445.

WHITLOCK, D. G. AND W. J. H. NAUTA 1956 Subcortical projections from the temporal neocortex in Macaca mulatta. J. Comp. Neur., 106: 183-212.

YOUMANS, J. R. 1956 Experimental production of seizures in the macaque by temporal lobe lesions. Neurol., 6: 179-186.

YOUNG, M. W. 1936 The nuclear pattern and fiber connections of the non-cortical centers of the telencephalon of the rabbit (Lepus cuniculus). J. Comp. Neur., 65: 295-401.