71-15,163

GREGG, D.D.S., John Marshall, 1940-
THE CENTRAL NERVOUS SYSTEM REACTION TO
EXTRACRANIAL TRIGEMINAL NERVE LESIONS.

The University of Michigan, Ph.D., 1970
Anatomy

University Microfilms, A XEROX Company, Ann Arbor, Michigan

THIS DISSERTATION HAS BEEN MICROFILMED EXACTLY AS RECEIVED

THE CENTRAL NERVOUS SYSTEM REACTION TO EXTRACRANIAL TRIGEMINAL NERVE LESIONS

by

John Marshall Gregg

A dissertation submitted in partial fulfillment
of the requirements for the degree
of Doctor of Philosophy
(Anatomy)
in The University of Michigan
1970

Doctoral Committee:

Professor Charles L. Votaw, Chairman
Professor James K. Avery
Professor Samuel P. Hicks
Professor Russell T. Woodburne

ABSTRACT

THE CENTRAL NERVOUS SYSTEM REACTION TO EXTRACRANIAL TRIGEMINAL NERVE LESIONS

by

John Marshall Gregg

Chairman: Charles L. Votaw

The central question of whether extracranial sections of the trigeminal nerve can result in ganglion cell death and the degeneration of centrally projecting nerve processes was investigated. The experimental variables included the distance of the nerve lesion from the ganglion cell bodies, the interval of time following the nerve lesion before the effects were studied, the variable reactions of two different species and the differences between young and adult animals. A most proximal nerve section of the mandibular division was made extracranially at the foramen ovale level and a more distal nerve section was made in the inferior alveolar nerve at the mandibular foramen level. The effects of these nerve lesions were studied over a post-operative range of one-half to twenty weeks using a multiphasic light microscopic approach. The effects of peripheral lesions on the trigeminal ganglia, its nerve processes and sensory roots were studied following treatment of paraffin embedded sections with the Kluver-Barrara staining method. Brain stem tissues were observed for degenerative changes by two different techniques, the Fink-Heimer modification of the Nauta-Gygax, and the Marchi method. The Kluver-Barrara stain was also applied to the brain stem frozen sections in order to detect possible reactive changes in central tract myelin and cell bodies of trigeminal subnuclear cells.

Observation of chromatolytic patterns in the trigeminal ganglia of adult rats following extracranial nerve lesions revealed distinct somatotopic relations. The mandibular division cell bodies were localized posteriorly and laterally within the ganglia, and the cell bodies of

the inferior alveolar nerve were concentrated in the most ventral and posterior portions of the mandibular somatotopic area. Section of the mandibular division of trigeminal at foramen ovale resulted in severe ganglionic chromatolysis followed by progressive disintegration and loss of some cell bodies. Section of the inferior alveolar nerve at the mandibular foramen also resulted in necrobiosis of ganglion cells, but the response was more gradual. The largest ganglion cells appeared to react more violently to both nerve lesions. Degeneration and myelin disintegration was detected within the brain stem of young rats, adult rats and adult cats following both foramen ovale and mandibular foramen nerve sections. In the adult rat, degeneration was not observed before the third week following foramen ovale nerve section or the fourth week following mandibular foramen nerve section. Degeneration was consistently localized in the dorsal portions of the entire central trigeminal complex and the degeneration appeared to progress centrifugally from the ganglia into and down the brain stem. It was most intense in the chief sensory nucleus area and diminished progressively at more caudal levels until it reached the second cervical level of the spinal cord. Compared to the adult rat, the ganglia of the cats appeared to be more resistant to extracranial nerve sections. The preponderence of chief sensory degeneration over the degeneration at more caudal levels was greater in the cat than in the rat. Degeneration in the young rats appeared to be more rapid and more absolute than in the adults. The young ganglia were grossly deficient of neurons and brain stem degeneration was prominent at a shorter interval following both of the peripheral nerve lesions.

It was concluded that extracranial nerve sections of the trigeminal nerve in the rat and cat can result in the necrobiosis of ganglion cells and the consequent degeneration of their central brain stem processes. These observations may provide a key to the etiology of trigeminal sensory neuropathies and may help to establish guidelines for surgery involving the trigeminal system.

ACKNOWLEDGMENTS

I wish to express my gratitude to the many people at the University of Michigan who helped make the execution and completion of graduate studies and this dissertation possible:

To Dr. Charles L. Votaw, committee chairman, for directing the research, interpretation and publication of this dissertation,

To Dr. James K. Avery, committee member, for encouraging the basic training toward this degree,

To Drs. Samuel P. Hicks and Russell T. Woodburne, committee members, for their meaningful criticism and discussion throughout the preparation of this thesis, and to Dr. Edward W. Lauer, for participating in the doctoral defense proceedings,

To Dr. James R. Hayward, for providing sustained encouragement for the completion of these graduate studies,

To Miss Constance D'Amato, Mr. Gary Bilyk, Mr. William Brudon, Mrs. Iris Templin, and Mrs. Joanne Wilson, for their assistance in conducting the research and in preparing this manuscript,

To my wife, Gail, who has been with me through all of this education.

This research has been supported in part by a grant of the Public Health Service from the National Institutes of Health, #5T01 DE 00013-13.

TABLE OF CONTENTS

Page

ACKNOWLEDGEMENTS ii

LIST OF TABLES v

LIST OF ILLUSTRATIONS vi

INTRODUCTION 1

MATERIALS AND METHODS 3

Experimental Design 3

Surgical Procedures 3

Histologic Procedures 8

Analytic Procedures 9

OBSERVATIONS 15

Somatotopic Morphology of the Adult Rat Trigeminal Ganglion 15

Adult Rat Reaction 22

Trigeminal ganglion reaction following foramen ovale nerve section in the adult rat 22

Trigeminal ganglion reaction following mandibular foramen nerve section in the adult rat 34

Brain stem reaction following foramen ovale nerve section in the adult rat 41

Brain stem reaction following mandibular foramen nerve section in the adult rat 58

Adult Cat Reaction 65

Trigeminal ganglion reaction following foramen ovale nerve section in the adult cat 65

Trigeminal ganglion reaction following mandibular foramen nerve section in the adult cat 66

Brain stem reaction following foramen ovale nerve section in the adult cat 66

Brain stem reaction following mandibular foramen nerve section in the adult cat 79

Page

Young Rat Reaction 79

Trigeminal ganglion reaction following foramen ovale nerve section in the young rat 79

Trigeminal ganglion reaction following mandibular foramen nerve section in the young rat 79

Brain stem reaction following foramen ovale nerve section in the young rat 79

Brain stem reaction following mandibular foramen nerve section in the young rat 84

Summary of Observations 84

DISCUSSION 103

Historical Perspectives 103

Retrograde Necrobiosis 105

The Cell Type Variable 107

The Age Variable 110

The Species Variable 111

Somatotopic Patterns of the Trigeminal Complex 112

Physiologic Considerations 115

Clinical Considerations 118

CONCLUSIONS 121

BIBLIOGRAPHY 123

LIST OF TABLES

Table Page

1. EXPERIMENTAL DESIGN FOR EXTRACRANIAL TRIGEMINAL NERVE SECTION 4

LIST OF ILLUSTRATIONS

Figure		Page
1.	SURGICAL TECHNIQUE FOR EXTRACRANIAL TRIGEMINAL NERVE SECTION	7
2.	HISTOLOGIC TECHNIQUE APPLIED TO THE TRIGEMINAL GANGLION AND ITS PROCESSES	11
3.	HISTOLOGIC TECHNIQUE APPLIED TO THE BRAIN STEM AND SPINAL CORD	13
4.	GROSS DIMENSIONS OF THE TRIGEMINAL GANGLION OF THE ADULT RAT	17
5.	SOMATOTOPIC PATTERNS IN THE TRIGEMINAL GANGLION OF THE ADULT RAT DETERMINED FOLLOWING MANDIBULAR DIVISION NERVE SECTION AT FORAMEN OVALE	19
6.	SOMATOTOPIC PATTERNS IN THE TRIGEMINAL GANGLION OF THE ADULT RAT DETERMINED FOLLOWING INFERIOR ALVEOLAR NERVE SECTION AT MANDIBULAR FORAMEN	21
7.	TRIGEMINAL GANGLION OF THE ADULT RAT ONE WEEK FOLLOWING FORAMEN OVALE NERVE SECTION	25
8.	TRIGEMINAL GANGLION OF THE ADULT RAT ONE WEEK FOLLOWING FORAMEN OVALE NERVE SECTION	27
9.	TRIGEMINAL GANGLION OF THE ADULT RAT ONE WEEK FOLLOWING FORAMEN OVALE NERVE SECTION	29
10.	TRIGEMINAL GANGLION OF THE ADULT RAT ONE AND ONE-HALF WEEKS FOLLOWING FORAMEN OVALE NERVE SECTION	31
11.	TRIGEMINAL GANGLION OF THE ADULT RAT TWO WEEKS FOLLOWING FORAMEN OVALE NERVE SECTION	33
12.	TRIGEMINAL GANGLION OF THE ADULT RAT ONE WEEK FOLLOWING MANDIBULAR FORAMEN NERVE SECTION	36
13.	TRIGEMINAL GANGLION OF THE ADULT RAT SIX WEEKS FOLLOWING MANDIBULAR FORAMEN NERVE SECTION	38

Figure		Page
14.	TRIGEMINAL GANGLION OF THE ADULT RAT TWENTY WEEKS FOLLOWING MANDIBULAR FORAMEN NERVE SECTION	40
15.	CHIEF SENSORY NUCLEUS AREA OF THE ADULT RAT THREE WEEKS FOLLOWING FORAMEN OVALE NERVE SECTION	43
16.	SUBNUCLEUS CAUDALIS AREA OF THE ADULT RAT THREE WEEKS FOLLOWING FORAMEN OVALE NERVE SECTION	45
17.	CHIEF SENSORY NUCLEUS AREA OF THE ADULT RAT SIX WEEKS FOLLOWING FORAMEN OVALE NERVE SECTION	47
18.	CHIEF SENSORY NUCLEUS AREA OF THE ADULT RAT SIX WEEKS FOLLOWING FORAMEN OVALE NERVE SECTION	49
19.	ROSTRAL PORTION OF THE DESCENDING TRACT OF TRIGEMINAL IN THE ADULT RAT TEN WEEKS FOLLOWING FORAMEN OVALE NERVE SECTION	51
20.	LOW MEDULLA LEVEL OF THE ADULT RAT THREE WEEKS FOLLOWING FORAMEN OVALE NERVE SECTION	53
21.	LOW MEDULLA LEVEL OF THE ADULT RAT THREE WEEKS FOLLOWING FORAMEN OVALE NERVE SECTION	55
22.	HYPOGLOSSAL NUCLEUS LEVEL OF ADULT RAT THREE WEEKS FOLLOWING FORAMEN OVALE NERVE SECTION	57
23.	CHIEF SENSORY NUCLEUS AREA OF THE ADULT RAT SIX WEEKS FOLLOWING MANDIBULAR FORAMEN NERVE SECTION	60
24.	LOW MEDULLA LEVEL OF THE ADULT RAT TWENTY WEEKS FOLLOWING MANDIBULAR FORAMEN NERVE SECTION	62
25.	LOW MEDULLA LEVEL OF THE ADULT RAT TWENTY WEEKS FOLLOWING MANDIBULAR FORAMEN NERVE SECTION	64
26.	TRIGEMINAL GANGLION OF THE ADULT CAT SIX WEEKS FOLLOWING FORAMEN OVALE NERVE SECTION	68

Figure		Page
27.	TRIGEMINAL GANGLION OF THE ADULT CAT TEN WEEKS FOLLOWING FORAMEN OVALE NERVE SECTION	70
28.	TRIGEMINAL GANGLION OF THE ADULT CAT TWENTY WEEKS FOLLOWING MANDIBULAR FORAMEN NERVE SECTION	72
29.	TRIGEMINAL GANGLION OF THE ADULT CAT TWENTY WEEKS FOLLOWING MANDIBULAR FORAMEN NERVE SECTION	74
30.	SENSORY ROOT OF TRIGEMINAL ENTERING THE BASALAR PONS IN THE ADULT CAT TWENTY WEEKS FOLLOWING MANDIBULAR FORAMEN NERVE SECTION	76
31.	ROSTRAL PORTION OF THE DESCENDING TRACT OF TRIGEMINAL IN THE ADULT CAT TWENTY WEEKS FOLLOWING MANDIBULAR FORAMEN NERVE SECTION	78
32.	TRIGEMINAL GANGLION OF THE YOUNG RAT TWO WEEKS FOLLOWING FORAMEN OVALE NERVE SECTION	81
33.	TRIGEMINAL GANGLION OF THE YOUNG RAT TWO WEEKS FOLLOWING MANDIBULAR FORAMEN NERVE SECTION	83
34.	PLANE OF SECTION AND ORIENTATION FOR ATLASES OF BRAIN STEM DEGENERATION IN THE ADULT RAT	88
35.	NAUTA DEGENERATION PATTERNS IN THE ADULT RAT THREE WEEKS FOLLOWING FORAMEN OVALE NERVE SECTION	90
36.	NAUTA DEGENERATION PATTERNS IN THE ADULT RAT SIX WEEKS FOLLOWING FORAMEN OVALE NERVE SECTION	92
37.	NAUTA DEGENERATION PATTERNS IN THE ADULT RAT FOUR WEEKS FOLLOWING MANDIBULAR FORAMEN NERVE SECTION	94
38.	NAUTA DEGENERATION PATTERNS IN THE ADULT RAT SIX WEEKS FOLLOWING MANDIBULAR FORAMEN NERVE SECTION	96
39.	MARCHI DEGENERATION PATTERNS IN THE ADULT RAT TEN WEEKS FOLLOWING FORAMEN OVALE NERVE SECTION	98

Figure Page

40. MARCHI DEGENERATION PATTERNS IN THE ADULT RAT TEN WEEKS FOLLOWING MANDIBULAR FORAMEN NERVE SECTION 100

41. MARCHI DEGENERATION PATTERNS IN THE ADULT RAT TWENTY WEEKS FOLLOWING MANDIBULAR FORAMEN NERVE SECTION 102

INTRODUCTION

Biologic scientists and clinicians alike have been impressed by the capacity of the sensory nerve to resist the effects of peripheral trauma and to reconstitute grossly functional nerve processes. This capacity has been especially relevant to the trigeminal nerve which innervates a body area which is subjected to the highest incidence of trauma from both accidental and iatrogenic sources. In a disturbing number of cases trigeminal sensory neuropathy has been linked to a patient history of trauma (White, J. C. and Sweet, W. H., '55, and Goldstein, N., *et al.*,'63). The etiology of post-traumatic sensory neuropathies has typically been explained on the basis of peripheral regenerative accidents such as neuroma formation (Huber and Lewis, '20), differences in remyelination patterns (Visoso and Young, '48), and failure in receptor regeneration or excessive scar formation (Huber, '27). An alternate etiology, and the central hypothesis to be examined in the present series of experiments, states that peripheral nerve trauma may result in the necrobiosis of certain ganglion cell bodies. A degeneration of central nerve processes would inevitably follow the death of ganglion cells. The elimination of functional central connections in this manner may provide a reasonable morphologic basis for explaining some forms of post-traumatic sensory dysfunction.

Bielschowsky ('32) had stated that the chromatolytic response of sensory cell bodies to peripheral trauma might include the extreme reaction of cell death. The early investigations of this problem emphasized a wide variety of factors which could determine whether the ganglion cell would react by undergoing necrobiosis. Cajal ('28) stressed the importance of the distance of the point of lesion from the cell body. Other authors emphasized the importance of the type of injury (Bielschowsky '32), the functional cell type injured (Cammermeyer, '63), and the species, the age, and the time interval between nerve lesion and examination of the effects (Geist, '33).

Perhaps because of the number of experimental variables involved in this problem, progress has been slow in the field of sensory system neuropathology. Interest has been

renewed, however, because of the need to provide morphologic support for recently evolved concepts of somatosensory physiology (Melzack and Wall, '65). Another recent technical advantage has been provided by the refinement of techniques for detecting subtle nervous system degeneration (Nauta and Gygax, '54). Torvik ('56) used the Nauta technique in the rat to describe the afferent connections of major sensory cranial nerves. He made intracranial nerve avulsions distal to the trigeminal, geniculate, glossopharyngeal and vagal ganglia and demonstrated extensive degeneration within the brain stems. However, no previous study has demonstrated both sensory ganglion cell disintegration and central process degeneration following simple extracranial nerve sections.

Therefore, it is the purpose of this study to determine whether an extracranial section of the trigeminal nerve can result in ganglion cell death. Proof of death would be based on the demonstration of nuclear disintegration within the ganglion as well as degenerative changes within the brain stem axon processes. Attention would be given to the post-operative timing of the appearance of this degeneration and to its somatotopic distribution within the known anatomic and functional subdivisions of the central trigeminal complex. The primary experimental variable would be the distance of the lesion from the cell body. Secondary investigations would be made of the influences of age and species on the reaction to nerve section.

MATERIALS AND METHODS

Experimental Design

Three experimental animal groups were used to study the appearance of central degeneration and necrosis in response to extracranial nerve sections (Table 1). Group A was designed to test the primary variable of distance of the nerve section from the cell body. In ten adult albino rats weighing at least 300 milligrams the mandibular division of trigeminal was sectioned at foramen ovale, the point of exit of the third division of trigeminal from the cranium. This "proximal" nerve section group of rats was compared to a second group of ten adult rats in which a "distal" nerve section was made of the inferior alveolar nerve just after its entry into the mandibular foramen (Figure 1). In all cases the right side was used for operation and the left side was used as a control. In order to observe the effects of these nerve sections over a broad range of time, the two surgical groups of animals were maintained post-operatively for one-half to twenty weeks before they were sacrificed (Table 1).

Group B was introduced to study the possible species differences under surgical conditions comparable to those of Group A. A total of eleven adult cats, weighing between 3.7 and 4.1 kilograms, were subjected to the proximal and distal nerve sections. Post-operative periods in this series ranged from one to twenty weeks (Table 1).

Group C was designed to compare the response of young rats under the same surgical conditions applied to the animals of Group A and B. Six white albino rats, twenty-five days of age were divided into two equal groups and subjected to the proximal and distal nerve section operations. Post-operative durations ranged from two to six weeks (Table 1).

Surgical Procedures

Baseline general anesthesia was established for all experimental animals with intraperitoneal sodium pentobarbital at a dosage of twenty-five milligrams per kilogram body

TABLE 1

EXPERIMENTAL DESIGN FOR
EXTRACRANIAL TRIGEMINAL NERVE SECTION

EXPERIMENTAL ANIMAL	OPERATION	POST-OPERATIVE DURATION
GROUP A:		
ADULT RATS (10)	FORAMEN OVALE	1/2, 1, 1-1/2, 2, 3, 4, 6, 8, 10, 20 WEEKS
ADULT RATS (10)	FORAMEN MANDIBULARE	1/2, 1, 1-1/2, 2, 3, 4, 6, 8, 10, 20 WEEKS
GROUP B:		
ADULT CATS (9)	FORAMEN OVALE	1, 1-1/2, 2, 3, 4, 6, 8, 10, 20 WEEKS
ADULT CATS (2)	FORAMEN MANDIBULARE	4, 20 WEEKS
GROUP C:		
YOUNG RATS (3)	FORAMEN OVALE	2, 4, 6 WEEKS
YOUNG RATS (3)	FORAMEN MANDIBULARE	2, 4, 6 WEEKS

weight for rats and thirty-five milligrams per kilogram body weight for cats. Surgical planes of anesthesia were maintained in rats with ether vapor inhalation. The surgical plane of anesthesia was maintained in cats by titrated additions of an ultra-short acting barbiturate, sodium methohexital, administered through an in-dwelling cephalic vein catheter.

The surgical sites were prepared by shaving, scrubbing with a hexachlorophene soap, and by applying 0.5 percent iodine antiseptic. The surgeons scrubbed, gowned and gloved; the animals were then draped for a surgically clean procedure. All operations were carried out on the right side of the animal with the contralateral side planned for use as a control.

Two surgical approaches were developed for sectioning the third division of trigeminal extracranially at reproducible "proximal" and "distal" locations (Figure 1). In the proximal or foramen ovale procedure a vertical three centimeter skin incision was made in the preauricular region anterior to the superficial temporal artery and extending superiorly over the zygomatic arch. The parotid gland and associated facial nerve branches were carefully retracted inferiorly. The posterior portion of the masseteric muscle was sectioned free from its attachment to the zygomatic arch and the posterior part of the arch was removed with a rongeur. The temporomandibular joint and mandibular condyle were then exposed through a vertical incision through the joint capsule and by reflecting the stylomandibular sling attachments posteriorly. The condyle and meniscus were then removed by dividing the condylar neck and then dissecting free the medial capsular and lateral pterygoid insertions. The proximal maxillary artery was visualized and stabilized with a loosely tied suture. The auriculotemporal nerve was found in the temporal fossa and was used as a guide to the location of foramen ovale. The lateral pterygoid muscle was retracted anteromedially and the middle meningeal artery was dissected free of mandibular nerve fibers. No attempt was made to distinguish motor nerve branches of the trigeminal, and all mandibular branches were sectioned cleanly with a number eleven blade at the level of nerve exit from foramen ovale. A loose resorbable gelatin sponge was placed in the dead space created by the condylectomy and the wound was closed in layers without drains. No attempt was made to reapproximate, divert, or cap the cut nerve ends; they were allowed to retract freely.

FIGURE 1

SURGICAL TECHNIQUE FOR EXTRACRANIAL TRIGEMINAL NERVE SECTION

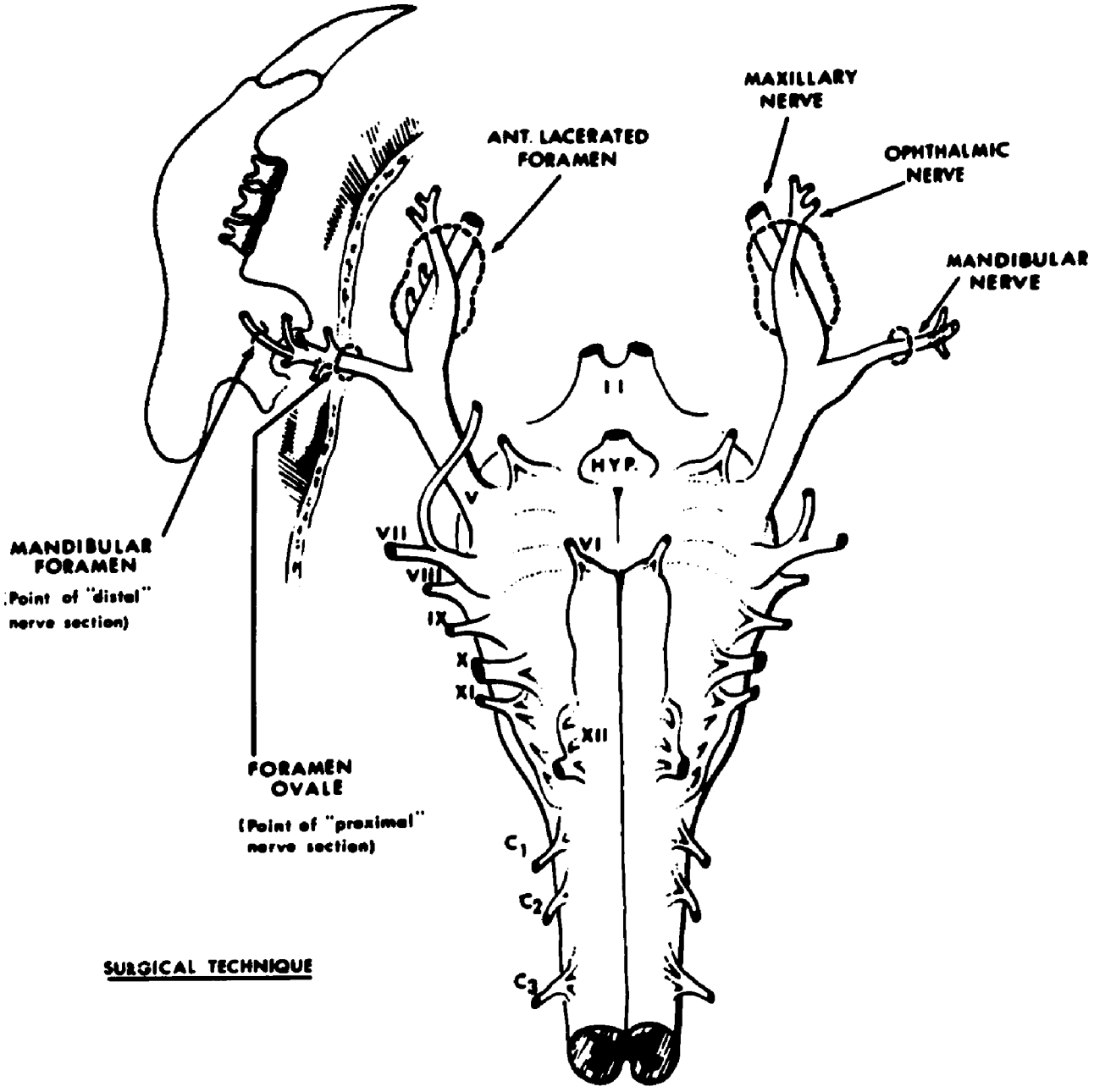

SURGICAL TECHNIQUE

VENTRAL VIEW
RAT BRAIN-STEM

1

The approach to the more distal or "foramen mandibularis" nerve section was begun by a two centimeter skin incision along the inferior border of the mandible in the middle one-third of the body. After sharp dissection was carried to bone at the inferior border the masseteric muscle was dissected completely free from its anterior mandibular attachments. The inferior alveolar neurovascular bundle could then be visualized grossly through the lateral mandibular cortex as it lay in the anterior portion of the ascending ramus. The lateral cortex of the canal was removed with a large rotating bone burr and the inferior alveolar nerve was cleanly divided at a point just distal to its entry at mandibular foramen. The wound was then closed in layers.

All animals were observed post-operatively for infection and gross neurologic deficit. Prophylactic broad spectrum and penicillin antibiotics were administered for one week post-operatively and the animals were maintained on normal laboratory chow with supplemental multivitamins.

Histologic Procedures

According to the sacrifice schedule the animals were anesthetized with sodium pentobarbital and an open thoracotomy was performed. Intracardiac perfusion was begun with isotonic saline using approximately 200 milliliters for cats and 50 milliliters for rats. Perfusion was completed with approximately 700 milliliters of 10 percent formalin for the cats and 300 milliliters of 10 percent formalin for the rats. The animals were then decapitated, and cranial vaults and dorsal spinal columns were removed. The remaining cranial tissues with exposed brain and spinal cords were immersed in 10 percent formalin for seven days. At the end of this fixation time the brain stems were separated from the forebrain by a transverse cut at the intercollicular level. The trigeminal roots were then exposed bilaterally and were divided transversely at their points of entrance into the pons. The brain stems and spinal cords were then dissected from their bony crypts. The remaining trigeminal roots and ganglia were bilaterally freed from the middle cranial fossae and their attached peripheral nerves were dissected peripherally as far as possible. Observations were made at this time on the operative sites in order to assess the gross effects of trigeminal nerve section and subsequent repair and regeneration activities.

All trigeminal root, ganglia and nerve tissues including operated and control tissues were prepared similarly for analysis of the reaction to nerve section (Figure 2). Tissues were dehydrated, infiltrated and embedded in paraffin. Sections were cut at 15 micra transverse to the mandibular nerve and the mandibular portion of the trigeminal ganglion. These tissues were then stained by the method of Kluver and Barrara ('53) which incorporates a Nissl stain, cresyl echt violet, and the Luxol fast blue technique for staining myelin.

The brain stem tissues were prepared for study by two nerve degeneration techniques; the Fink-Heimer ('67) modification of the Nauta-Gygax technique ('54), and the Marchi method (Figure 3). Tissues of animals that had been sacrificed less than ten weeks post-operatively were cut into transverse slices approximately five millimeters thick with a large, thin blade. These thick sections were then immersed in a 30 percent sucrose solution for two to three days. The tissues were then placed on a dry ice platform and sectioned transversely at 30 micra from the level of the superior colliculus to the cervical five cord level with a sliding microtome. Frozen sections from representative levels of the brain stem were then processed through the Fink-Heimer procedure. Similar representative sections not used in the Fink-Heimer procedure were mounted and stained with the Kluver-Barrara stain.

Brain stems of animals that had been sacrificed at greater than eight weeks post-operative duration were stained according to the Marchi osmium tetroxide technique. These tissues were then infiltrated, embedded in paraffin, and sectioned at 30 micra in the transverse plane (Figure 3).

Analytic Procedures

The normal architecture of the trigeminal ganglion in the adult rat was determined by examining the normal control specimens and the chromatolytic patterns in the ganglia of rats following foramen ovale and mandibular foramen nerve sections. Particular attention was paid to the localization of the mandibular division cell bodies and the distribution of the inferior alveolar nerve cell bodies within this division. The ganglia were observed throughout all experimental groups for evidence of progressive cell body disintegration and death. The particular criteria used included observation of Nissl substance dissolution and dispersion to the cell periphery, pyknosis, cell body fragmentation, and phagocytosis.

FIGURE 2

HISTOLOGIC TECHNIQUE APPLIED TO THE TRIGEMINAL GANGLION AND ITS PROCESSES

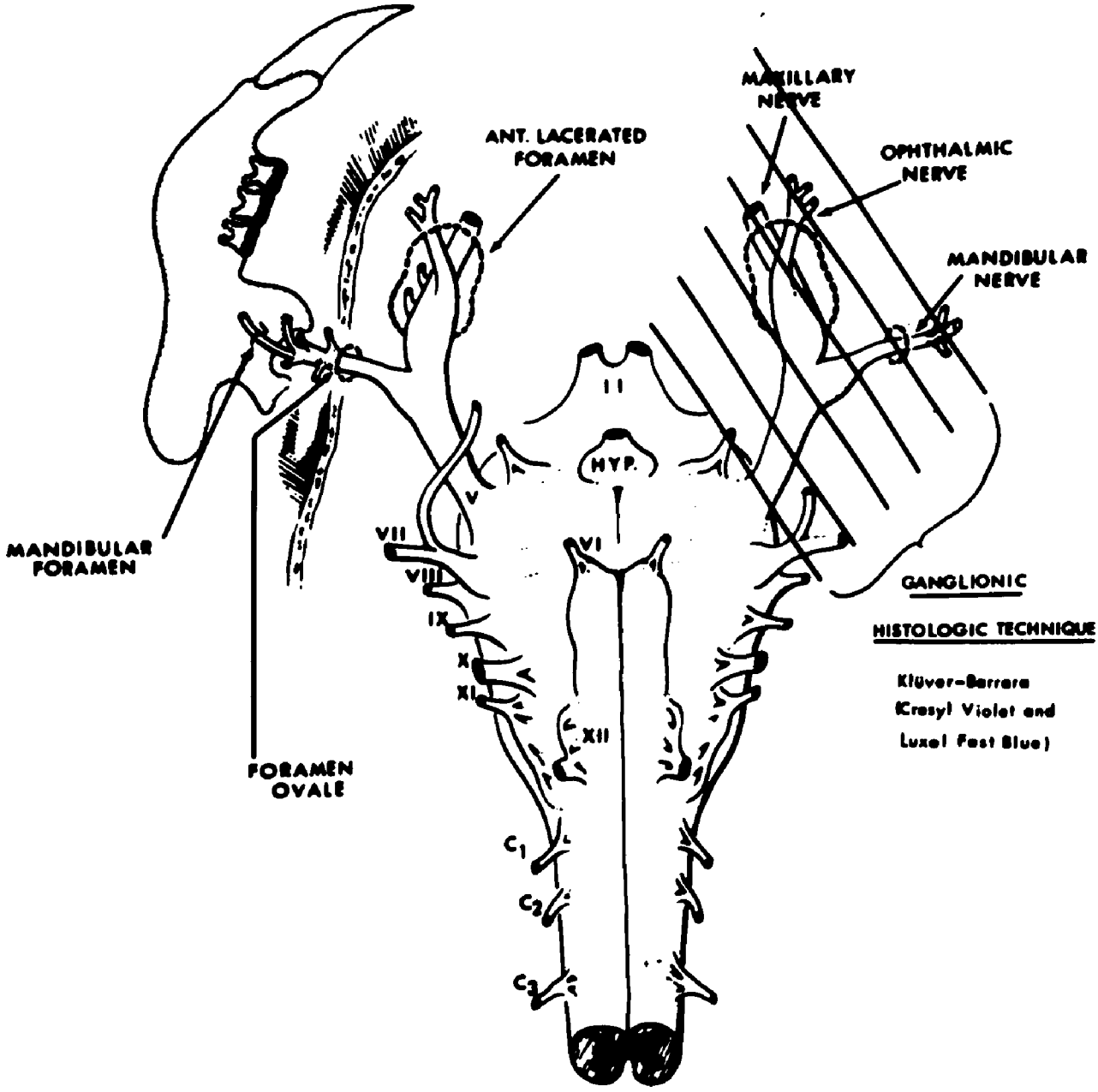

VENTRAL VIEW
RAT BRAIN-STEM

2

FIGURE 3

HISTOLOGIC TECHNIQUE APPLIED TO THE BRAIN STEM AND SPINAL CORD

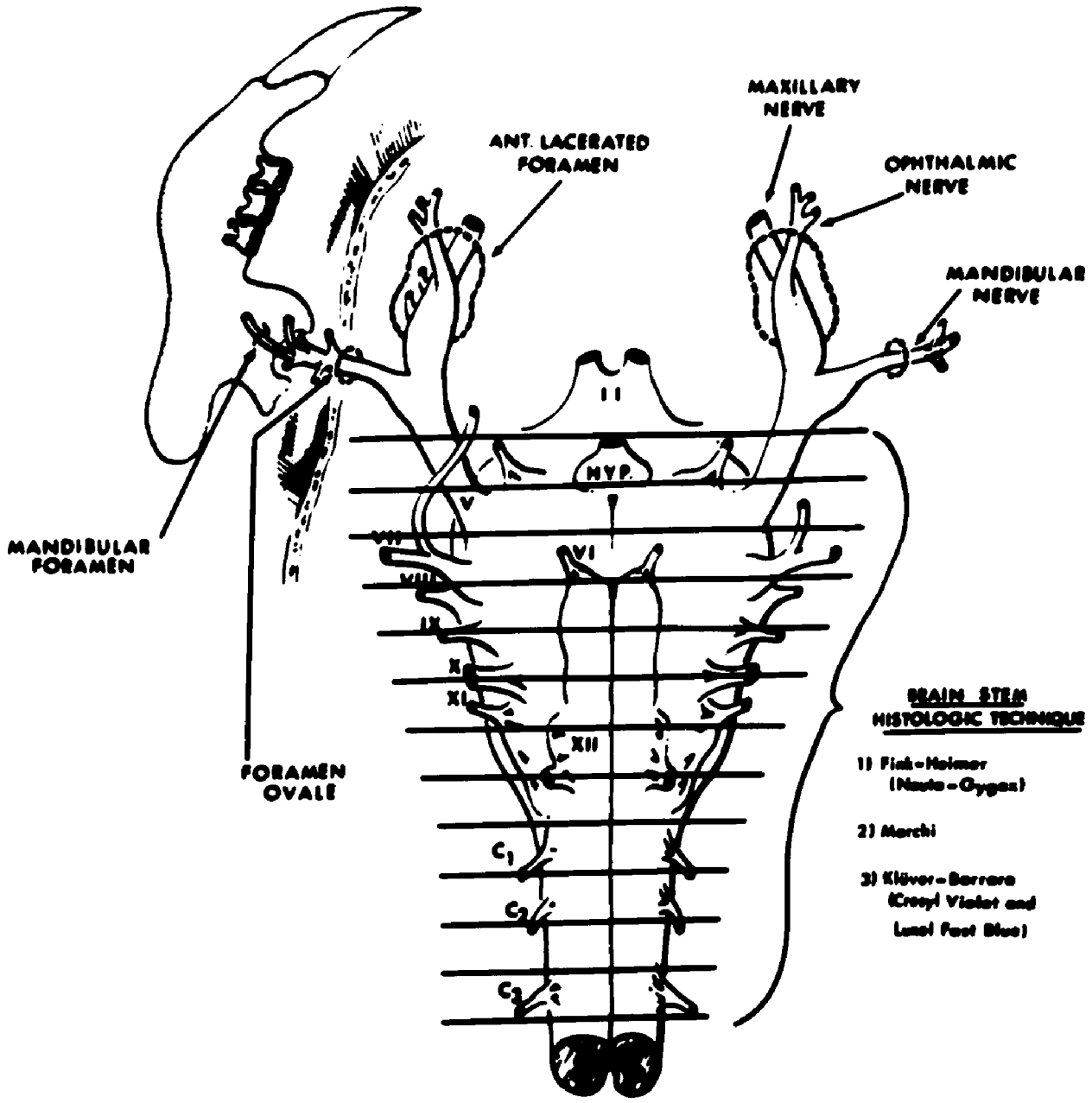

VENTRAL VIEW
RAT BRAIN-STEM

3

Additional indirect evidence of cell loss was considered such as the appearance of vacant cell "ghosts", glial scars and an observable reduction in cell density. The trigeminal roots and nerve processes were also observed for evidence of demyelination and proliferation of Schwann cells as well as neuroma formation. Tissues were also observed for the presence of more generalized pathology such as meningeal granulocytosis, lymphocytosis, organizing hematoma, or foreign body reaction.

Brain stem Fink-Heimer and Marchi method sections were analyzed for the actual presence of degeneration granules and for their somatotopic localization within tract and nuclear areas of the brain stem. Those brain stem tissues stained by the Kluver-Barrara method were observed for evidence of myelin dissolution within the chief sensory and descending tract of trigeminal areas. These tissues were also studied for evidence of transneuronal degeneration. The reactive changes of the motor and mesencephalic nuclei of the trigeminal complex were not studied.

Observations were made using a Leitz light microscope and representative fields were photographed with a Zeiss 35 millimeter photomicroscopic apparatus.

OBSERVATIONS

Somatotopic Morphology of the Adult Rat

Trigeminal Ganglion

The trigeminal ganglion of the adult rat lies in the floor of the middle cranial fossa invested by a tough reflection of dural meninges. The root and ganglion are bounded medially by the basisphenoid and the cavernous sinus, and are bounded posteriorly by the petrous portion of the temporal bone which sends a bony shelf to partially over-ride the mandibular portion of the trigeminal ganglion. The root and ganglion are covered superiorly by the temporal lobe of cerebral cortex and more posteriorly by the cerebellar hemisphere and the bony tentorium cerebelli. The trigeminal root diverges from the posteriorlateral basilar pons and is directed anteriorly parallel to the long axis of the brain stem. The ganglion itself is not semilunar but rather fusiform in outline form. The ophthalmic and maxillary divisions extend anteriorly to exit together from the lacerated foramen with the ophthalmic branch located superior and medial to the larger maxillary division at their point of exit from the cranial cavity. The mandibular nerve, intermediate in size between the ophthalmic and maxillary nerves, diverges from the ventral and posterior portions of the ganglion and courses laterally to exit through foramen ovale.

Gross measurements of the adult rat specimens by vernier caliper revealed that the average length of the trigeminal root, ganglion and nerves from the pons surface to anterior lacerated foramen is 10.5 to 11.5 millimeters (Figure 4). The average length from pons surface to the point of mandibular nerve exit from foramen ovale was found to be 6.5 to 7.5 millimeters. The approximate distance between foramen ovale and the mandibular foramen was 2.5 to 3.5 millimeters. Calculations based on serial cross sections of normal control of trigeminal ganglia revealed that the most peripherally located cell bodies of the mandibular division were approximately 3.2 to 4.1 millimeters from the point of mandibular nerve exit at foramen ovale. Therefore, these measurements reveal that the proximal

FIGURE 4

GROSS DIMENSIONS OF THE TRIGEMINAL GANGLION OF THE ADULT RAT

GROSS DIMENSIONS OF RAT TRIGEMINAL GANGLION

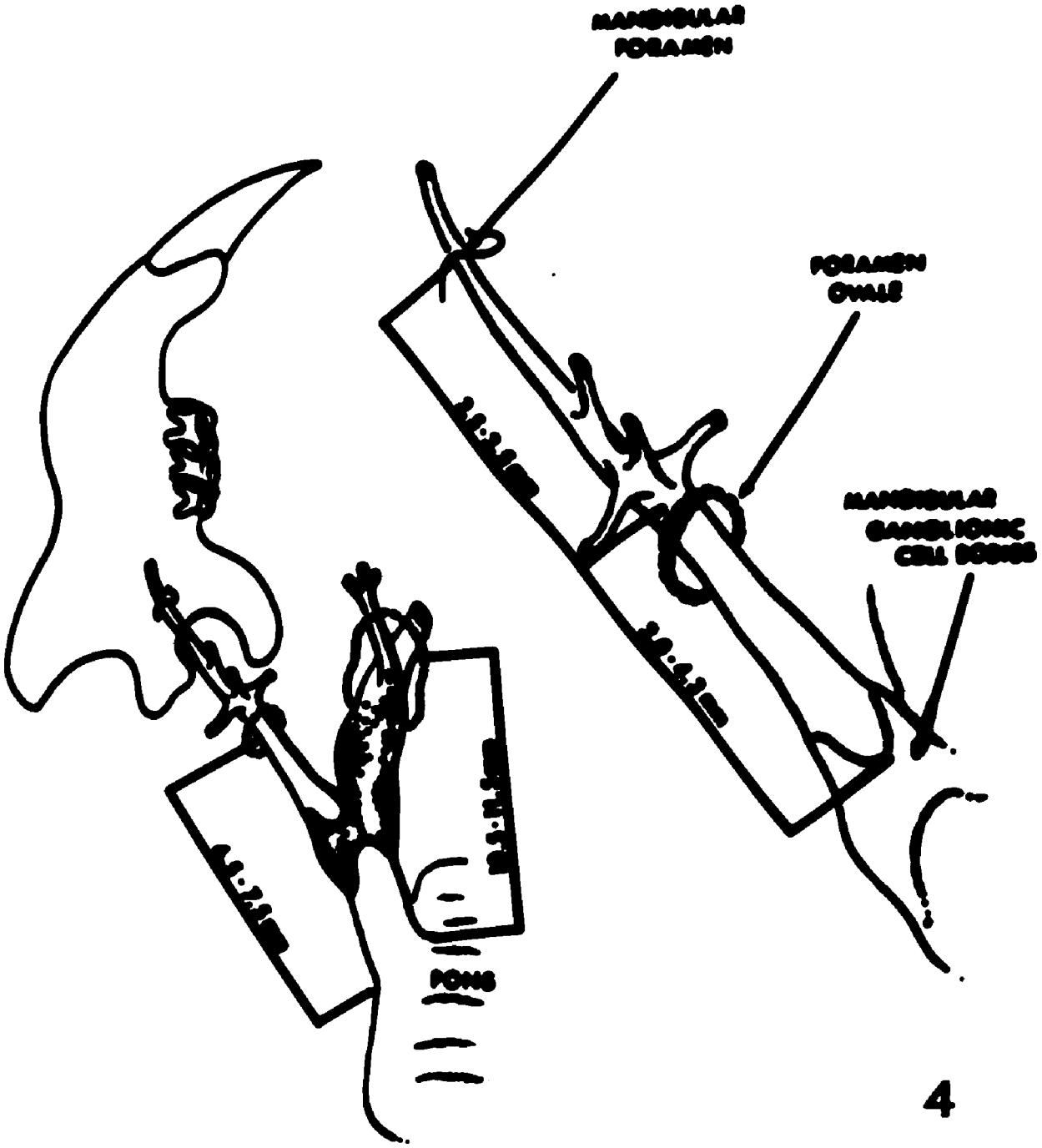

4

FIGURE 5

SOMATOTOPIC PATTERNS IN THE TRIGEMINAL GANGLION OF THE ADULT RAT DETERMINED FOLLOWING MANDIBULAR DIVISION NERVE SECTION AT FORAMEN OVALE

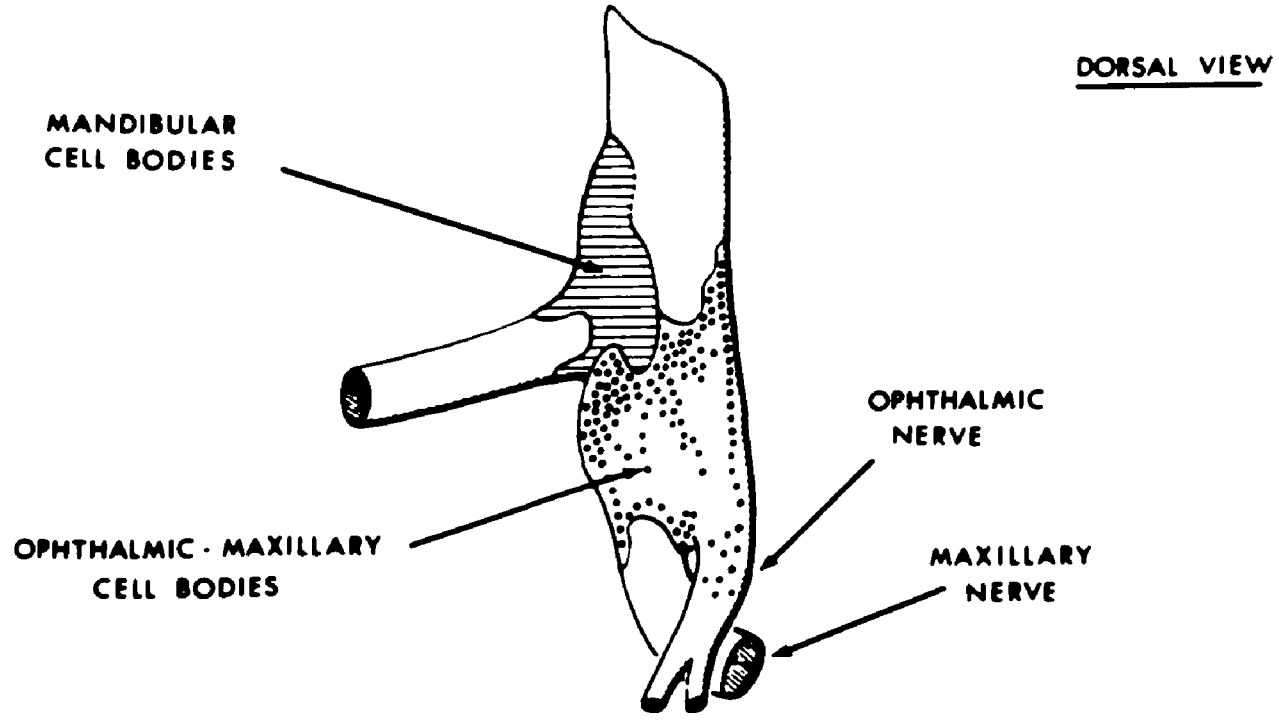
DORSAL VIEW
MANDIBULAR CELL BODIES
OPHTHALMIC NERVE
OPHTHALMIC - MAXILLARY CELL BODIES
MAXILLARY NERVE

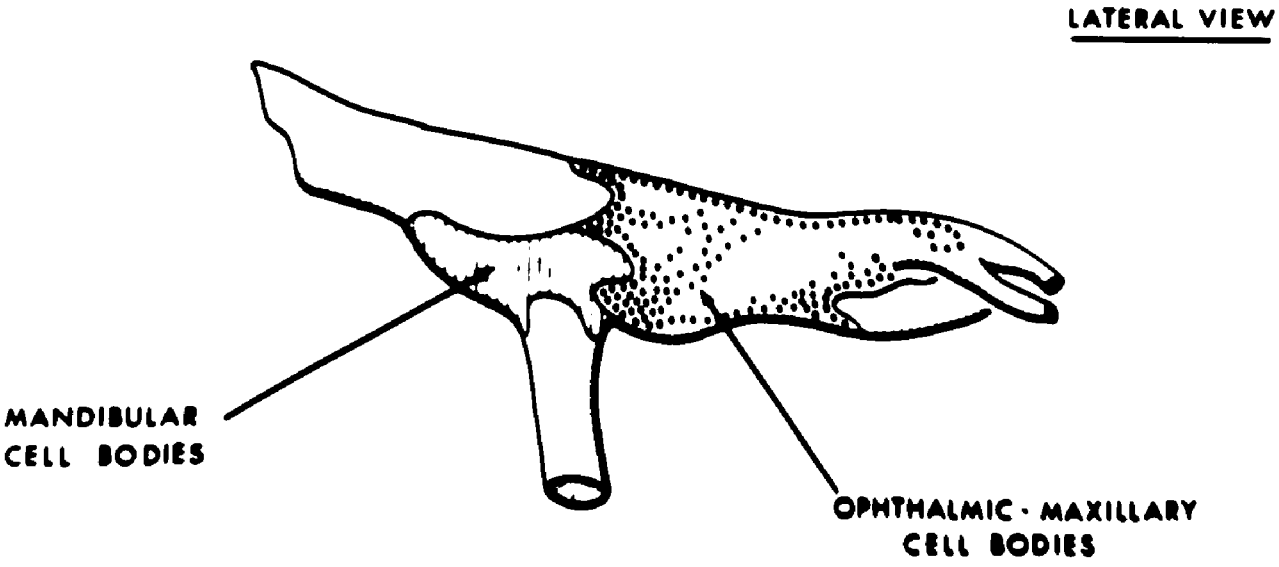
LATERAL VIEW
MANDIBULAR CELL BODIES
OPHTHALMIC - MAXILLARY CELL BODIES

5

FIGURE 6

SOMATOTOPIC PATTERNS IN THE TRIGEMINAL GANGLION OF THE ADULT RAT DETERMINED FOLLOWING INFERIOR ALVEOLAR NERVE SECTION AT MANDIBULAR FORAMEN

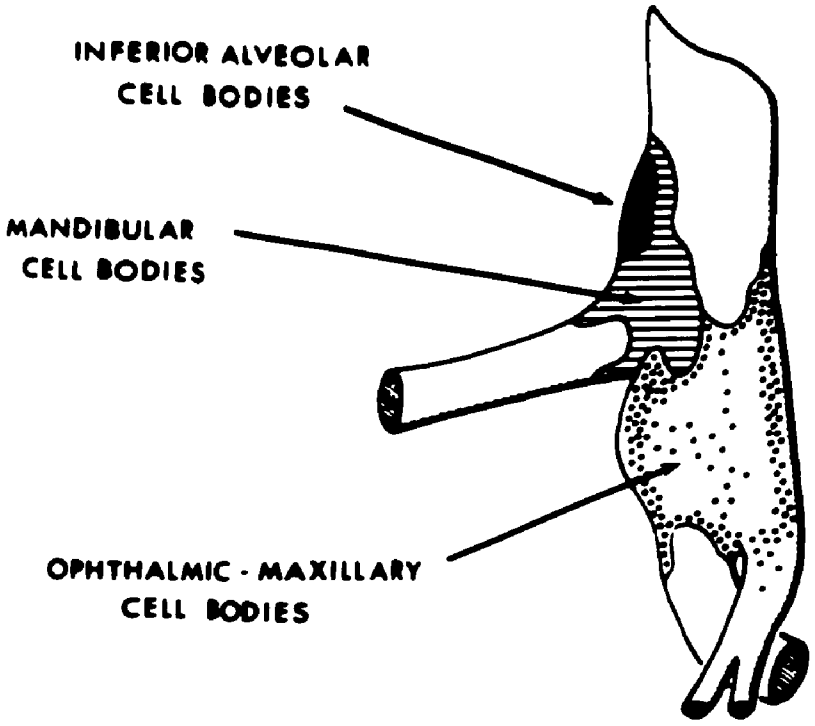

DORSAL VIEW

LATERAL VIEW

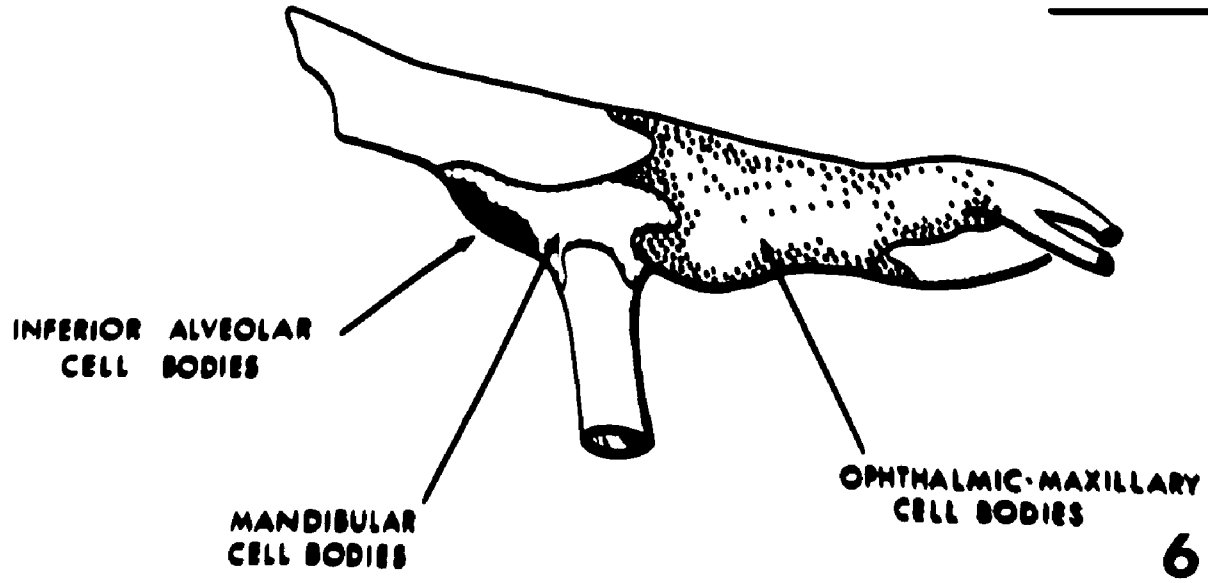

6

extracranial nerve section made at foramen ovale was located over three millimeters from the closest ganglion cell bodies and more likely between 3.5 and 5.0 millimeters from the bulk of these cell bodies. The more distal nerve section at mandibular foramen was located approximately 5.7 to 7.6 millimeters from the nearest mandibular division ganglion cell bodies (Figure 2).

The cell bodies of the normal adult rat trigeminal ganglion were found to be distributed in an anteromedial to posterolateral pattern (Figure 5). The cell bodies were more heavily concentrated along the walls of the ganglion and those found within the central core of the ganglion were more diffuse and scattered in small nests. Observation of chromatolytic patterns following foramen ovale nerve section revealed that the mandibular division cell bodies were not freely interspersed with those of the ophthalmic and maxillary divisions, although a central core of third division nuclei appeared to extend anteriorly into the ophthalmic and maxillary division areas (Figure 5). A dense collection of cell bodies was concentrated ventrally in the bifurcation region between the third and first two nerve divisions. The remainder of the ophthalmic and maxillary division cell bodies were scattered more diffusely and peripherally throughout the intracranial course of those divisions. Cell bodies were found to extend the furthest peripheral onto the ophthalmic nerve and many diffuse nests of cell bodies were found as far peripheral as the point of nerve exit at the anterior lacerated foramen. Observation of chromatolytic patterns following inferior alveolar nerve section showed that the cell bodies of the inferior alveolar nerve were located diffusely within the more ventral and posterior portions of the mandibular division cell mass (Figure 6).

Adult Rat Reaction

Trigeminal ganglion reaction following foramen ovale nerve section in the adult rat.

Throughout the period of one-half to two weeks following foramen ovale nerve section a classic chromatolytic reaction was observed within the trigeminal ganglion (Figures 7, 10, 11). Two basic cellular responses were observed at four days post-operative. The smaller cells displayed a perinuclear tigrolysis of Nissl substance with no cellular irregularity. A second cellular reaction was observed predominantly in the larger ganglionic cells. These

neurons were slightly swollen, irregular and surrounded by a narrow perineuronal shrinkage space. The perinuclear cytoplasm was clear and the Nissl substance was heavily concentrated around the perimeter of the cell bodies. There appeared to be an increased number of binucleolate forms in the earliest reacting ganglia as compared to the control sides.

One week following foramen ovale nerve section nearly all ganglionic cells demonstrated chromatolytic changes similar to the second variety described above. There was generalized cellular swelling and irregularity, cytoplasmic clearing with a fine granularity of Nissl substance and variable eccentricity of the nuclei (Figure 7). Shrinkage spaces were most evident around the larger, more severely chromatolytic neurons and the satellite cells appeared to be more prominent throughout the sections. As early as one week after nerve section a severe demyelination of the mandibular peripheral nerve process was observed at its point of divergence from the cell bodies within the trigeminal ganglion. The primary segment for approximately 100 micra appeared normally myelinated. Myelin debris, and clumps along with some phagocytic leucocytes and numerous prominent Schwann cells were observed at this point of transition (Figures 8, 9). A similar demyelination was seen immediately adjacent to the ganglia at one and one-half and two weeks following foramen ovale nerve section.

In addition to the classic chromatolytic response that was observed in the earlier post-operative periods, a definite process of ganglion cell disintegration was seen as early as one week following foramen ovale nerve section. This process appeared to begin by a thinning of the central portions of the cell body with a compaction of cytoplasm around the walls of the cellular space (Figures 7, 10). The nuclei were frequently seen to be fragmented within the pyknotic cell body peripheries. The earliest severe chromatolytic and disintegration changes seemed to occur most frequently in the larger ganglionic cells.

At one and one-half and two weeks following foramen ovale nerve section the disintegration of trigeminal ganglia cells appeared to be most profound (Figure 10). Cells were seen to be irregularly pyknotic, the nuclei were often fragmented and nucleoli were difficult to distinguish in these cells. Using the cellular spaces as criteria it appeared that the most severely disintegrative cells were from the large cell population. In addition, the most severely reacting cells were found within the posteroventral ganglion regions, the area that somatotopically corresponds to the inferior alveolar nerve.

FIGURE 7

TRIGEMINAL GANGLION OF THE ADULT RAT
ONE WEEK FOLLOWING FORAMEN OVALE NERVE SECTION

Severe chromatolytic changes include Nissl substance dissolution and accumulation at cell peripheries, nuclear eccentricity, binucleolation, pericellular shrinkage space, and prominance of amphicytes. The larger cells appear more severly chromatolytic. A few neurons are undergoing early disintegration. (Kluver-Barrara, 600x)

NR – *Nissl substance dissolution and compaction at periphery, nuclear eccentricity*

BN – *binucleolation*

D – *neuron disintegration*

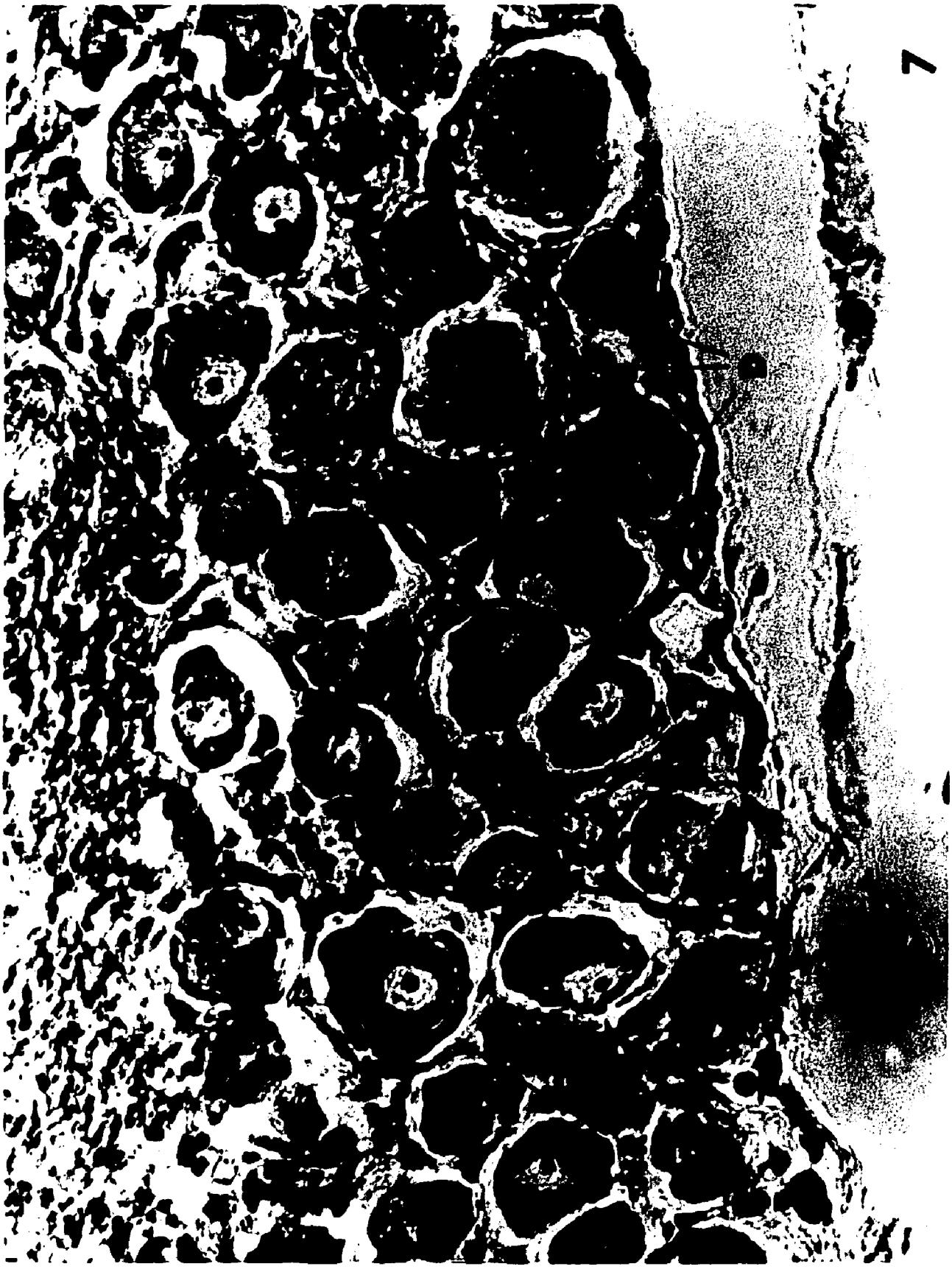

FIGURE 8

TRIGEMINAL GANGLION OF THE ADULT RAT

ONE WEEK FOLLOWING FORAMEN OVALE NERVE SECTION

The mandibular division trigeminal nerve process is visible adjacent to the mandibular division ganglion cells. Massive demyelination is apparent at this position on the nerve. (Kluver-Barrara, 75x)

GC – *trigeminal ganglion cells*

DM – *demyelinated nerve*

NM – *normally myelinated nerve*

8



FIGURE 9

TRIGEMINAL GANGLION OF THE ADULT RAT

ONE WEEK FOLLOWING FORAMEN OVALE NERVE SECTION

A higher power view of the intraganglionic mandibular nerve tissue of Figure 8 demonstrating the transition from normally myelinated to demyelinated nerve. Note the clumping of fragmented myelin, the prominance of Schwann cells and phagocytes. (Kluver-Barrara, 480x)

DM - *demyelinated nerve*

NM - *normal myelination*

PH - *phagocytes*


DWT
PH

FIGURE 10

TRIGEMINAL GANGLION OF THE ADULT RAT

ONE AND ONE-HALF WEEKS FOLLOWING FORAMEN OVALE NERVE SECTION

Most neurons appear to be severely chromatolytic. Neuron disintegration is widespread; glial cells and mononuclear leucocytes occupy areas of nuclear and cytoplasmic disintegration. (Kluver-Barrara, 480x)

D – *neuron disintegration*

GP – *gliosis and leucocytosis*



FIGURE 11

TRIGEMINAL GANGLION OF THE ADULT RAT

TWO WEEKS FOLLOWING FORAMEN OVALE NERVE SECTION

The final stages of neuron disintegration are evident including cell "ghosts" of fragmented cellular debris. The remaining cells are pyknotic and atrophic. (Kluver-Barrara, 378x)

CG – *cell "ghosts" with fragemented debris*

A – *atrophic, pyknotic cells*


CG

Although a full range of mild to extreme chromatolytic responses could be observed, the ganglion at two weeks following nerve section was typified by two basic extremes of cellular response. Numerous small, dark staining and slightly irregular cells were seen in direct contrast to larger cell spaces which frequently were seen to contain cell fragments and pyknotic debris (Figure 11). Prominant and excessive numbers of satellite cells were seen to rim these cell "ghosts". In intervals between these cellular nests there were concentrations of glial and small mononuclear scars.

Throughout the third, fourth and sixth weeks following nerve section the preponderant cell type observed was small, dark and apparently atrophic. Cell ghosts with pyknotic debris were occasionally observed. Overall cell density was variable but generally reduced over the density of the control specimens.

In the ganglia of animals that had survived ten and twenty weeks following nerve section the reduction in cell density was very evident and areas of scar consisted of both glial and fibroblastic elements. The ganglionic cells that remained after these long periods following operation were small and normally nucleated.

Trigeminal ganglion reaction following mandibular foramen nerve section in the adult rat.

The initial chromatolytic response observed following nerve section at the mandibular foramen appeared to develop as rapidly and profoundly as the response to foramen ovale. At one week following nerve section most of the cells within the inferior alveolai ganglionic distribution were grossly swollen, displayed slight nuclear eccentricity, and the cytoplasm was frequently finely granulated with compaction of Nissl substance to the cell perimeter (Figure 12). An occasional cell displayed disintegration features.

Throughout the second, third and fourth weeks following nerve section there was a gradual and progressive cell dissolution. As in the foramen ovale specimens the more severe response seemed to have occurred in the larger ganglion cells. In contrast to the foramen ovale nerve section cases, however, in which cell disintegration appeared to have progressed rapidly after the first week, the comparable disintegrative changes following mandibular foramen nerve section took place more slowly. Thus it appeared that a full range of response from mild chromatolysis to apparent total fragmentation was still visible four and six weeks

FIGURE 12

TRIGEMINAL GANGLION OF THE ADULT RAT

ONE WEEK FOLLOWING MANDIBULAR FORAMEN NERVE SECTION

A chromatolytic response is apparent in this ganglion, especially among the larger cells. Compared to the response observed at the comparable time following foramen ovale nerve section (Figure 7) this reaction is moderate. However, occasional disintegrating neuron forms are visible. (Kluver-Barrara, 600x)

D – *neuron disintegration*

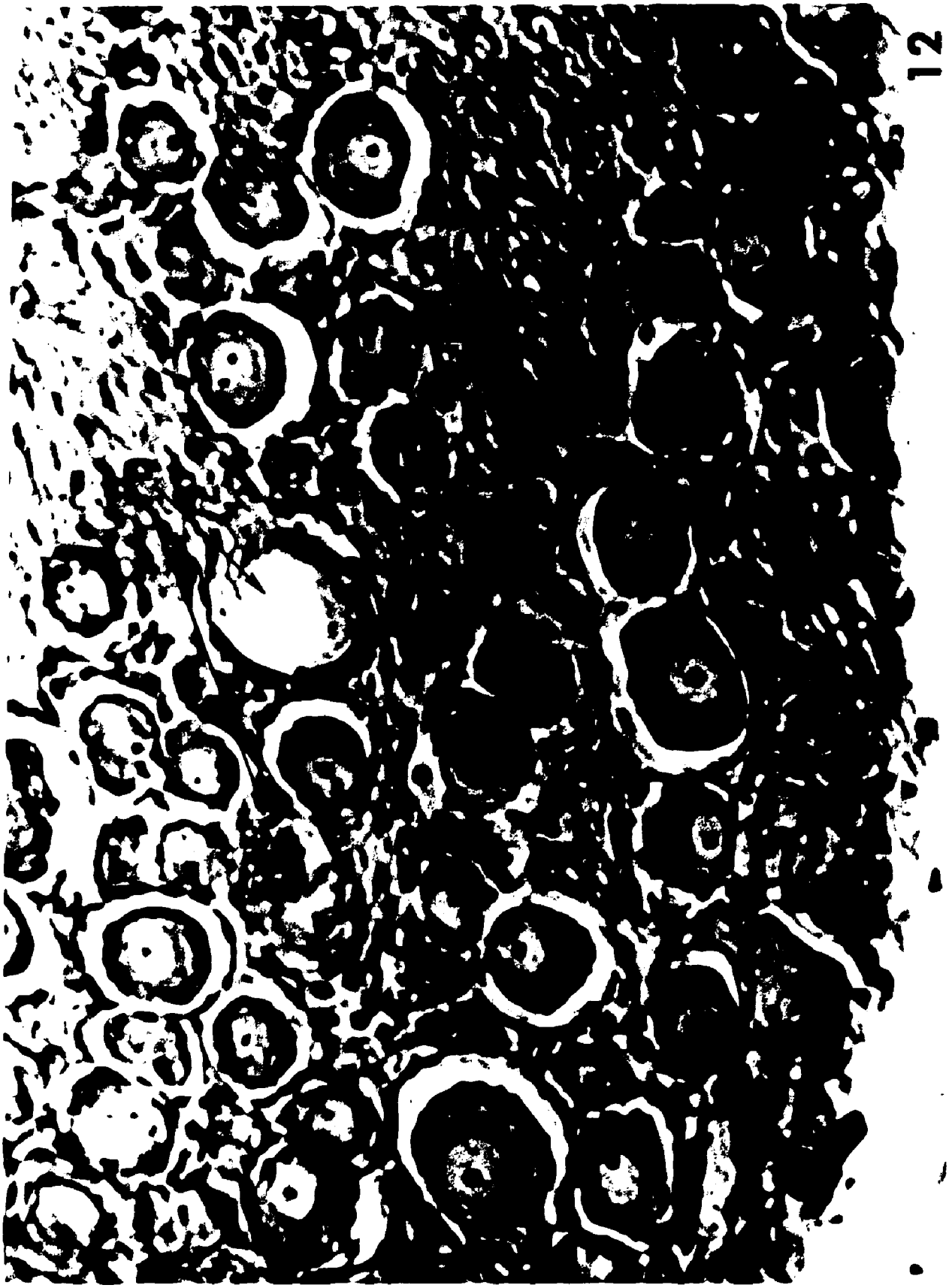

12

FIGURE 13

TRIGEMINAL GANGLION OF THE ADULT RAT
SIX WEEKS FOLLOWING MANDIBULAR FORAMEN NERVE SECTION

A wide range of severe chromatolytic forms remain along with many atrophic neurons surrounded by large pericellular shrinkage spaces. Fragmentation in cell spaces and glial scarring are also visible. (Kluver-Barrara, 300x)

D – *neuron disintegration*

GS – *glial scar*

A – *atrophic neurons*



13

FIGURE 14

TRIGEMINAL GANGLION OF THE ADULT RAT
TWENTY WEEKS FOLLOWING MANDIBULAR FORAMEN NERVE SECTION

The number of ganglion cells is greatly reduced over normal control populations. There are many cell "ghosts" which contain cellular debris and prominant amphicytes. The remaining ganglionic neurons are pyknotic and atrophic. (Kluver-Barrara, 378x)

CG – *cell "ghosts" with fragmented debris*



14

after mandibular foramen nerve section (Figure 13). The number of cells undergoing disintegration following mandibular nerve section was grossly less than the disintegration in comparable ganglionic areas following foramen ovale section.

At eight, ten and twenty weeks following mandibular foramen section the cell density was reduced from the normal control density (Figure 14). The density reduction however, was less than that of the foramen ovale nerve section specimens. The cell bodies that remained in the ganglia long periods following mandibular nerve section appeared for the most part normal. In contrast to the long term foramen ovale cellular atrophy, there were few obviously atrophic forms and the full range of cell sizes was seen.

Brain stem reaction following foramen ovale nerve section in the adult rat.

Observation of brain stem cross sections that were processed by the Fink-Heimer modification of the Nauta-Gygax technique failed to reveal any central degeneration at one-half, one, one and one-half, and two weeks following nerve section. At three weeks following foramen ovale nerve section, however, an intense granular degeneration was observed within the dorsal portions of the central trigeminal complex including sensory root, chief sensory and descending tract areas (Figures 15, 16, 35). The degeneration maintained a consistent dorsal somatotopic position throughout the caudal extent of the descending tract as far caudal as the second cervical segment and in all chief sensory and subnuclear areas. The density of Nauta granules seen at the three week post-operative period was markedly greater within the chief sensory root and nucleus as compared to the density observed in the descending tract and subnuclei. In addition, the density of degeneration appeared to diminish gradually at more caudal levels of the descending tract (Figures 16, 35). The quality of granules varied between the tract and the subnuclear tissues. Within the tract the degeneration granules were larger and more globular as compared to the more delicate and frequently beaded granules of the subnuclear areas.

Degeneration was also demonstrated with the Fink-Heimer technique at four and six weeks following nerve section (Figures 17, 18, 36). As in the three week specimen the greatest density of degeneration was observed in the more rostral chief sensory nucleus regions. However, there was less difference in the amount of degeneration between the

FIGURE 15

CHIEF SENSORY NUCLEUS AREA OF THE ADULT RAT
THREE WEEKS FOLLOWING FORAMEN OVALE NERVE SECTION

A high density of Nauta degeneration granules are visible within the chief sensory nucleus area. Granules vary in size but the predominant type appear to be smaller particles which frequently are seen to cluster around neuron cell bodies. (Fink-Heimer, 480x)

NG – *Nauta degeneration granules*

TD – *terminal degeneration*



FIGURE 16

SUBNUCLEUS CAUDALIS AREA OF THE ADULT RAT
THREE WEEKS FOLLOWING FORAMEN OVALE NERVE SECTION

The density of Nauta degeneration granules is markedly reduced when compared to the density of the more rostral chief sensory nucleus area displayed in Figure 12. An adjacent area within the cuneate nucleus is void of granules. (Fink-Heimer, 480x)

CN – *cuneate nucleus*

CV – *subnucleus caudalis of trigeminal*

NG *Nauta granules*


16
NG
CN

FIGURE 17

CHIEF SENSORY NUCLEUS AREA OF THE ADULT RAT
SIX WEEKS FOLLOWING FORAMEN OVALE NERVE SECTION

Nauta degeneration granules are visible within the most dorsal portions of the chief sensory nucleus. An adjacent area of the middle cerebellar peduncle is void of degeneration granules. The granules seen in the descending tract are larger and globular as compared to the more particulate and beaded forms within the chief sensory nucleus. (Fink-Heimer, 240x)

CS – *chief sensory nucleus*

DV – *descending tract of trigeminal*

MCP – *middle cerebellar peduncle*


DV
MCP

FIGURE 18

CHIEF SENSORY NUCLEUS AREA OF THE ADULT RAT
SIX WEEKS FOLLOWING FORAMEN OVALE NERVE SECTION

A higher power view demonstrating the details of beaded fiber and terminal degeneration forms in the subnuclear area.

TD – *terminal degeneration*

FD – *fiber degeneration*


18
RD
TD

FIGURE 19

ROSTRAL PORTION OF THE DESCENDING TRACT OF TRIGEMINAL
IN THE ADULT RAT TEN WEEKS FOLLOWING FORAMEN OVALE NERVE SECTION

Marchi degeneration granules occupy the dorsal one-third of the descending tract of trigeminal at the level of the chief sensory nucleus. In this figure dorsal is to the right and ventral to the left. (Marchi, 60x)

MG – *Marchi degeneration granules*

DV – *descending tract of trigeminal*

CS – *chief sensory nucleus of trigeminal*

MV – *motor root of trigeminal*


19
B

FIGURE 20

LOW MEDULLA LEVEL OF THE ADULT RAT THREE WEEKS
FOLLOWING FORAMEN OVALE NERVE SECTION

The position of the myelin disintegration observed is shown within the dorsal and medial portions of the descending tract of trigeminal. (Kluver-Barrara, 60x)

MD – *myelin disintegration*

CV – *subnucleus caudalis of trigeminal*

DV – *descending tract of trigeminal*

NM – *normal myelination*



FIGURE 21

LOW MEDULLA LEVEL OF THE ADULT RAT THREE WEEKS
FOLLOWING FORAMEN OVALE NERVE SECTION

Higher power view of myelin disintegration and an adjacent area of normal myelination. The glial and phagocytic cells are prominent within the degenerate area. (Kluver-Barrara, 240x)

MD – *myelin disintegration*

NM – *normal myelination*

GP – *glial and phagocytic cells*



FIGURE 22

HYPOGLOSSAL NUCLEUS LEVEL OF THE ADULT RAT
THREE WEEKS FOLLOWING FORAMEN OVALE NERVE SECTION

The pattern of demyelination and gliosis is evident within the descending tract of trigeminal. In addition, disintegrating myelin beads are visible within the adjacent subnuclear area. (Kluver-Barrara, 180x)

MD – *myelin disintegration*

DV – *descending tract of trigeminal*

IV – *subnucleus interpolaris of trigeminal*


22

more rostral and more caudal levels than had been observed in the three week specimen. The relative concentration of degeneration appeared to have shifted caudally down the brain stem in the four and six week specimens (Figures 35, 36).

The pattern and extent of degeneration observed at three weeks after operation was the greatest of any post-operative interval. This reaction was seen to approach in extent and pattern the "total" trigeminal mandibular division lesions that had been prepared by Torvik ('56) by intracranial nerve section. However, in no instance was there evidence of degeneration within nucleus supratrigeminalis, within fasciculus solitarius, within any of the cerebellar peduncles, or within lateral reticular areas adjacent to any part of the trigeminal. The central trigeminal areas which correspond somatotopically to the ophthalmic and maxillary divisions were void of degeneration response. Similarly the contralateral control tracts and nuclear areas failed to demonstrate degeneration.

Specimens that were treated by the Marchi technique ten and twenty weeks following foramen ovale nerve section demonstrated moderate degeneration (Figure 19). Marchi granules were most frequent in the dorsal portions of the sensory root, in the chief sensory nucleus and in the most rostral descending tract areas. The granules became gradually less frequent and smaller at more caudal levels (Figure 39).

Kluver and Barrara staining of representative brain stem cross sections revealed no abnormality before three weeks following nerve section. In the three week specimen, however, myelin fragmentation and associated gliosis was clearly visible within the most dorsal and medial portions of the entire descending tract of trigeminal (Figures 20, 21, 22). Similar changes at longer intervals following surgery were not detected.

Brain stem reaction following mandibular foramen nerve section in the adult rat.

There was no evidence of Nauta degeneration seen in the interval one-half to three weeks following mandibular foramen nerve section. Four weeks following nerve section, however, Nauta degeneration was seen primarily within the trigeminal root tissues entering the pons. The granules were located within the dorsal portions of the root and a few scattered granules were also seen in the dorsal portions of the root entering the chief sensory nucleus (Figure 23). At six weeks following nerve section, degeneration was seen to

FIGURE 23

CHIEF SENSORY NUCLEUS AREA OF THE ADULT RAT
SIX WEEKS FOLLOWING MANDIBULAR FORAMEN NERVE SECTION

Nauta degeneration granules are visible within the chief sensory nucleus area. Patterns of degeneration include beaded fibers and clusters terminating on nuclear cell bodies. The density of degeneration granules observed in this specimen is much less than the density seen in Figures 12 and 14. (Fink-Heimer, 480x)

NG – *Nauta degeneration granules*

CS – *chief sensory nucleus*

MCP – *middle cerebellar peduncle*


Z3
MCP

FIGURE 24

LOW MEDULLA LEVEL OF THE ADULT RAT TWENTY WEEKS

FOLLOWING MANDIBULAR FORAMEN NERVE SECTION

Marchi degeneration granules are localized in the most dorsal and medial portions of the caudal descending tract of trigeminal. The position and extent of the inferior alveolar degeneration can be contrasted to the approximate entire third division of trigeminal somatotopic area (bracketed). In this figure dorsal is to the right and ventral to the left. (Marchi, 60x)

MG – *Marchi degeneration granules*

V_3 – *mandibular division of trigeminal somatotopic area*

CV – *subnucleus caudalis of trigeminal*


24
3

FIGURE 25

LOW MEDULLA LEVEL OF THE ADULT RAT TWENTY WEEKS
FOLLOWING MANDIBULAR FORAMEN NERVE SECTION

Higher power view of Marchi degeneration granules within the descending tract of trigeminal at the subnucleus caudalis level. (Marchi, 240x)

CV – *subnucleus caudalis of trigeminal*

MG – *Marchi degeneration granules*


25

be more dense than that observed at four weeks (Figures 37, 38). The heaviest concentration was in the root fibers entering the chief sensory nucleus and in the most rostral portions of the descending tract as far caudal as the sixth nerve nucleus. Compared to the Nauta reaction observed in response to foramen ovale nerve section the reaction to mandibular nerve section appeared to develop more slowly and was much less dense, and tended to localize in the sensory root, chief sensory and rostral descending tract areas of the trigeminal complex. No Nauta degeneration was seen at eight weeks following mandibular foramen section.

Marchi staining of specimens ten weeks following mandibular foramen nerve section resulted in positive degeneration granules located in the sensory root and those portions of the tract which entered the chief sensory nucleus (Figure 40). By twenty weeks following nerve section, however, Marchi granules were also located within the more caudal portions of the trigeminal complex including areas adjacent to subnucleus interpolaris (Figures 24, 25). In contrast to the degeneration observed following foramen ovale nerve section, the granules seen in the mandibular foramen specimens were fewer in number by approximately one-half and they were confined to the extreme dorsal and medial portions of the trigeminal descending tracts (Figures 39, 40, 41).

Adult Cat Reaction

Trigeminal ganglion reaction following foramen ovale nerve section in adult cat.

The wide range of early acute chromatolytic cell responses to nerve section described for the adult rat were also seen in the adult cat (Figure 26). In addition, disintegration of ganglionic neurons was seen in the cat trigeminal as early as three weeks following nerve section. The cytologic response of the cat differs from that of the rat, however, in that the more mild chromatolytic features of swelling, clearing and eccentric nucleation appeared to be the more predominant response in the cat and lasted for a longer period following surgery. Even at six weeks following foramen ovale nerve section the trigeminal ganglion demonstrated a scattering of mildly and more acutely chromatolytic forms intermingled with disintegrating neurons (Figure 26). In addition, the cat appeared to be more resistent to rapid disintegration of ganglionic neurons. There were no instances of massive sensory root

demyelination in the cat similar to what had been observed in the rat one week after nerve section. The more gradual disintegration of neurons was also evident at the ten weeks post-operative interval when rather normal neurons were seen interspersed with disintegrating forms, cell "ghosts" and glial scarred areas (Figure 27).

Trigeminal ganglion reaction following mandibular foramen nerve section in the adult cat.

The series of cats investigated following mandibular foramen nerve section was limited to two animals. Four weeks after surgery the ganglionic response was seen to be mildly chromatolytic with scattered disintegration forms present. At twenty weeks after surgery a striking loss of ganglionic neurons was evident within the mandibular division area. The scarcity of neurons and presence of glial and fibroblastic scarring appeared to surpass the degree of disintegrative and cell loss changes observed in any of the foramen ovale specimens (Figures 28, 29).

Brain stem reaction following foramen ovale nerve section in the adult cat.

The Fink-Heimer technique was applied to the cat only at six weeks following surgery. No Nauta degeneration was detected at this time in any areas of the central trigeminal tract. There also was no evidence of tract demyelination or transneuronal degeneration in brain stem subnuclear areas as demonstrated by the Kluver-Barrara stain.

Degeneration was not detectable with the Marchi technique at eight weeks following foramen ovale nerve section. However, at ten weeks following surgery, moderate Marchi granulation was seen within the dorsal portions of the trigeminal descending tract. Degeneration was confined primarily to the sensory root and more rostral regions of the descending tract adjacent to the chief sensory nucleus. Marchi degeneration was also observed at twenty weeks following foramen ovale nerve section. The greatest concentration of granules was observed at the level of the seventh nerve exit and adjacent to subnucleus rostralis. Compared to the adult rat, the preponderance of degeneration within the chief sensory nucleus over the descending tract areas was greater in the cat.

FIGURE 26

TRIGEMINAL GANGLION OF THE ADULT CAT SIX WEEKS
FOLLOWING FORAMEN OVALE NERVE SECTION

A wide range of mild to extreme chromatolysis may be seen within this ganglion. Cell swelling, Nissl substance dissolution, and nuclear eccentricity are clearly visible. The largest cells appear most severely affected. Other neurons are anuclear and fragmented, and are associated locally with a focal gliosis. (Kluver-Barrara, 240x)

D – *neuron disintegration*

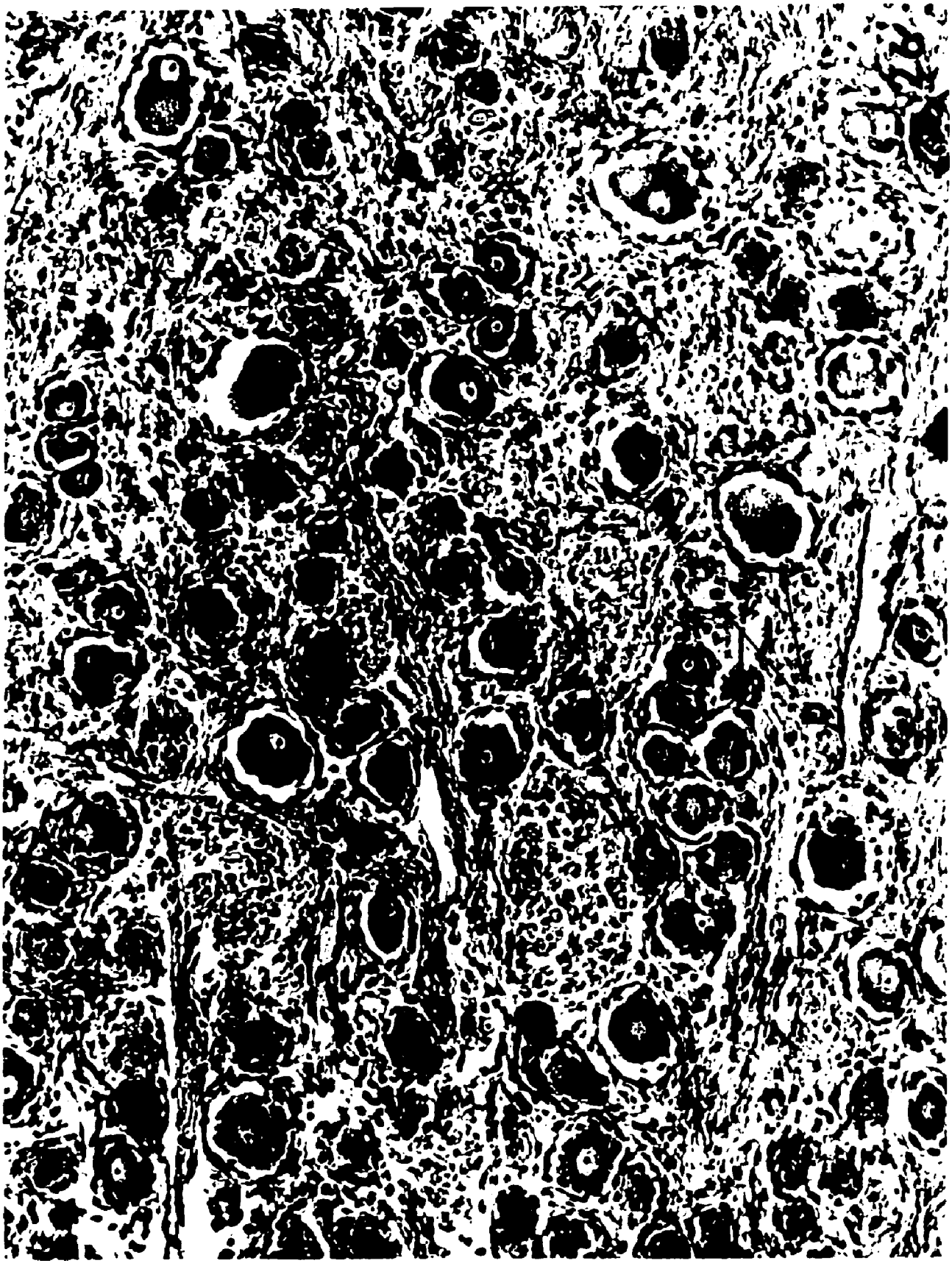

FIGURE 27

TRIGEMINAL GANGLION OF THE ADULT CAT TEN WEEKS FOLLOWING FORAMEN OVALE NERVE SECTION

There are numerous cell "ghosts" and spaces containing cellular debris within this ganglion. Most of these areas are infiltrated with many glial cells. In contrast to the histologic picture observed in Figure 26, there are few mild chromatolytic changes within the residual neurons. Instead, the cells are dark and atrophic. (Kluver-Barrara, 240x)

CG – *cell "ghosts" with fragmented debris*

A – *atrophic, dark neurons*

GP – *gliosis, phagocytosis*

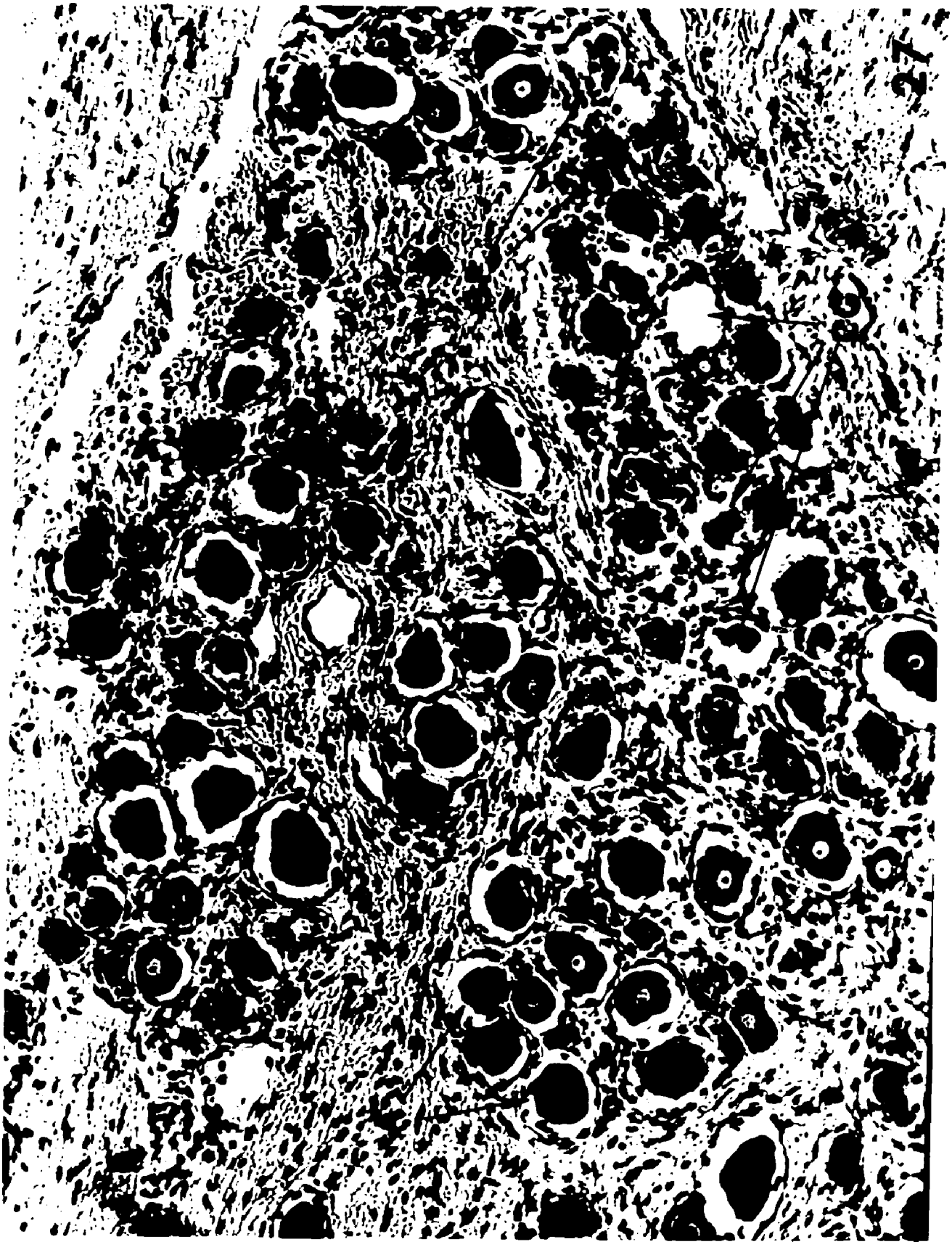

FIGURE 28

TRIGEMINAL GANGLION OF THE ADULT CAT TWENTY WEEKS FOLLOWING MANDIBULAR FORAMEN NERVE SECTION

There is an extreme loss of neuron cell bodies and replacement by scar tissues within the mandibular division area. Scar tissue has largely invaded and replaced the missing neural elements. (Kluver-Barrara, 60x)

GS – *glial scar*

A – *atrophic neurons*

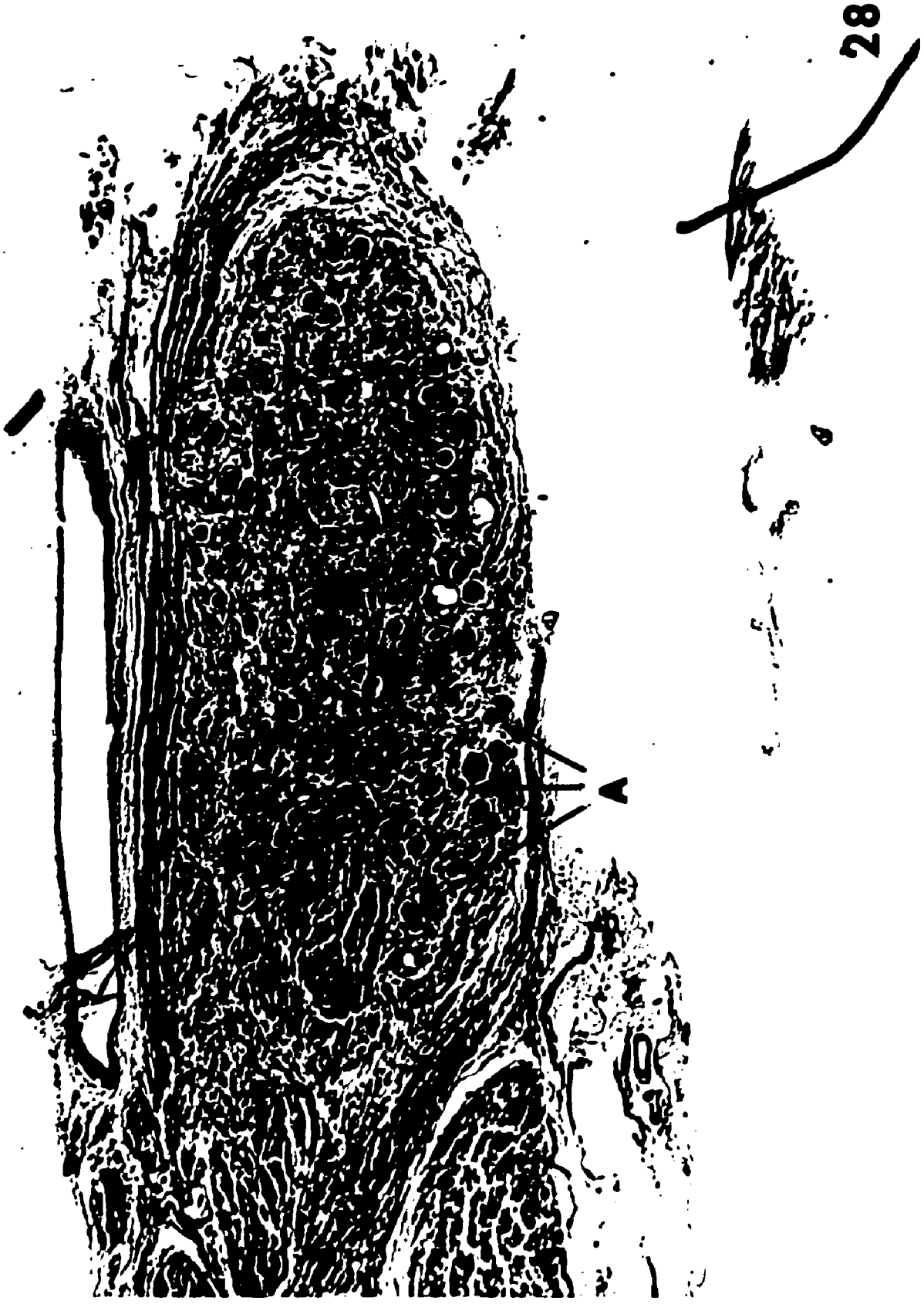
28

FIGURE 29

TRIGEMINAL GANGLION OF THE ADULT CAT TWENTY WEEKS
FOLLOWING MANDIBULAR FORAMEN NERVE SECTION

A higher power view of the trigeminal ganglion presented in Figure 28 demonstrating the continued disintegration and loss of neurons. Glial and phagocytic cells are concentrated around the necrotic and atrophic ganglion cells. A Schwann cell and fibroblast scar has replaced most of this ganglion, leaving atrophic neurons. (Kluver-Barrara, 240x)

GP – *gliosis and phagocytosis*

GS – *glial scar*

D – *neuron disintegration*


GP
D

FIGURE 30

TRIGEMINAL SENSORY ROOT OF THE ADULT CAT TWENTY WEEKS FOLLOWING MANDIBULAR FORAMEN NERVE SECTION

Marchi degeneration granules are heavily concentrated in the more dorsal and peripheral portions of the trigeminal sensory root at its point of entry into the pons. (Marchi, 150x)

MCP – *middle cerebellar peduncle*

SR – *sensory root of trigeminal*

MG – *Marchi granules*

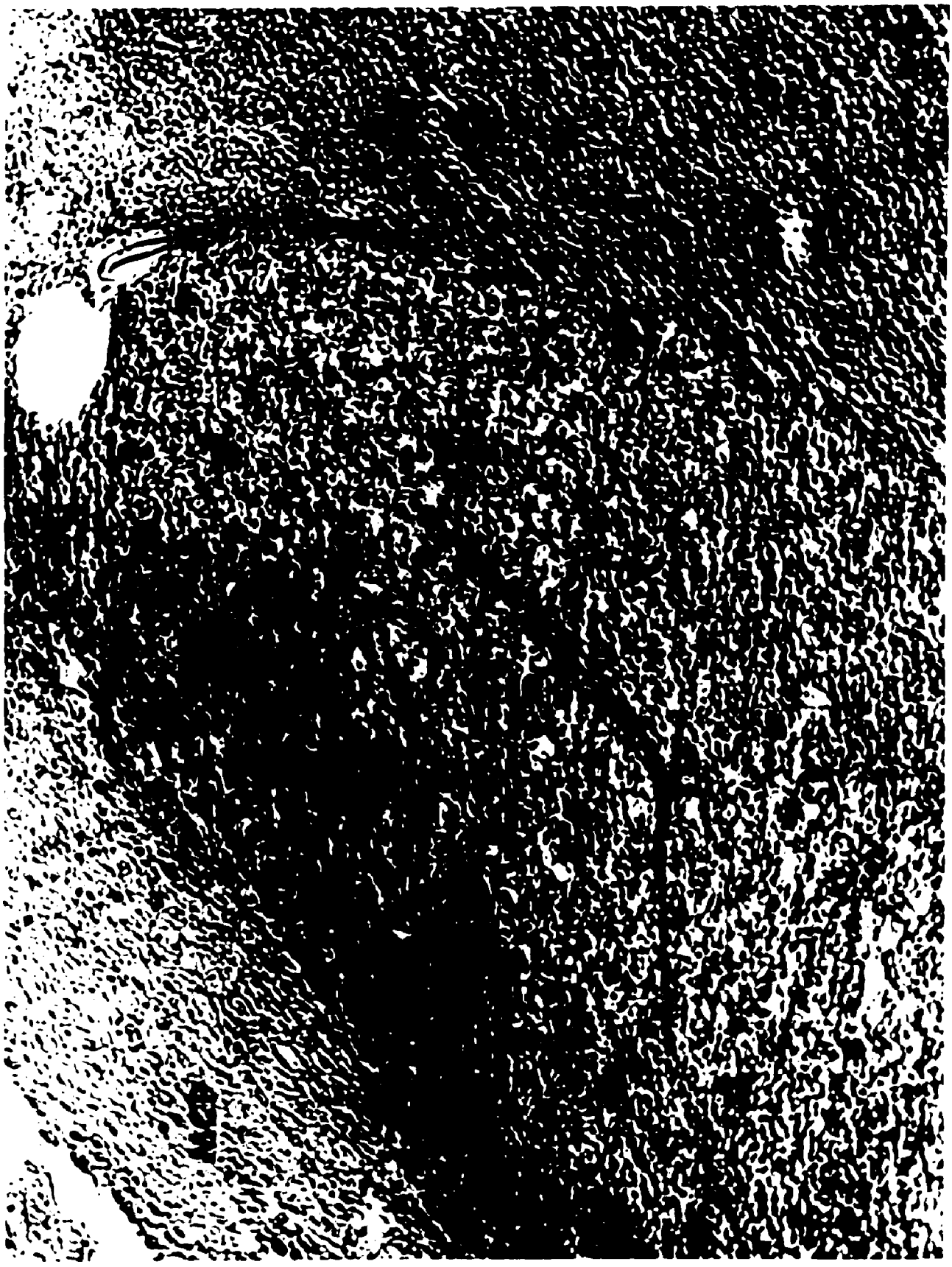

FIGURE 31

ROSTRAL PORTION OF THE DESCENDING TRACT
OF TRIGEMINAL IN THE ADULT CAT TWENTY WEEKS
FOLLOWING MANDIBULAR FORAMEN NERVE SECTION

Marchi degeneration granules are localized in the dorsal one-third of the descending tract of trigeminal and may be seen within the chief sensory nucleus at the same level. The granules within the tract are larger and more globular when compared to the granules within the chief sensory nucelus. In this figure dorsal is to the right and ventral to the left. (Marchi, 60x)

VII – *root of the Facial nerve*

CS – *chief sensory nucleus of trigeminal*

DV – *descending tract of trigeminal*


31
35

Brain stem reaction following mandibular foramen nerve section in adult cat.

The Fink-Heimer technique was applied only to the cat four weeks after nerve section. No Nauta degeneration was observed at this time in any portion of the central trigeminal complex.

At twenty weeks following mandibular foramen nerve section Marchi degeneration was moderately heavy and concentrated in the sensory root and more rostral portions of the descending tract adjacent to the chief sensory nucleus (Figures 30, 31). Marchi granules were observed within the chief sensory nucleus, but were not observed within any of the subnuclei of the descending tract of trigeminal.

Young Rat Reaction

Trigeminal ganglion reaction following foramen ovale nerve section in the young rat.

The trigeminal ganglia of young rats that were studied two, four, and six weeks following foramen ovale nerve section displayed little evidence of the classic milder chromatolytic reactions that were observed in the adult rat. Most of the neurons present were small, dark and regular in outline with minimal nuclear eccentricity (Figure 32). There appeared to be an overall loss of ganglion cell numbers and scattered cell ghosts were visible. No glial scars were observed.

Trigeminal ganglion reaction following mandibular foramen nerve section in the young rat.

The trigeminal ganglia of young rats that were studied at two, four and six weeks after mandibular foramen nerve section resembled those ganglia of the foramen ovale specimens. The cells were uniformly atrophic appearing without evidence of any larger, chromatolytic neurons (Figure 33).

Brain stem reaction following foramen ovale nerve section in the young rat.

Nauta degeneration was observed at all intervals following foramen ovale nerve section in the young rat. In contrast to the adult rat in which no degeneration was

FIGURE 32

TRIGEMINAL GANGLION OF THE YOUNG RAT

TWO WEEKS FOLLOWING FORAMEN OVALE NERVE SECTION

Cell numbers are grossly reduced over control ganglion populations. A scattering of nerve disintegration forms is visible among the residual neurons which are atrophic and pyknotic. Glial scarring is minimal. (Kluver-Barrara, 378x)

A – *atrophic, pyknotic cells*

D – *neuron disintegration*



32

FIGURE 33

TRIGEMINAL GANGLION OF THE YOUNG RAT

TWO WEEKS FOLLOWING MANDIBULAR FORAMEN NERVE SECTION

Many cell spaces contain debris from neuron disintegration. Most of the remaining neurons are atrophic; gliosis is moderate and binucleolation forms are apparent. (Kluver-Barrara, 240x)

CG – *cell "ghosts" and fragmented debris*

GP – *gliosis and phagocytosis*

BN – *binucleolation*



33

detected prior to the three week interval after surgery, degeneration had apparently proceded well into the brain stem of the young rats by two weeks following nerve section. The quantity of degeneration granules seen at two weeks after nerve section equalled that seen at six weeks in the adult animal. Degeneration was heaviest in the chief sensory nucleus area although subnuclear areas of the descending tract of trigeminal were also well represented.

Brain stem reaction following mandibular foramen nerve section in the young rat.

Nauta degeneration was observed at two, four and six weeks following mandibular foramen nerve section in the young rat. Compared to the nerve degeneration patterns observed in response to the foramen ovale nerve section in young rats, the degeneration in this series appeared even more heavily concentrated in the chief sensory tract at two weeks after surgery. The degeneration was also observed as far caudal as the second cervical segment at two weeks after nerve section. At these intervals the overall density of Nauta degeneration observed following mandibular foramen nerve section actually appeared greater than the density following foramen ovale nerve section in the young rat.

Summary of Observations

1. Chromatolytic reactions within the trigeminal ganglia of adult rats following peripheral nerve sections revealed that the mandibular division cells are localized posterolaterally and concentrated around the ganglia peripheries. The inferior alveolar cell bodies are positioned posteriorly and on the ventral surface of the mandibular division.

2. A disintegration and phagocytosis of myelin was observed in the mandibular peripheral nerve processes at their point of divergence from the trigeminal ganglia one and two weeks after foramen ovale nerve section.

3. The trigeminal ganglia cells of the adult rat reacted to nerve section at foramen ovale by a progressive chromatolysis, disintegration and loss of neuron cell bodies. Section of the inferior alveolar nerve resulted in similar reactions, although the response was more gradual and quantitatively reduced over the response to foramen ovale nerve section. The larger ganglion cells appeared more severely affected by both nerve sections.

4. Application of the Kluver-Barrara stain to the brain stem of the adult rat three weeks following foramen ovale nerve section revealed a demyelination process within the dorsal portions of the entire trigeminal tract complex.

5. Degeneration was detected within the central trigeminal processes of the adult rat following both foramen ovale and mandibular foramen nerve sections. Nauta degeneration was first observed three weeks after foramen ovale nerve section and four weeks following mandibular foramen section; Marchi degeneration was seen at ten and twenty weeks following both of the nerve sections. In each series the degeneration was localized in the dorsal portions of all tract and subnuclear areas and it appeared to progress centrifugally into and caudally down the brain stem. The density of degeneration was greater in the chief sensory nucleus area and diminished progressively at more caudal levels; degeneration was observed as far caudal as the second cervical cord level following foramen ovale nerve section. The response to mandibular foramen nerve section was more delayed, was quantitatively less and did not extend as far caudally.

6. The trigeminal ganglia of the cat reacted to both foramen ovale and mandibular foramen nerve section by a progressive chromatolysis, disintegration and loss of ganglionic cell bodies. The chromatolysis appeared to be more severe among the larger cells but the response was more protracted than in the rat. The cat appeared generally more resistent to the effect of nerve sections.

7. In the brain stem of the adult cat degeneration was seen with the Marchi technique ten and twenty weeks following both foramen ovale and mandibular foramen nerve section. The response was similar to the adult rat in its dorsal somatotopic position and its apparent centrifugal progression into the brain stem at longer intervals following surgery. The cat differed from the rat, however, in that the preponderance of degeneration for the chief sensory nucleus relative to the descending tract was greater for the cat.

8. The trigeminal ganglia of young rats following both foramen ovale and mandibular foramen nerve section were grossly deficient of neurons and contained atrophic residual ganglion cells. No acute chromatolytic cells similar to those of the adult were seen although disintegrated cell forms were visible.

9. Nauta degeneration was observed in the brain stems of young rats following both of the nerve section operations. Compared to the adult rat the degeneration appeared at a shorter interval following surgery and there was little difference between the extensiveness of degeneration that had been produced by either of the two different nerve lesions.

FIGURE 34

PLANE OF SECTION AND ORIENTATION FOR ATLASES OF BRAIN STEM DEGENERATION IN THE ADULT RAT

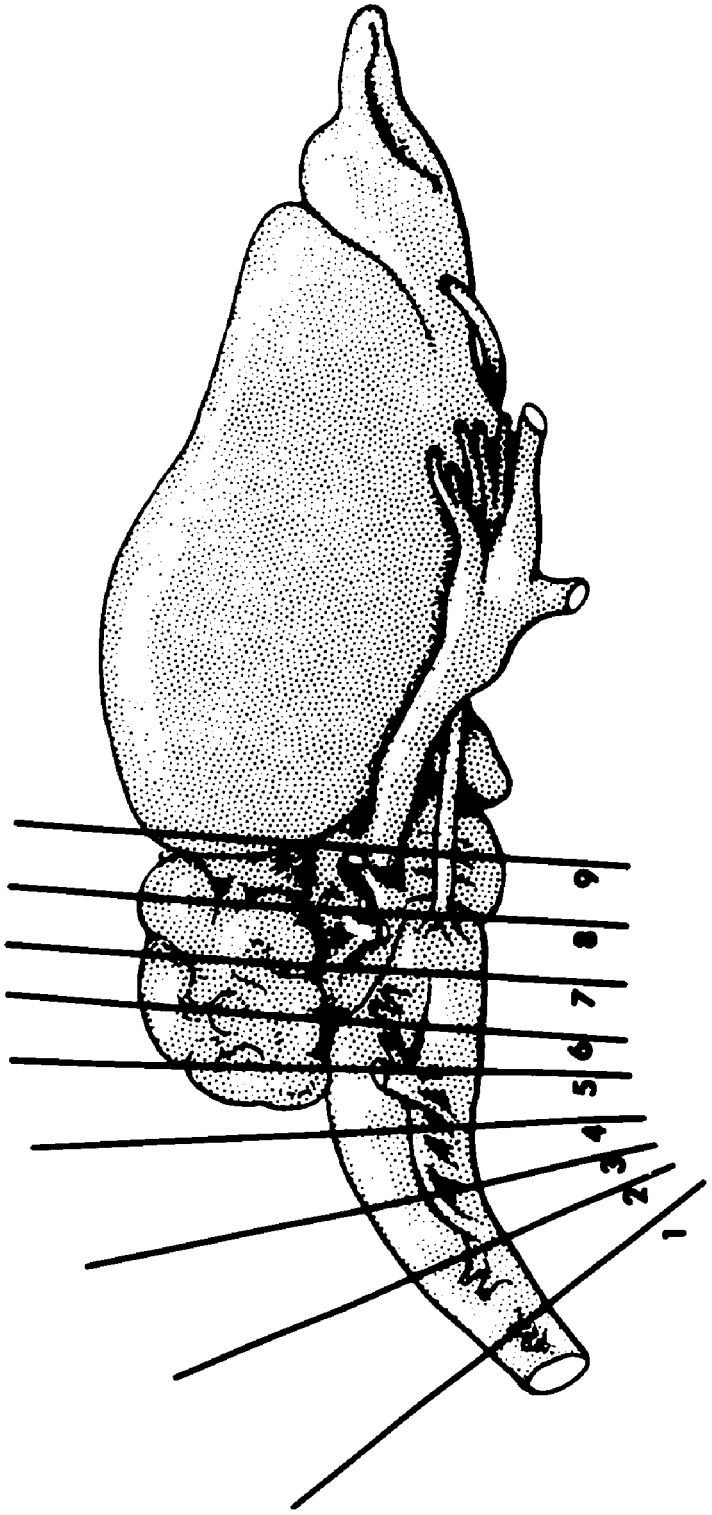

34

FIGURE 35

NAUTA DEGENERATION PATTERNS IN THE ADULT RAT THREE WEEKS FOLLOWING FORAMEN OVALE NERVE SECTION

aff VII, IX, X – *afferent fibers of VII, IX, X*

CV – *nucleus caudalis, trigeminal*

CN – *cuneate nucleus*

CSV – *chief sensory nucleus, trigeminal*

DVN – *dorsal vestibular nucleus*

FS – *fasciculus solitarius*

GVII – *genu of VII*

GN – *nucleus gracilis*

ICP – *inferior cerebellar peduncle*

IV – *nucleus interpolaris, trigeminal*

MV – *motor nucleus, trigeminal*

MesV – *mesencephalic nucleus, trigeminal*

MCP – *middle cerebellar peduncle*

MRV – *motor root, trigeminal*

MVN – *medial vestibular nucleus*

OV – *nucleus oralis, trigeminal*

PD – *pyramidal decussation*

RVII, VIII, IX, X, XII – *root fibers of VII, VIII, IX, X, XII*

RF – *reticular formation*

SCP – *superior cerebellar peduncle*

SG – *substantia gelatinosa*

SV – *nucleus supratrigeminalis*

SpV – *spinal tract, trigeminal*

SRV – *sensory root, trigeminal*

SVN – *superior vestibular nucleus*

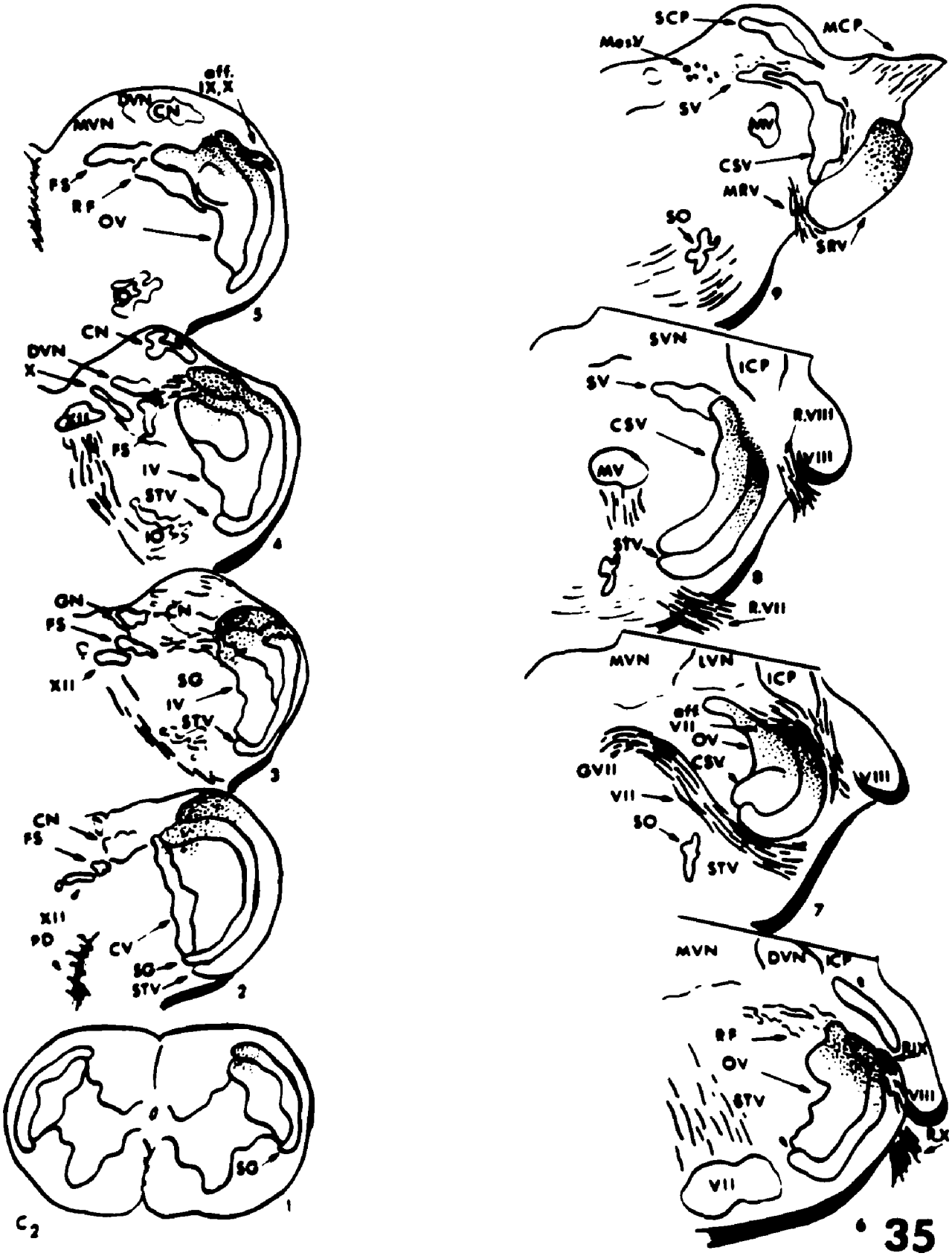
aff. IX,X
DVN
CN
MVN
FS
RF
OV
5
CN
DVN
X
XII
FS
IV
STV
IO
4
GN
FS
CN
XII
SG
IV
STV
3
CN
FS
XII
PD
CV
SG
STV
2
SG
1
C2
SCP
MCP
MesV
SV
MV
CSV
MRV
SO
SRV
9
SVN
ICP
SV
CSV
R.VIII
VIII
MV
STV
8
R.VII
MVN
LVN
ICP
aff
VII
OV
CSV
GVII
VIII
VII
SO
STV
7
MVN
DVN
ICP
RF
OV
STV
RIX
VIII
RX
VII
6

35

FIGURE 36

NAUTA DEGENERATION PATTERNS IN THE ADULT RAT
SIX WEEKS FOLLOWING FORAMEN OVALE NERVE SECTIONS

aff VII, IX, X – *afferent fibers of VII, IX, X*

CV – *nucleus caudalis, trigeminal*

CN – *cuneate nucleus*

CSV – *chief sensory nucleus, trigeminal*

DVN – *dorsal vestibular nucleus*

FS – *fasciculus solitarius*

GVII – *genu of VII*

GN – *nucleus gracilis*

ICP – *inferior cerebellar peduncle*

IV – *nucleus interpolaris, trigeminal*

MV – *motor nucleus, trigeminal*

MesV – *mesencephalic nucleus, trigeminal*

MCP – *middle cerebellar peduncle*

MRV – *motor root, trigeminal*

MVN – *medial vestibular nucleus*

OV – *nucleus oralis, trigeminal*

PD – *pyramidal decussation*

RVII, VIII, IX, X, XII – *root fibers of VII, VIII, IX, X, XII*

RF – *reticular formation*

SCP – *superior cerebellar peduncle*

SG – *substantia gelatinosa*

SV – *nucleus supratrigeminalis*

SpV – *spinal tract, trigeminal*

SRV – *sensory root, trigeminal*

SVN – *superior vestibular nucleus*

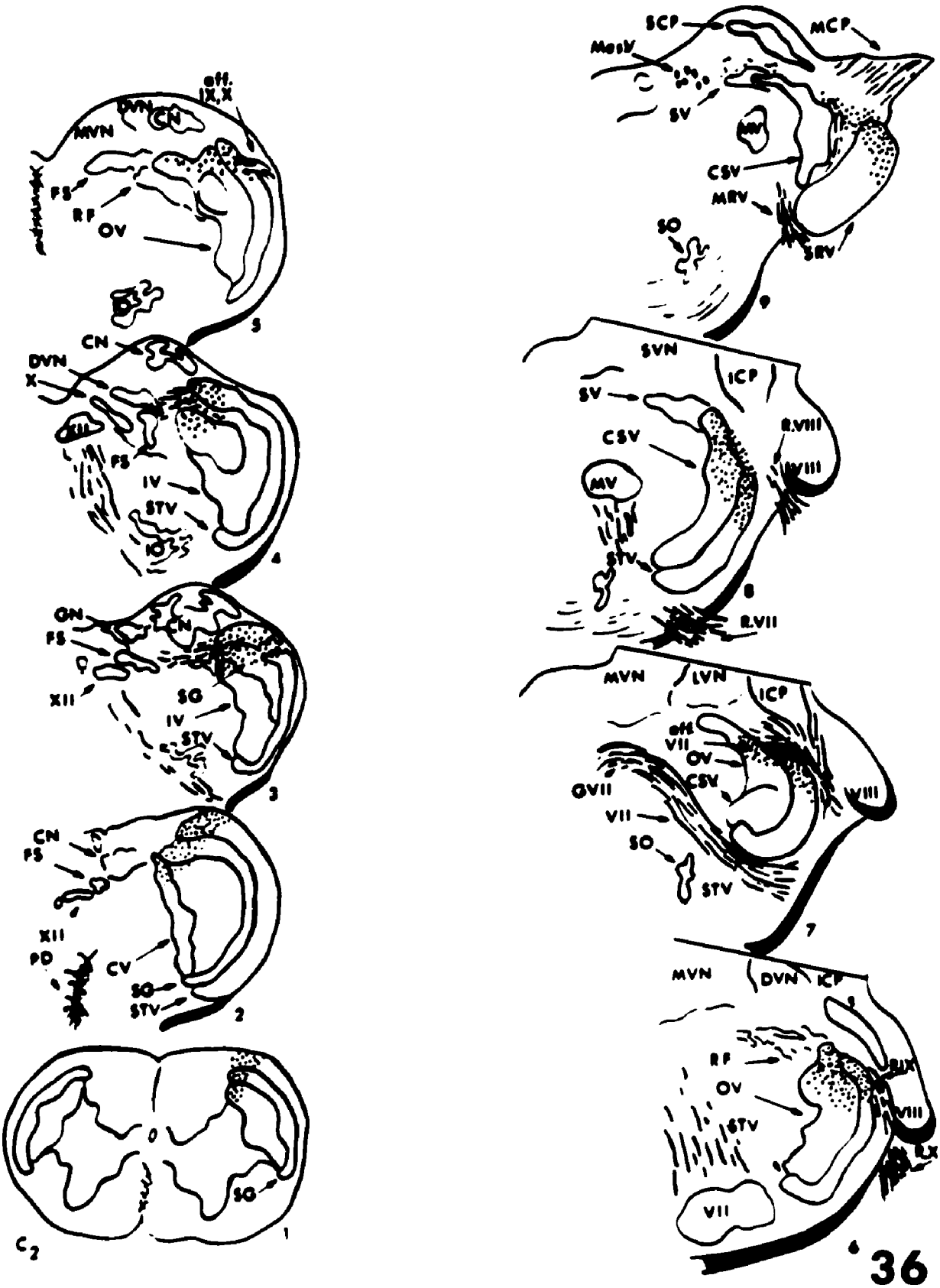
SCP
MCP
MesV
SV
CSV
MRV
SRV
SO
9
SVN
ICP
SV
CSV
R.VIII
MV
STV
8
R.VII
MVN
LVN
ICP
eff. VII
OV
CSV
GVII
VII
VIII
SO
STV
7
MVN
DVN
ICP
RF
OV
STV
VII
6
eff. IX,X
DVN
CN
MVN
FS
RF
OV
5
CN
DVN
X
FS
IV
STV
4
GN
CN
FS
XII
SO
IV
STV
3
CN
FS
XII
PD
CV
SO
STV
2
SO
1
C_2

36

FIGURE 37

NAUTA DEGENERATION PATTERNS IN THE ADULT RAT
FOUR WEEKS FOLLOWING MANDIBULAR FORAMEN NERVE SECTIONS

aff VII, IX, X – *afferent fibers of VII, IX, X*

CV – *nucleus caudalis, trigeminal*

CN – *cuneate nucleus*

CSV – *chief sensory nucleus, trigeminal*

DVN – *dorsal vestibular nucleus*

FS – *fasciculus solitarius*

GVII – *genu of VII*

GN -- *nucleus gracilis*

ICP – *inferior cerebellar peduncle*

IV – *nucleus interpolaris, trigeminal*

MV – *motor nucleus, trigeminal*

MesV – *mesencephalic nucleus, trigeminal*

MCP -- *middle cerebellar peduncle*

MRV – *motor root, trigeminal*

MVN – *medial vestibular nucleus*

OV – *nucleus oralis, trigeminal*

PD – *pyramidal decussation*

RVII, VIII, IX, X, XII – *root fibers of VII, VIII, IX, X, XII*

RF – *reticular formation*

SCP – *superior cerebellar peduncle*

SG – *substantia gelatinosa*

SV – *nucleus supratrigeminalis*

SpV – *spinal tract, trigeminal*

SRV – *sensory root, trigeminal*

SVN – *superior vestibular nucleus*

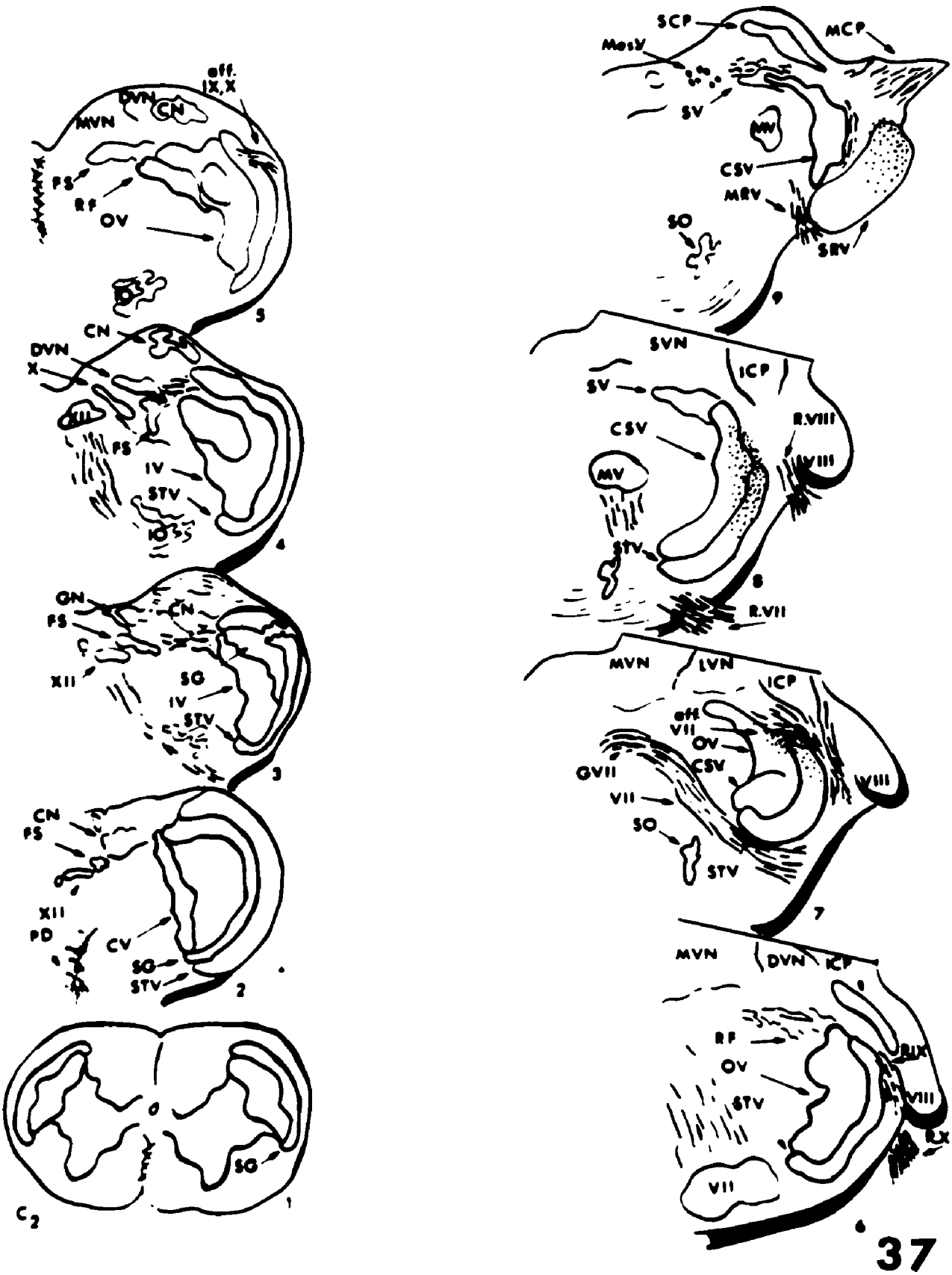
SCP
MCP
MesV
SV
MV
CSV
MRV
SO
SRV
9
SVN
ICP
SV
R.VIII
CSV
VIII
MV
STV
8
R.VII
MVN
LVN
ICP
aff
VII
OV
CSV
GVII
VIII
VII
SO
STV
7
MVN
DVN
ICP
RF
OV
STV
VII
6
aff.
IX,X
DVN
CN
MVN
PS
RF
OV
5
CN
DVN
X
XII
PS
IV
STV
IO
4
GN
CN
PS
XII
SO
IV
STV
3
CN
PS
XII
PD
CV
SO
STV
2
SO
1
C_2

37

FIGURE 38

NAUTA DEGENERATION PATTERNS IN THE ADULT RAT
SIX WEEKS FOLLOWING MANDIBULAR FORAMEN NERVE SECTIONS

aff VII, IX, X – *afferent fibers of VII, IX, X*

CV – *nucleus caudalis, trigeminal*

CN – *cuneate nucleus*

CSV – *chief sensory nucleus, trigeminal*

DVN – *dorsal vestibular nucleus*

FS – *fasciculus solitarius*

GVII – *genu of VII*

GN – *nucleus gracilis*

ICP – *inferior cerebellar peduncle*

IV – *nucleus interpolaris, trigeminal*

MV – *motor nucleus, trigeminal*

MesV – *mesencephalic nucleus, trigeminal*

MCP – *middle cerebellar peduncle*

MRV – *motor root, trigeminal*

MVN – *medial vestibular nucleus*

OV – *nucleus oralis, trigeminal*

PD – *pyramidal decussation*

RVII, VIII, IX, X, XII – *root fibers of VII, VIII, IX, X, XII*

RF – *reticular formation*

SCP – *superior cerebellar peduncle*

SG – *substantia gelatinosa*

SV – *nucleus supratrigeminalis*

SpV – *spinal tract, trigeminal*

SRV – *sensory root, trigeminal*

SVN – *superior vestibular nucleus*

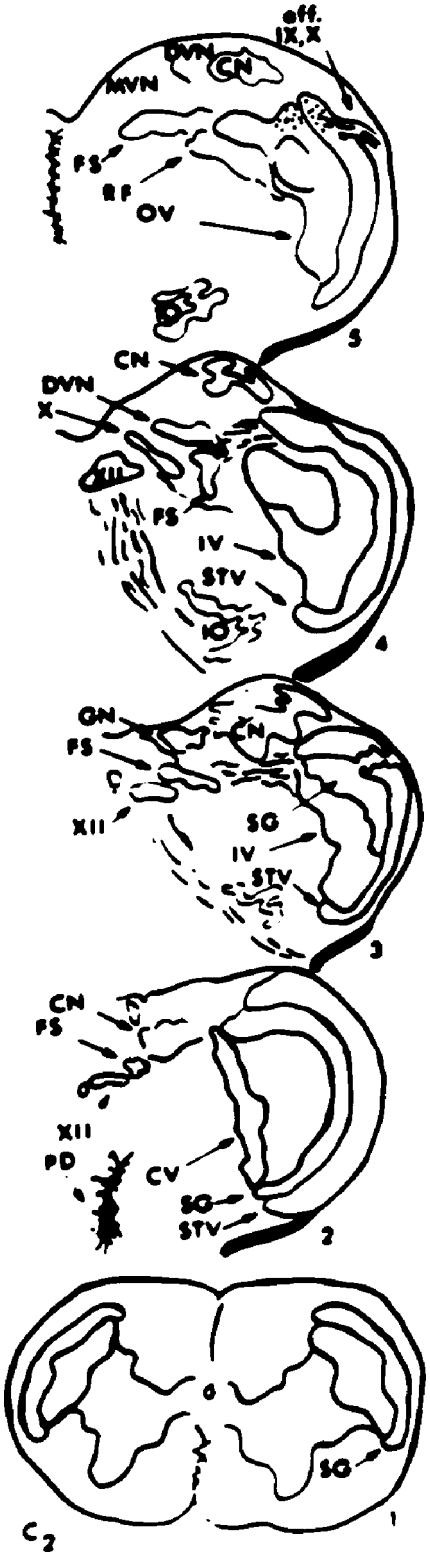
aff. IX, X
DVN
CN
MVN
FS
RF
OV
5
CN
DVN
X
PS
IV
STV
SO
4
GN
CN
FS
XII
SO
IV
STV
3
CN
FS
XII
PD
CV
SO
STV
2
SO
1
C2

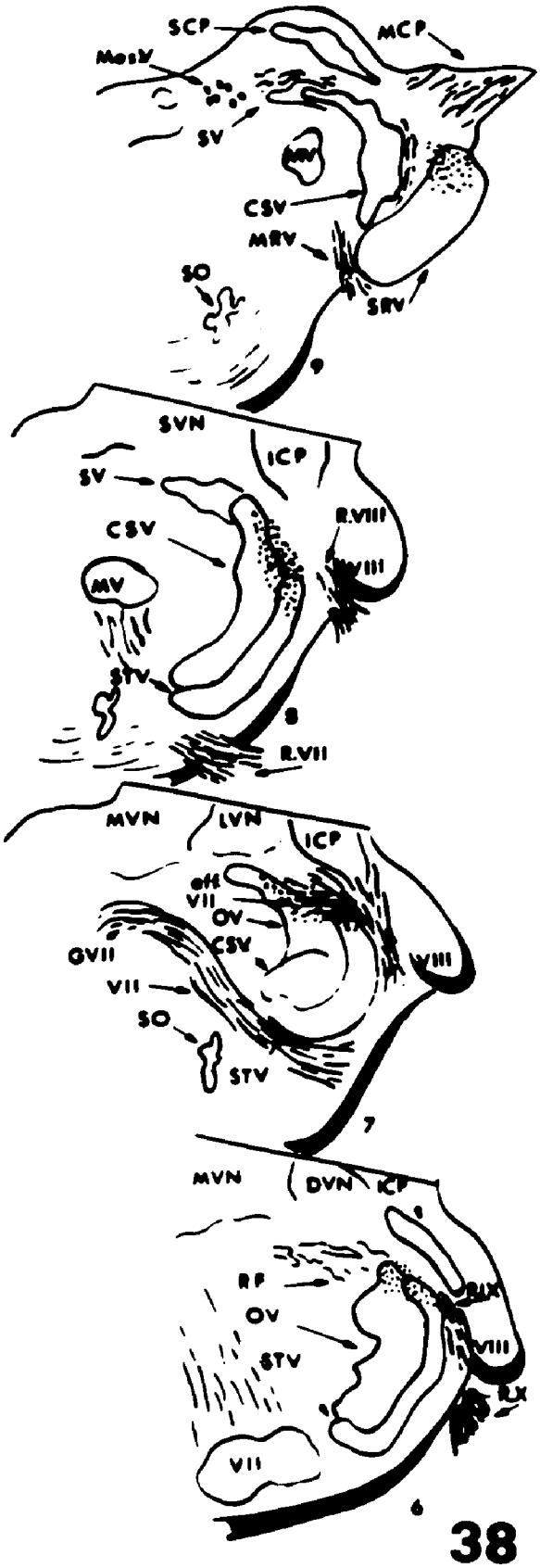
SCP
MCP
MotV
SV
CSV
MRV
SO
SRV
9
SVN
ICP
SV
R.VIII
CSV
MV
VIII
STV
8
R.VII
MVN
LVN
ICP
aff VII
OV
CSV
GVII
VIII
VII
SO
STV
7
MVN
DVN
ICP
RF
OV
STV
VIII
VII
6

38

FIGURE 39

MARCHI DEGENERATION PATTERNS IN THE ADULT RAT
TEN WEEKS FOLLOWING FORAMEN OVALE NERVE SECTION

aff VII, IX, X – *afferent fibers of VII, IX, X*

CV – *nucleus caudalis, trigeminal*

CN – *cuneate nucleus*

CSV – *chief sensory nucleus, trigeminal*

DVN – *dorsal vestibular nucleus*

FS – *fasciculus solitarius*

GVII – *genu of VII*

GN – *nucleus gracilis*

ICP – *inferior cerebellar peduncle*

IV – *nucleus interpolaris, trigeminal*

MV – *motor nucleus, trigeminal*

MesV – *mesencephalic nucleus, trigeminal*

MCP – *middle cerebellar peduncle*

MRV – *motor root, trigeminal*

MVN – *medial vestibular nucleus*

OV – *nucleus oralis, trigeminal*

PD – *pyramidal decussation*

RVII, VIII, IX, X, XII – *root fibers of VII, VIII, IX, X, XII*

RF – *reticular formation*

SCP – *superior cerebellar peduncle*

SG – *substantia gelatinosa*

SV – *nucleus supratrigeminalis*

SpV – *spinal tract, trigeminal*

SRV – *sensory root, trigeminal*

SVN – *superior vestibular nucleus*


aff. IX, X
DVN
CN
MVN
FS
RF
OV
3
CN
DVN
X
XII
FS
IV
STV
4
GN
FS
CN
XII
SO
IV
STV
3
CN
FS
XII
PD
CV
SO
STV
2
SO
1
C2

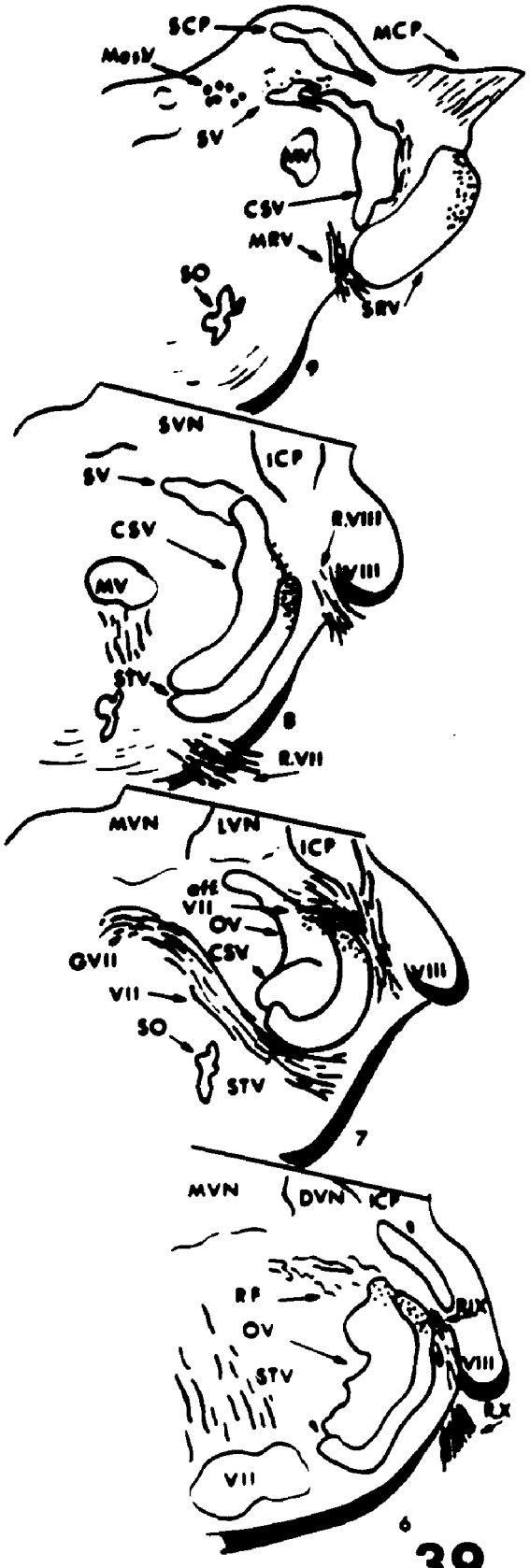
SCP
MCP
MesV
SV
CSV
MRV
SO
SRV
9
SVN
ICP
SV
CSV
R.VIII
VIII
MV
STV
8
R.VII
MVN
LVN
ICP
aff VII
OV
CSV
GVII
VII
VIII
SO
STV
7
MVN
DVN
ICP
RF
OV
STV
VII
6

39

FIGURE 40

MARCHI DEGENERATION PATTERNS IN THE ADULT RAT
TEN WEEKS FOLLOWING MANDIBULAR FORAMEN NERVE SECTIONS

aff VII, IX, X – *afferent fibers of VII, IX, X*

CV – *nucleus caudalis, trigeminal*

CN – *cuneate nucleus*

CSV – *chief sensory nucleus, trigeminal*

DVN – *dorsal vestibular nucleus*

FS – *fasciculus solitarius*

GVII – *genu of VII*

GN – *nucleus gracilis*

ICP – *inferior cerebellar peduncle*

IV – *nucleus interpolaris, trigeminal*

MV – *motor nucleus, trigeminal*

MesV – *mesencephalic nucleus, trigeminal*

MCP – *middle cerebellar peduncle*

MRV – *motor root, trigeminal*

MVN – *medial vestibular nucleus*

OV – *nucleus oralis, trigeminal*

PD – *pyramidal decussation*

RVII, VIII, IX, X, XII – *root fibers of VII, VIII, IX, X, XII*

RF – *reticular formation*

SCP – *superior cerebellar peduncle*

SG – *substantia gelatinosa*

SV – *nucleus supratrigeminalis*

SpV – *spinal tract, trigeminal*

SRV – *sensory root, trigeminal*

SVN – *superior vestibular nucleus*

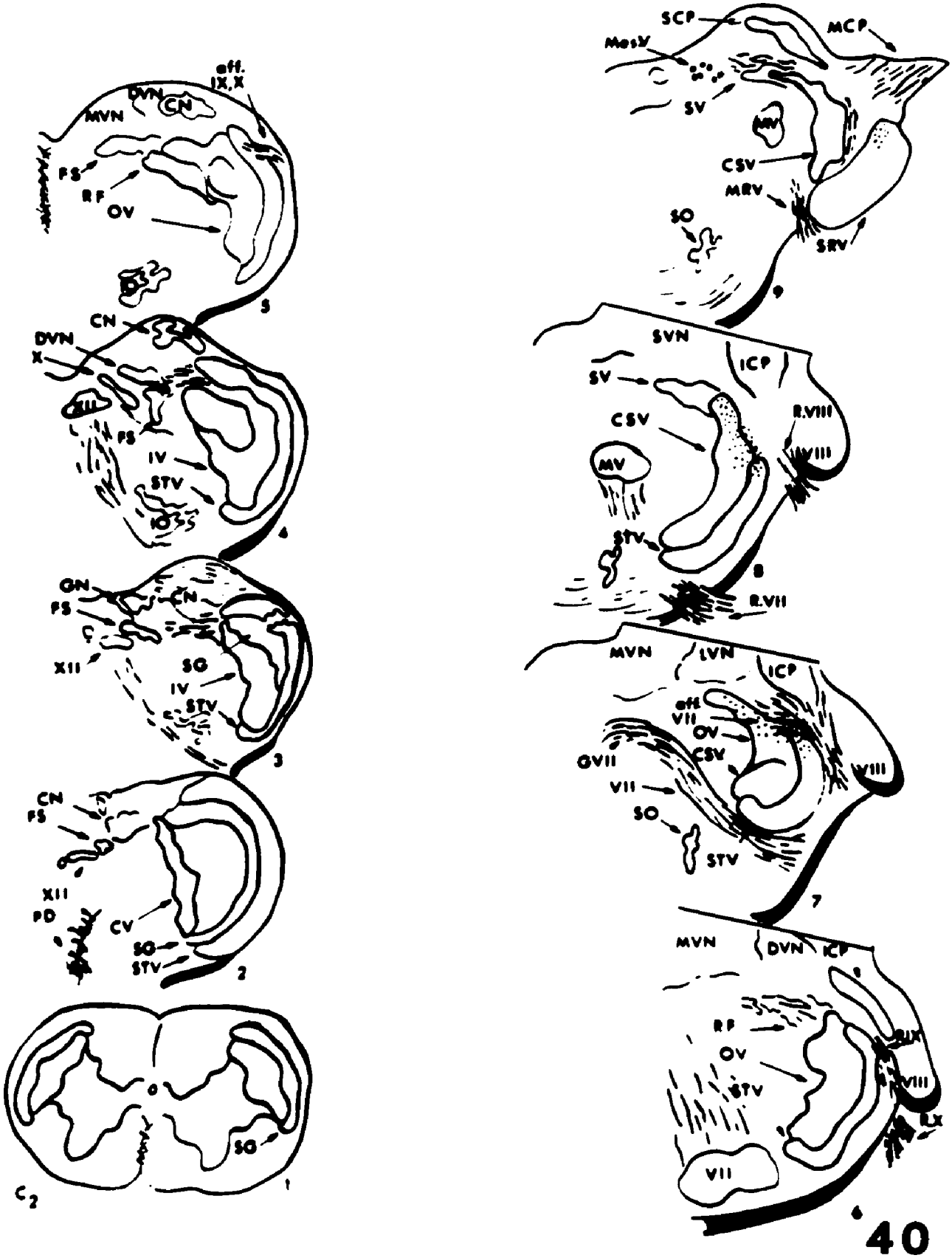
SCP
MCP
MesV
SV
MV
CSV
MRV
SO
SRV
9
SVN
ICP
SV
CSV
R.VIII
MV
VIII
STV
8
R.VII
MVN
LVN
ICP
eff VII
OV
CSV
OVII
VIII
VII
SO
STV
7
MVN
DVN
ICP
RF
OV
STV
VIII
VII
6
eff. IX, X
DVN
CN
MVN
FS
RF
OV
5
CN
DVN
X
XII
FS
IV
STV
4
GN
CN
FS
XII
SG
IV
STV
3
CN
FS
XII
PD
CV
SO
STV
2
SG
1
C2

40

FIGURE 41

MARCHI DEGENERATION PATTERNS IN THE ADULT RAT
TWENTY WEEKS FOLLOWING MANDIBULAR FORAMEN NERVE SECTIONS

aff VII, IX, X – *afferent fibers of VII, IX, X*

CV – *nucleus caudalis, trigeminal*

CN – *cuneate nucleus*

CSV – *chief sensory nucleus, trigeminal*

DVN – *dorsal vestibular nucleus*

FS – *fasciculus solitarius*

GVII – *genu of VII*

GN – *nucleus gracilis*

ICP – *inferior cerebellar peduncle*

IV – *nucleus interpolaris, trigeminal*

MV – *motor nucleus, trigeminal*

MesV – *mesencephalic nucleus, trigeminal*

MCP – *middle cerebellar peduncle*

MRV – *motor root, trigeminal*

MVN – *medial vestibular nucleus*

OV – *nucleus oralis, trigeminal*

PD – *pyramidal decussation*

RVII, VIII, IX, X, XII – *root fibers of VII, VIII, IX, X, XII*

RF – *reticular formation*

SCP – *superior cerebellar peduncle*

SG – *substantia gelatinosa*

SV – *nucleus supratrigeminalis*

SpV – *spinal tract, trigeminal*

SRV – *sensory root, trigeminal*

SVN – *superior vestibular nucleus*

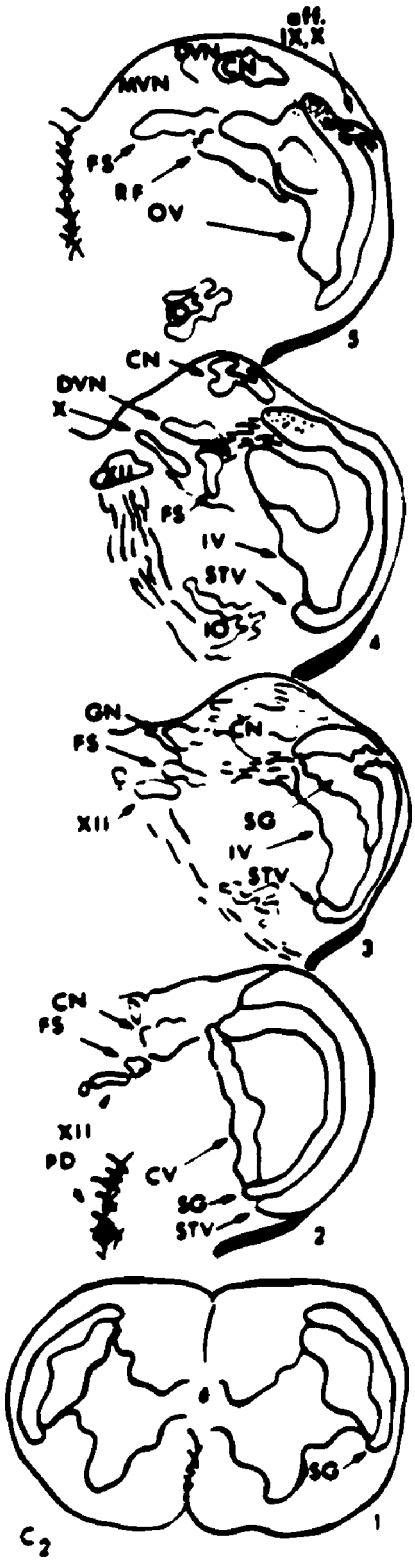
aff. IX, X
DVN
CN
MVN
FS
RF
OV
5
CN
DVN
X
FS
IV
STV
IO
4
GN
CN
FS
XII
SG
IV
STV
3
CN
FS
XII
PD
CV
SG
STV
2
SG
1
C2

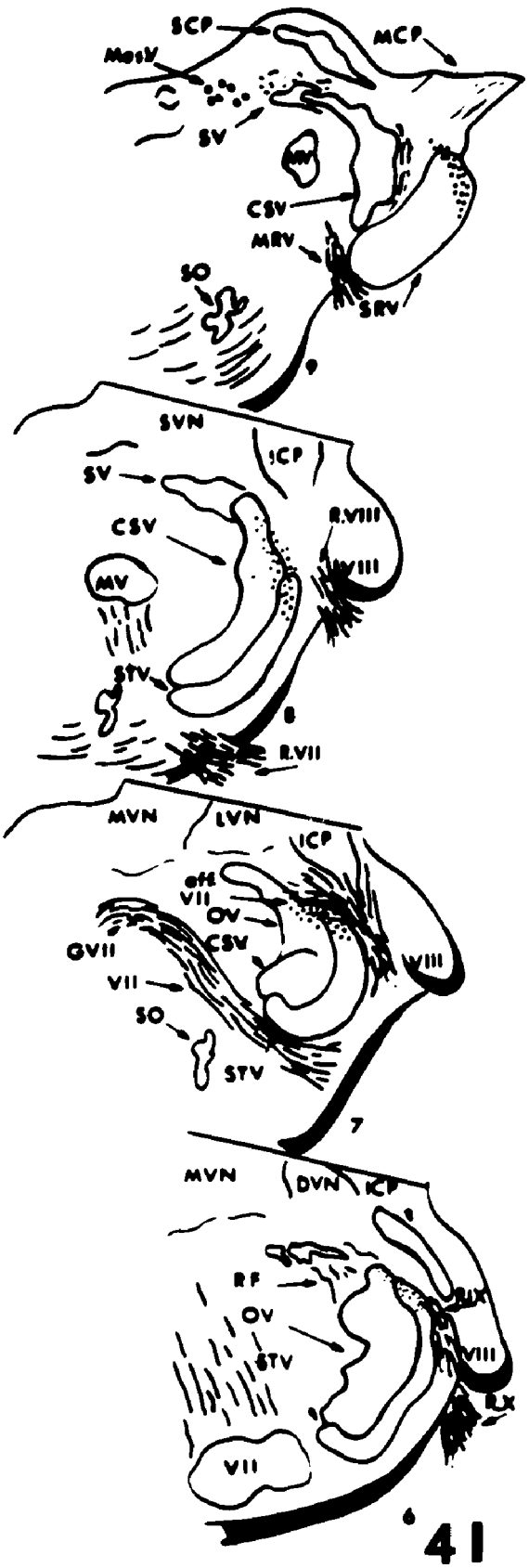
SCP
MCP
MesV
SV
CSV
MRV
SO
SRV
9
SVN
ICP
SV
CSV
R.VIII
VIII
MV
STV
8
R.VII
MVN
LVN
ICP
aff VII
OV
CSV
GVII
VII
VIII
SO
STV
7
MVN
DVN
ICP
RF
OV
STV
VIII
R.IX
VII
6

41

DISCUSSION

Historical Perspectives

The current investigations have sought to observe with a variety of methods and over a wide span of time the central effect of controlled peripheral nerve lesions on portions of a major somatosensory system, the trigeminal. There has been intense historical concern for learning about the variables of central nervous system reaction to injury for at least three basic reasons: 1) the ubiquity of peripheral nerves and their frequent location near body surfaces make them vulnerable to injury, 2) among the major body tissue types the nervous system has the poorest capacity to effect a healing response which returns the organism to an optimum functional state, and 3) permanent loss of nervous system elements is particularly debilitating and frequently life threatening to the organism.

Waller (1852) observed that the severed distal portion of a nerve invariably undergoes a degeneration. The larger fibers and their sheaths fragment most rapidly, releasing their Schwann cells to aid in the repair response. Marchi (Busch, 1898) had introduced a technique which selectively impregnated the products of Wallerian degeneration, as this reactive process had come to be called. The Marchi stain, in turn, became a productive and reliable experimental tool for the expanding fields of comparative anatomy and experimental pathology of the nervous system. A number of early investigators observed a Wallerian-like response in the proximal stump tissues immediately adjacent to the nerve lesion. Cajal ('28) named this process "traumatic dgeneration" and stressed that it usually did not proceed initially further central than the next node of Ranvier and later no further than the next nerve collateral. However, a search for a mechanism by which a peripheral nerve lesion could cause a reaction in a distant cell body had been prompted by the classic observations of Nissl (1892); division of the peripheral facial nerve trunk resulted in a gross cell swelling, nuclear eccentricity and a dissolution of intracytoplasmic methylene blue bodies. The Nissl reaction, also known as central chromatolysis or the axon reaction, has continued to challenge investigators to explain its mechanisms and peculiarities. For example, axon

interruption of spinal ganglion cells distal to the ganglion leads to typical chromatolysis, but amputation central to the ganglion by posterior root severence is followed by no apparent morphologic changes in the ganglion cells (Bucy, '28, Bodian and Mellors, '45, and Carmel and Stein, '69). The Nissl reaction has been looked upon more recently as an anabolic attempt by the cell to reconstitute its resected cytoplasmic processes (Brattgard, *et al.*, '58, and Torvik and Heding, '69). But it is evident that the cell may sometimes fail in these attempts to compensate for cytoplasmic loss; in these cases necrobiosis would result. Gudden (1870) had demonstrated that the cell body retrograde reaction may be one of rapid ganglion cell atrophy and eventual disappearance (Gudden atrophy). This work has been confirmed more recently by Brodal ('40), but has been primarily demonstrated in the central nervous system and among young animals. Van Gehuchten ('03) believed that the retrograde chromatolytic reaction, even in the peripheral nervous system, could be a prelude to disintegration and loss of the cell body. He further postulated that in such a situation a degeneration would proceed centrifugally from the damaged cell along the cell processes. This concept of retrograde degeneration is in direct contrast to the centripetal traumatic degeneration supported by Cajal and others. Van Gehuchten's proposal has been largely neglected until more recently when support has come from a variety of sources. Cowan, *et al.*, ('61) have demonstrated a degeneration which spreads centrifugally from the mesencephalon along the isthmo-optic tract following eye enucleation in birds. Grant and Aldskogius ('67) have similarly demonstrated with Nauta technique that section of the hypoglossal nerve in the neck of kittens results in a degenerative response which spreads from the cell body out along both dendrites and axon processes. Kirkpatrick ('68) has confirmed these findings for the hypoglossal nucleus of the rat with electron microscopic techniques. Whatever the mechanism of retrograde cell necrosis, a number of investigators agree that this process is delayed in onset over the direct Wallerian form of degeneration (Beresford, '65).

In the following discussion many of these classic concepts that relate to the retrograde response to injury will be considered in terms of the findings in the present series of experiments.

Retrograde Necrobiosis

This study has supported the central hypothesis that extracranial trigeminal nerve sections can result in necrobiosis of ganglion cells with consequent degeneration of peripheral and central processes. The major supportive findings include: 1) the appearance of histologically disintegrative and fragmented trigeminal ganglion cells over a wide post-operative interval, 2) an apparent progressive reduction in ganglion cell numbers and their replacement by glial elements, 3) a demyelination within the descending tract of trigeminal as demonstrated by a standard myelin stain, and 4) the demonstration of central nerve process degeneration within the brain stem by two different nerve degeneration stains.

There has been little experimental evidence that would have led to a prediction of these findings. Strassburg ('67) studied the trigeminal ganglion changes following dental extractions and mandibular fractures in rabbits. He concluded that the trigeminal ganglion cells made a complete recovery following these lesions. These studies, however, did not investigate the ganglia during the one to ten week post-operative period during which time neuron disintegration was observed in the present studies with rats and cats. In addition, there was no quantitative evidence given that at long post-operative intervals the neuron cell populations were not reduced in number. In an extensive study Torvik ('56) produced massive brain stem trigeminal degeneration by avulsing intracranially the peripheral processes of the trigeminal nerve in rats. However, the nature of the lesion in these experiments makes it difficult to draw direct correlations to the extracranial nerve section lesions reported in this paper. Bielschowsky ('32) has stressed the important variable of the type of nerve lesion. He has indicated that a simple nerve transection is less likely to produce a central cell necrosis than avulsion of the nerve. Carmel and Stein ('69) avoided the type of lesion variable and intracranially sectioned the peripheral nerve processes of trigeminal in one adult monkey. These investigators were unable to detect central brain stem degeneration with the Nauta technique applied at five days post-operative mandibular nerve section. However, Van Gehuchten ('03) had emphasized that retrograde degeneration in the spinal nerves appears after a minimum post-operative delay of fifteen days. This is also consistent with the findings in the current experiments with adult rats and cats. It appeared that the central trigeminal degeneration following peripheral lesions was subject to a longer post-operative lag period than usually observed in classical Wallerian degeneration.

Ramon Y Cajal ('28) had stressed that a "traumatic degeneration" extends centripetally on the proximal nerve stump from the point of nerve lesion. He believed, as did Lance ('54), that this degeneration at first progressed no further centrally than the next node of Ranvier, and later no further centrally than the next nerve collateral. However, Cajal also described a population of larger nerve fibers that did not conform strictly to these stated boundaries and were found to degenerate much further centrally. In the current experiments, Kluver-Barrara staining revealed a demyelination of the peripheral mandibular nerve which was seen most distinctly at one and two weeks following foramen ovale nerve section. This degeneration was observed within the trigeminal ganglion although the initial peripheral segment of approximately one hundred micra was not degenerate. Therefore, it seems likely that this degeneration was a "traumatic degeneration" of the type described by Cajal and that it had progressed centripetally from the point of lesion at foramen ovale to nearly reach the ganglion cells.

A second form of degenerative response which appeared to be physically separate from the process of traumatic degeneration was observed within the ganglia and centrally projecting nerve processes. This process was one of ganglion cell necrobiosis beginning within the first week and one-half following both foramen ovale and mandibular foramen nerve sections. In addition, the central nerve processes were subsequently seen to degenerate in a pattern which spread centrifugally from the necrotic ganglion cells into and caudally down the brain stem trigeminal complex. This form of degeneration conforms to the descriptions of Van Gehuchten ('03) concerning a retrograde necrotic reaction which spreads out from the cell body as a secondary peripheral degeneration. The recent observations of Kirkpatrick ('68), and Grant and Aldskogius ('67) have shown that the centrifugal pattern of degeneration can also apply to the central dendritic processes of the hypoglossal nerve. The observations in the present study are unique, however, in that the centrifugal degeneration spread was observed in a sensory ganglion and it was present in adult as well as young animals. In addition, the nerve lesions of the present experiments were localized much further peripherally than the position of lesion that was formerly thought necessary to produce ganglion cell necrobiosis (Geist, '33, and Cajal, '28).

The Cell Type Variable

In the current experiments it was apparent that not all cells and cell processes reacted with equal severity to the peripheral nerve lesions. The larger ganglion cells constantly displayed a more profound chromatolysis and a greater frequency of disintegration than the smaller cells within the same ganglia. An even more precise measure of a selective reactive response to trauma was demonstrated by the much greater density of chief sensory nucleus Nauta and Marchi degeneration as compared to degeneration in the descending tract nuclear areas. The observations in the trigeminal ganglion and the brain stem are probably related since it is known that the chief sensory nucleus predominantly receives the central fiber processes of the larger ganglion cells and the more caudal brain stem trigeminal areas receive the finer fibers from the smaller ganglionic cell bodies (Windle, '26). A number of previous authors have recognized that there is considerable difference in both the rate and degree of reaction to trauma by various neurons. Beresford ('65) stated that the motor systems are generally less resistent to the effects of trauma than the sensory systems. Cammermeyer ('68) had noted that "pink" neurons of the rabbit seventh nerve nucleus reacted more violently to lesions than the "blue" neurons within the same central nucleus. K. Smith ('61) also stated that the larger dorsal root ganglion cells demonstrated more extensive electron microscopic degenerative changes. In addition, trigeminal cells exhibit a differential susceptibility to such diverse sources as systemic alcohol (Sauerland, '70), various chemicals (Gabbiani, '66, and Sasa, *et al.*, '69), viral infections (Johnson and Mims, '68, and Kahn, '67), and fungus infections (McKinney, *et al.*, '68). These selective effects have been well documented but poorly understood.

It is possible that the differences in trigeminal cell reactivity to trauma may ultimately be explained in terms of morphologic and developmental characteristics. Hamburger ('61) and Johnston ('66) have shown that the trigeminal ganglion cells are derived from both neural crest and epidermal placode elements. However, direct correlations have not yet been made between the varied cell origins and adult ganglion cell morphologic differences. As Dixon ('63) has pointed out, there are great morphologic variations within the trigeminal ganglion cell population. For example, the ganglion cell diameters may range from fifteen to one hundred microns in size and there is a higher population of large cells in the trigeminal

ganglion than in other cranial ganglia (Carmel and Stein, '69). Dixon ('63) described two distinct morphologic types within the trigeminal ganglion; a dark cell with abundant ribonucleoprotein granules and a pale cell with more discrete granular inclusions. Two similar types of light and dark cells have been described in the spinal ganglia by Dawson, *et al.*, ('55). Some of the smaller ganglionic cells have been implicated in visceral afferent activities (Crosby, Humphrey and Lauer, '62) or have been described as postganglionic parasympathetic cells. Carmel and Stein ('69) have also drawn attention to a collection of cells which they call the "accessory trigeminal ganglion" which is attached to the distal portions of the trigeminal ganglion close to the mandibular branch. The cells are autonomic in type and personal observations (unpublished) indicate that fibers from these cells wrap around adjacent arteries and rejoin the peripheral mandibular nerve at a number of levels.

It is possible that the differences in individual cell reactivity to trauma are somehow related to intrinsic cell metabolic differences. Most investigators now look upon the chromatolysis response as an outward expression of the cells attempts to manufacture great amounts of structural protein (Brattgard, *et al.*, '58, and Torvik and Heding, '69). Because the transected peripheral cytoplasm of neurons may exceed the cell body by over a thousand times (Singer, '52), these demands for new proteins may be extreme. It appears that in some cells either the mechanisms for protein production cannot meet the demands, or the means of delivering the formed substances to the areas of need are deficient. These cells might undergo an exhaustion of energy stores in the vain attempt to reestablish the lost cytoplasm; vital cell respiratory and osmotic balances then could not be maintained and irreversible cytoplasmic shock would result. There is controversial evidence that this does happen on a differential cellular basis. Hartmann ('54) described mitochondrial swelling as a **sequel** to axon section and K. Smith ('61) indicated that the larger dorsal root cells undergo more profound mitochondrial reaction to injury. Koenig ('69) has also implicated the role of the mitochondria in the response to fluorocitrate intoxication. Another possible cell metabolic difference that may be important to the differential trauma reaction has been emphasized by Jilek, *et al.*, ('64). He stated that younger neurons and phylogenically more recent neurons are better able to survive hypoxic insult by more efficient use of endogenous glycogen reserves as a substrate for anaerobic glycolysis. It appears likely, therefore, that significant differences exist between cell types with respect to respiratory and energy producing

capacities as well as to the capacity to synthesize proteins. These differences probably are key factors in producing the variation in response to injury that is observed between cell types.

There may be reasons other than intrinsic cell body metabolism why individual cells react differently to nerve trauma. The cell bodies are probably greatly dependent on the integrity of peripheral processes and associated glial cells to provide the substrate for both energy production and protein manufacture (Oderfold-Nowak, and Niemierko, '69). In addition, the cell processes probably exert a "neurotrophic" or supportive influence on the cell body. The better known trophic influence by the cell body on its peripheral processes is probably chemical in nature and appears to be exerted by means of a centrifugal flow of axoplasmic molecules (Weiss, '55). More recent experiments have shown that the axoplasmic flow is bidirectional with substances both leaving and arriving at the cell body (Lubinska, '64). This reverse flow phenomenon provides a physiologic basis for the concept of a "reverse neurotrophic influence". There is strong experimental support for this concept. An increase in the peripheral field of innervation by means such as limb grafting results in a hypertrophy and excessive development of spinal ganglia (Detwiler, '20). Similarly, limb extirpation in the chick results in massive cell atrophy and degeneration (Hamburger and Levi-Montalcini, '49). Because the reverse trophic effect appears to be proportionate to the amount of peripheral nerve cytoplasm, it follows that removal of relatively greater amounts of peripheral nerve cytoplasm would cause a proportionately greater loss of trophic effect upon the cell body. It might be expected, for example, that severing the fibers of the mental nerve at foramen ovale level would induce a more violent change in the ganglion cells than a comparably placed lesion of the shorter auricular branches. Observations in the current experiment gave support to this supposition; the cell bodies of the inferior alveolar nerve reacted more violently than surrounding cell bodies of shorter nerves following nerve section at foramen ovale.

There is an additional implication that the reverse axoplasmic flow concept is relevant to nerve lesion responses. Nakai ('56) has described a pinocytosis and ascent of large molecular droplets which occurs at cut fiber ends in tissue culture. If this process were translated to the nerve section process in vivo, it would provide a possible mechanism whereby toxins and potentially destructive substances such as viruses, chemicals, and lysosomes could have easy access to the nerve cell bodies by entering the cut nerve end.

It is evident that a wide range of morphologic, developmental and metabolic features exist within the trigeminal ganglion. It is not surprising that the stresses placed on these cells by demands for structural protein production and the loss of peripheral trophic influences would also have a wide range of effects among the ganglion cells.

The Age Variable

In the current investigations the trigeminal ganglia of young rats which had undergone nerve sections appeared to be lacking in overall cell numbers. The residual cells were uniformly atrophic and did not display classic chromatolytic changes. It also appeared that the spread of degeneration into the brain stems of young rats began after a shorter post-operative interval than in the adult rats. Gudden (1870) had stated that young neurons are more likely to disappear in response to peripheral nerve section than the comparable adult neurons. In fetal material it has been demonstrated that there is a near total loss of cells from peripheral neurectomy (Hess, '56). The cell disappearance in the very young has been described as extremely rapid and lacking in the classic Nissl reaction. Lavelle and Lavelle ('58 and '59) have offered a partial explanation for the difference between the adult and the immature susceptibility to nerve injury. They have demonstrated, for the seventh nerve of the hamster, that there is a very close correlation between the type of reaction to injury that is observed and the developmental state of the nucleolar apparatus. In the youngest specimens when the nucleoli are not formed into a single organelle the nerve cell reacts to peripheral neurectomy by nucleolar disintegration and cell death without cytoplasmic change. Shortly following the maturation of the nucleolus, however, a rather abrupt change occurs in the reaction to injury. The nucleolus remains intact and the cytoplasmic Nissl reaction becomes the dominant feature. Brachet and Chantrenne ('56) have confirmed that the Nissl substance is reformed during the chromatolysis reaction from ribose nucleoprotein of the nucleus which is in turn dependent upon nucleolar desoxyribose nucleoprotein patterns. In the current studies binucleolate cell forms appeared to be associated with both young and adult cells that were in the process of disintegrating following extracranial nerve lesions. Rand and Courville ('46) had found binucleate cells in the cortices of human brain trauma cases. They concluded that binucleation was a stage in the disintegration of cells. The division of the nucleolus may be a final desperate attempt on

the part of the cell to compensate for extreme demands for nucleoprotein production. In any event, the nucleolus appears to be a key factor in the nerve cell's capacity to resist necrobiosis following peripheral damage.

The Species Variable

In the present series of experiments it appeared that the adult cat was more resistant to the effects of extracranial trigeminal nerve section than the adult rat. Previous investigations have stressed the vast differences between different animal types in the resistances of their nervous systems to trauma. However, upon closer inspection it appears that it is the regenerative capacities, not the resistance to degeneration, that sets these species apart. The Newt compensates for the transection of its spinal cord by a migration and transformation of ependymal cells to constitute a new cord (Piatt, '55). Among the fishes a new optic nerve may be restored through cell division (Sperry, '48). In reptiles and birds it appears that sensory deficit may receive compensation by hypertrophy of residual cells (Hamburger, '55). The mammals, unfortunately, do not display these dramatic healing responses to a meaningful degree. For example, no mammalian form, adult or embryonic, has shown the capacity to react to a traumatic stimulus by cell division and replacement of lost neurons (Hess, '56). There have been few studies which have compared the susceptibility of various species to sensory nerve damage. Cammermeyer ('68) reported that the mouse chromatolytic response is more severe than the rabbit, and Tower ('43) commented that the cat is much more resistant to ventral root section than man. Because no controlled study has compared the primate response to other mammalian forms, direct cross species comparison effects from sensory nerve damage may be misleading at this time.

A second major species difference in the present series of experiments related to the relative amounts of degeneration observed in the chief sensory nuclei. It appeared that the ratio of degeneration between the more dense chief sensory nucleus and the less dense descending tract was greater in the cat than in the rat. Windle ('26) found in a study of the projection of the trigeminal roots on the brain stem centers that there were three types of projection neurons. In general, the small ganglionic neurons send small central fibers into the caudal brain stem. The largest neurons project large fibers predominantly into the chief sensory nucleus. Other cells divide and send larger branches into the chief

sensory nucleus and smaller fibers into the descending tract. Crosby and Yoss ('54) have demonstrated that the proportions of unbranched and branched fibers that enter the chief sensory nucleus vary greatly between species. However, both the relative number of fibers that enter the chief sensory nucleus and the size of the nucleus correlate closely with the presence and quantity of encapsulated tactile corpuscles (Boeke, '25). Therefore, the observation in the present experimental series that there was relatively more degeneration in the chief sensory nucleus in the cat than in the rat is probably a reflection of a true morphologic species difference.

A final species difference that may have been operative in the current experiments relates to the gross dimensions of the trigeminal complex. Species differences may exist between the ratios of intracranial to extracranial nerve lengths, the relative distances between the ganglion, foramen ovale and mandibular foramen, the fiber spectra of nerve diameters, and the degree of nerve branching. Most of these statistics are not available. However, this type of information will have to be provided before extensive species comparisons can be made.

Somatotopic Patterns of the Trigeminal Complex

Observation of trigeminal ganglia and the central trigeminal complex following peripheral nerve lesions revealed highly organized and consistant somatotopic relations. The mandibular division cell bodies were found to be localized ventrally and posteriorly within the ganglion. In addition, the inferior alveolar nerve cell bodies were found to be the most ventral among the mandibular cells with these neurons located predominantly at the ventral surface adjacent to the sphenoid bone. These findings, based on chromatolysis patterns, are in basic agreement with recent neurophysiologic tracing studies (Kerr and Lysak, '64). Mechanoreceptor recordings have revealed that the more dorsal portions of the ganglion are populated by cells innervating peripheral trigeminal fields such as the forehead and pinna whereas the ventral ganglionic cells are related to more discrete fields in or near the oral cavity (Beaudreau and Jerge, '68). The ventral position of these peroral-related cells takes on added significance in view of one of the major theories of tic douloureux etiology. Kerr ('63) has supported a concept of "cryptogenic" neuralgia in which structural defects

in the skull overlying the internal carotid artery allow the artery to pulsate against the ventral surface of the trigeminal ganglion. The known preponderence of peroral trigger zones for this neuralgia (Dalessio, '69) and the ventral localization of the appropriate nerve cells both add impetus to this argument.

A functional somatotopic division has been proposed for the human trigeminal sensory root by Dandy ('66). He proposed that the sensory root adjacent to the pons separates into a caudal portion which projects exclusively into the descending tract nuclei and a rostral accessory segment of the root which terminates in the chief sensory nucleus. However, Emmons and Rhoton ('68) have disproved this organization for the monkey. Using selective rhizotomy procedures they found that the most rostral portion of the sensory root adjacent to the motor trigeminal root corresponds to the ophthalmic division and projects both to chief sensory and descending tract regions. A similar orientation and somatotopic segregation of sensory root fibers was found in the rats and cats of the current experimental series. The mandibular division fibers appeared to be distinctly located in the dorsal and lateral portions of the sensory root approaching the pons and the inferior alveolar nerve fibers occupied the most dorsal portion of the mandibular fiber area. In the current experimental series it was demonstrated that the mandibular ganglion cells concentrate ventrally and laterally within the ganglion. It seems likely that the central fibers given off by these cells rotated laterally to assume their dorsal position within the sensory root as it entered the brain stem.

There have been several excellent studies which have mapped the somatotopic patterns of the central trigeminal complex by single unit recordings (Kerr, *et al.*, '68). A unique opportunity to confirm these findings has been offered by the present series of experiments. The degeneration patterns following foramen ovale nerve section indicated that the mandibular division occupies a constant dorsal position within the central trigeminal complex throughout all of the tract and subnuclear areas. Electrophysiologic studies have confirmed for a variety of species that the mandibular division assumes the most dorsal position constantly throughout the trigeminal complex; the ophthalmic division lies ventrally and the maxillary division is interposed (Kerr, *et al.*, '68 and Darian-Smith, *et al.*,'65). The inferior alveolar nerve position as determined following inferior alveolar nerve section in the present series appeared to localize in the most dorsal and medial portions of the mandibular

area, immediately adjacent to the upper trunk tactile sense distribution area in the lower medulla. These findings confirm the somatotopic mapping that Nord ('67) described through electrophysiologic techniques. He indicated that the chin and oral projection regions rest in a backwards position upon the upper trunk within the lower brain stem.

The absence of degeneration in certain brain stem areas in the rats and cats of the present experiments is of interest. There was no evidence of primary afferent degeneration with Nauta or Marchi techniques within cerebellar peduncles, nucleus supratrigeminalis, within fasciculus solitarius, reticular formation or approaching any motor nuclear areas. Nor was there any evidence of fibers that crossed the midline.

Woodburne ('36) had described direct trigeminal-cerebellar fibers projecting from the sensory root and mingling with the spinocerebellar tracts in amphibians, reptiles, birds, and mammals (mouse). Although other authors have supported these observations (Brodal, '54), many investigators have denied their existence (Astrom, '53), and have been unable to demonstrate them experimentally (Torvik, '56). However, Cupedo ('65) has provided an observation which may explain the apparent conflict of opinions. He has shown that cells of the mesencephalic nucleus, particularly in the rodent are frequently located in the anterior medullary velum and the superior cerebellar peduncle fiber bundles. He has speculated that their location in these positions reflects their participation in the cerebellar coordinating influence on feeding movements. Therefore the observations of Woodburne ('36) and Brodal ('54) could have been due to these aberrant mesencephalic fibers. It also might be expected that these fibers would not react to nerve lesion experiments such as those of Torvik ('56) and those of the current experiment in the same fashion as the primary afferent ganglion fibers.

In the current experimental setting, the absence of degeneration within the nucleus supratrigeminalis was consistent with the degeneration studies of Torvik ('56) . Jerge ('63) has demonstrated that a considerable degree of integration of trigeminal masticatory reflexes occurs within this nucleus. These findings, along with the position of the nucleus supratrigeminalis between mesencephalic and motor trigeminal nuclear groups, has led to the speculation that this nucleus is a collection of interneurons active in the integration of trigeminal motor reflex activities.

Primary trigeminal fibers which cross the midline have been described in the caudal medulla of lower vertebrates (Woodburne, '36), and Torvik ('56) found a moderate number of trigeminal fibers which cross the midline in the spinal cord of the rat and appear to terminate in the opposite dorsal horn. Smith ('67) used evoked potentials in monkeys and cats to demonstrate bilateral projections of proprioceptive input to mesencephalic trigeminal nuclei, and Dixon and Kaley ('68) reported bilateral mesencephalic chromatolysis effects from unilateral trigeminal ganglion lesions. Various reports have also demonstrated primary afferent trigeminal fibers passing to nontrigeminal areas such as the solitary tract (Astrom, '53), the dorsal part of the reticular formation (Torvik, '56), the external cuneate nucleus (Liu, '55) and passing directly to motor trigeminal (Astrom, '53), facial and hypoglossal nuclei (Koelliker, 1891). All of these nontrigeminal fiber projections are located in more caudal brain stem regions and are derived from small unbranched ganglion cells (Windle, '26). These projections develop early *in utero* and are known to establish the earliest gross reflex connections of the embryo (Humphrey, '64). A preponderance of these more caudal trigeminal connections is also known to be typical of more primitive vertebrates such as the cyclostome and tailed amphibians (Crosby and Yoss, '54), and Jilek, *et al.*, ('64) have stressed the concept that phylogenetically older portions of the central nervous system are more resistant to traumatic insult.

In the current experiments the more severe chromatolysis and dense central degeneration was concentrated in the larger ganglion cells and their central projections to rostral brain stem areas. The degeneration density appeared to diminish progressively at more caudal levels. In addition, no degeneration was observed in the nontrigeminal projection areas discussed above, nor were there any degenerate crossed fibers. Each of these observations is consistent with the proposal that smaller cell projections are more resistant to extracranial trauma than the larger cell projections.

Physiologic Considerations

Johannes Muller in 1862 formulated the "law of specific irritability" in which he suggested that there are specific receptors that give rise to sensations peculiar to each of them. This concept has been extended by others to include a straight-line specificity of fiber paths which also carry specific sensibilities to equally specific brain "centers". Thus

there are heat, cold, touch and pain receptors, tracts, and centers. There is ample experimental support for this concept. Heinbecker, *et al.* ('35) were able to correlate fiber size directly with the sensory stimulus applied at the end of an exposed human amputation stump, and Gasser ('35) demonstrated that local anesthetics block small fiber transmission of painful stimuli before they block tactile sensation. It has also been shown that pain may also be experienced with isolated small fiber activation after large fibers have been blocked (Collins '60). In the trigeminal system the results of the classic tractotomy operation of Sjoqvist ('38) for facial pain control are frequently cited as evidence for the specificity of pain within the descending tract of trigeminal. Evidence has also accumulated that seems to negate the doctrine of specificity. For example, it has been shown that the facial pain eliminated by the descending tractotomy may slowly return although the tract does not regenerate (Porter, *et al.*, '66). Also, the human cornea is known to contain only free nerve endings and small afferent fibers. Nevertheless, these receptors are responsive to warmth, cold, touch and pain (Lele and Weddell, '56). Weddell ('41) has gone to the extreme of denying the specificity of any receptor or any other more central neural structure. He has stressed in his "pattern theory" that sensory perception depends only on spatial and temporal patterns of nerve impulses. Most authorities in this field now agree that some features of both the specificity and pattern theories of somatosensory perception are correct. Probably some specificity of receptors, tracts, and areas exist in that they respond to "preferred" types of stimuli. However, the patterns of impulses that are transmitted probably greatly influence the actual perception of sensation.

The more recent theories of somatosensory perception have relied heavily on proof that a great amount of impulse modification takes place at the synaptic terminals at many levels of the system. Much of the work that has been accomplished in this area has concentrated on the substantia gelatinosa of the spinal cord and in the homologous nucleus of the descending **trigeminal tract (Crosby and Yoss, '54).** One of the recent breakthroughs has been the demonstration of afferent "surround inhibition" (Eccles, *et al.*, '63). Darian-Smith ('65) has demonstrated a "trigeminal tract" reflex in which a presynaptic inhibition of primary trigeminal afferent fibers may occur following stimulation of other surrounding trigeminal areas. It has been suggested that the large afferent fiber systems are particularly

active in exerting a presynaptic inhibition of the afferent smaller fibers (Melzack and Wall, '65). This concept forms the basis of a new theory of pain mechanisms. In this theory any situation which could produce an abnormal balance between the large and small nerve components would have the potential for producing abnormal pain states. Any destructive process, therefore, which eliminates the larger fibers out of proportion to the smaller fibers has the effect of releasing the smaller fibers from inhibition and allowing excessive transmission to pass from these fibers. There is ample clinical-pathological proof for this theory. For example, herpes zoster is known to result from a viral invasion and selective destruction of the largest trigeminal ganglion cells (Noordenbos, '59). The post-herpetic pain syndrome has been explained, therefore, on the basis of the resulting trigeminal disproportion of sensory elements. Similarly, the pain of tabes dorsalis has been explained on the basis of the removal of large afferent fibers that enter the dorsal columns (Noordenbos, '59). It is also of interest that Beaver ('67) and also Kerr ('67) have described the essential histopathology of trigeminal neuralgia as a proliferative and degenerative demyelination of the sensory trigeminal root. This process occurs predominantly in the largest root fibers. In addition, a tic douloureux-like pain is frequently associated with multiple sclerosis, a disease which attacks the sheaths of myelinated fibers (Harris, '50). In the current series of experiments a selective degeneration of larger ganglion cells and their corresponding central fibers was demonstrated. It might be theorized that ordinary surround inhibitions would be altered in this post-operative state because of the disproportion of the trigeminal afferent elements.

The presynaptic inhibition of primary trigeminal afferent fibers has also been shown to arise from sources such as the cortex, thalamus and other brain stem areas (Hernandez-Peon and Hagbarth, '55). Rapid conducting corticofugal fibers appear to have the capacity to influence the transmission of trigeminal impulses arriving at all levels of the trigeminal subnuclear column (Dubner, '67). These findings provide a location of action and physiologic model for the common observation that cortical activity can greatly alter the transmission of painful impulses. Casey and Melzack ('67) have proposed that the lemniscal projection system, including the chief sensory nucleus of trigeminal, project through a rapid two neuron arc to the cortex where they can activate the corticofugal neurons. These corticofugal fibers then project to the trigeminal area for modification of primary afferent activities. In the current experiments the predominant central degeneration observed

following peripheral lesions in both the rat and the cat was concentrated in the chief sensory nucleus area. It might be speculated that the corticofugal inhibitory loop would be altered in such a post-operative condition.

Clinical Considerations

In the previous section on physiologic mechanisms the concept was reviewed that an imbalance of afferent sensory nerve elements may profoundly alter the sensory perceptive experience. One possible mechanism by which afferent sensory input might be altered through extrinsic influence has been derived from the observations in the current experiments. The retrograde necrobiosis of some ganglion cells and their central processes may result from peripheral nerve lesions. If future research confirms that these findings are applicable to humans, they may lead to a better understanding of sensory neuropathy problems.

Among the sensory neuropathies that are known to occur, the problem of pathologic pain has received the greatest attention by biomedical scientists. Pathologic or "inappropriate" pain of the face has received particular consideration for a number of possible reasons: 1) facial pain is one of the most common presenting patient complaints, 2) facial pain frequently presents unique pathologic features, such as the case of trigeminal neuralgia, the understanding of which may provide keys to wider problems of sensory neuropathy, and 3) facial pain may be more important to people because of the intense psychological aura surrounding the human face (Pilling, '68).

White and Sweet ('55) had reviewed the reported cases of post-traumatic trigeminal neuralgia and concluded that the primary clinical features of this syndrome are pain of a diffuse, sustained, boring and non-provokable nature. Since this review, an increasing number of case histories have appeared in the literature that have directly correlated inappropriate or pathologic facial pain to various types of trauma (Goldstein, *et al.*, '63).

The clinical features of post-traumatic trigeminal neuralgia are in direct opposition to the known signs and symptoms of tic douloureux. This syndrome is typified by paroxysms of sharp, localized and provokable pain. In spite of these differences, however, the possibility remains that trauma may be related to the etiology of tic douloureux. It is known that the trigeminal ganglia of humans that had suffered from tic douloureux are

altered by a proliferative and degenerative demyelination of the sensory root larger fibers (Beaver, '67). Kerr ('67), in fact, conceded that peripheral nerve lesions may aggravate and perhaps precipitate the phenomenon of tic douloureux although he feels that the essential etiology is an age-related vascular effect on the ganglion rootlets.

The clinical practice of the head and neck surgeon is greatly tied to the physiology and pathology of the trigeminal sensory system. For example, one of the cardinal features of most facial trauma is damage to peripheral sensory neurons, a fact which frequently aids in the determination of location and extent of injury to facial tissues. Considering the potential for secondary central trigeminal degeneration following trauma, treatment plans should be oriented toward avoiding further trauma to the sensory nerves and to enhancing regenerative efforts to their maximum. In elective procedures which might approach the more proximal portions of the trigeminal nerves such as osteotomy, paranasal polypectomy, deep dental impaction or cyst excision, nerve transposition for preprosthetic purposes, and the elimination of blastomatoid or benign neoplastic processes, the treatment plan should also consider the preservation of sensory elements. In planning nerve ablative procedures for the control of intractable pain states such as trigeminal neuralgia and invasive metastatic neoplasm, as well as the excision of peripheral neural pathology such as amputation neuromas, consideration should be given to the possible longer term effects. A differential degeneration of neurons may occur and then be followed by the regeneration of a grossly intact but physiologically "imbalanced" nerve. The potential hazards of inadvertant nerve trunk disruption should be considered, even in the instance of block anesthesia for surgery of maxillo-dental regions.

The majority of the possible implications of the current study that have been discussed appear to stress rather negative potential influences that could be imposed upon the sensory trigeminal system. However, knowledge of variables in the degeneration process and an awareness of a possible selectivity of this response also introduces the possibility of a certain planned control of the situation. For example, Shelden, *et al.*, ('67) have embedded platinum electrodes in the mandibular nerves adjacent to the trigeminal ganglia of patients who had been suffering from trigeminal neuralgia. By maintaining a tonic stimulation of the larger fiber elements they were able to abolish the tic pain in a significant number of cases. Knowledge of the differing susceptibilities of ganglion cells may provide clues

to neurotrophic-related diseases such as scleroderma (Thoma, '41), progressive facial hemiatrophy (Gorlin and Pindborg, '64) and herpes simplex infection (Johnson and Mims, '68). It may also be determined that different kinds of surgical manipulations such as cryotherapy, electrocautery, irradiation, chemotherapy and laser surgery have decidedly differing effects on the degenerative picture. Future studies of these problems may help dictate prefered modes of surgical treatment.

CONCLUSIONS

1. The central question of whether extracranial sections of the trigeminal nerve can result in ganglion cell death and the degeneration of central processes was investigated in these experiments. The experimental variables of the study included the use of two nerve lesions at differing distances from the cell bodies, the study of the effects of nerve injury on two species, cat and rat, and the comparative effects on young and adult rats. The post-operative time interval before the effects of nerve lesion were studied ranged from one-half to twenty weeks.

2. Observation of chromatolytic patterns in the trigeminal ganglia of adult rats following extracranial nerve lesions revealed distinct somatotopic relations. The mandibular division cell bodies were localized posteriorly and laterally within the ganglia, and the cell bodies of the inferior alveolar nerve were concentrated in the most ventral and posterior portions of the mandibular somatotopic area.

3. Section of the mandibular division of trigeminal at foramen ovale resulted in severe ganglionic chromatolysis followed by progressive disintegration and loss of some cell bodies. Section of the inferior alveolar nerve at the mandibular foramen also resulted in the necrobiosis of ganglion cells, but the response was more gradual. The largest ganglion cells appeared to react more violently to both nerve lesions.

4. Using both the Fink-Heimer and Marchi techniques degeneration was detected within the brain stem of young rats, adult rats and adult cats following both foramen ovale and mandibular foramen nerve sections. In addition, the Kluver-Barrara stain displayed a myelin disintegration throughout the descending tract and subnuclear complex at three weeks following foramen ovale nerve section. In the adult rat, Fink-Heimer degeneration was not observed before the third week following foramen ovale nerve section or the fourth week following mandibular foramen nerve section. Degeneration was consistently localized in the dorsal portions of the entire central trigeminal complex although no degeneration was observed in cerebellar, reticular, cranial motor nuclear, or contralateral areas. The

degeneration appeared to progress centrifugally from the ganglia into and down the brain stem. It was most intense in the chief sensory nucleus area and diminished progressively at more caudal levels until it reached the second cervical level of the spinal cord.

5. Compared to the trigeminal ganglion cells of the adult rats, the ganglion cells of the cats appeared to be more resistant to extracranial nerve sections. The preponderance of chief sensory degeneration over the degeneration at more caudal levels was greater in the cat than in the rat.

6. Degeneration in the young rats appeared to be more rapid and more absolute than in the adults. The young ganglia were grossly deficient of neurons and brain stem degeneration was prominent at a shorter interval following both of the peripheral nerve lesions.

7. The precise somatotopic patterns that may be found within the trigeminal ganglion, the sensory root and throughout the central tract and subnuclear areas may aid in the diagnosis and treatment of localizing intracranial pathology. In addition, the position of the peroral region cell bodies within the ventral portions of the ganglion may give insight into the trigger zone distribution as well as the etiology of tic douloureux.

8. Because a retrograde necrobiosis may occur in the trigeminal system following nerve lesions as far in the periphery as the inferior alveolar nerve, the management of nerve trauma and elective surgical procedures should also include the optimal preservation of sensory nerve elements.

9. The fact that some sensory ganglion cells appear to be less resistant than others to the effects of extracranial trigeminal nerve trauma may have relevance to the etiology of sensory neuropathy in these nerves. The imbalances that might have been imposed on the somatosensory system by a selective loss of afferent elements may be significant to such sensory dysfunctions as pathologic facial pain.

10. The greater susceptibility of the young animal to the effects of peripheral nerve trauma may be related to the immaturity of the nucleolar apparatuses and the corresponding inadequacies in protein synthesis capacities. Future treatment methods which involve nerve degeneration or regeneration should consider the increased vulnerability of the trigeminal systems of the very young.

REFERENCES

Astrom, K. E. On the central course of afferent fibers in the trigeminal, facial, glossopharyngeal, and vagal nerves and their nuclei in the mouse. *Acta. Physiol. Scand.* 30;Suppl. 106: 209, 1953.

Beaudreau, D. E. and Jerge, C. E. Somatotopic representation in the Gasserian ganglion of tactile peripheral fields in the cat. *Arch. Oral. Biol.* 13:247, 1968.

Beaver, D. L. Electron microscopy of the Gasserian ganglion in trigeminal neuralgia. *J. Neurosurg.* 26:138, 1967.

Beresford, W. A. A discussion on retrograde changes in nerve fibers. *Progress in Brain Research.* 14:33, 1965.

Bielschowsky, M. Histopathology of nerve Cells. *Cytology and Cellular Pathology of the Nervous System.* 1:147, ed. by W. Penfield, Hoeber, New York, 1932.

Bodian, D. and Mellors, R. C. The regenerative cycle of motoneurons, with special reference to phosphatase activity. *J. Exp. Med.* 81:469, 1945.

Boeke, J. Die Intrazellulare Lage der Nervenendigungern im Epithelgewebe und ihre Bezighungen zum Zellkern. *Ztschr. Mik. Anat. Forsch.* 2:391, 1925.

Brachet, J. and Chantrenne, H. The function of the nucleus in the synthesis of cytoplasmic proteins. *Cold Spring Harbor Symp. Quant. Biol.* 21:329, 1956.

Brattgard, S. O., Edstrom, J. E., and Hyden, H. The productive capacity of the neuron in retrograde reaction. *Exp. Cell Res. Suppl.* 5:185, 1958.

Brodal, A. Modification of Gudden method for study of cerebral localization. *Arch. Neurol. Psychiat.* (Chic.) 43:46, 1940.

Brodal, A. Afferent cerebellar connections. *Aspects of Cerebellar Anatomy.* pp. 82, ed. by J. Jensen and A. Brodal. J. Grundt Tanum, Oslo, 1954.

Bucy, P. C. Studies in degeneration of peripheral nerves. *J. Comp. Neurol.* 45:129, 1928.

Busch, I. A modification of the Marchi method. *Neurol. Centralblat.* 17:476, 1898.

Cammermeyer, J. Differential response of two neuron types to facial nerve transection in young and old rabbits. *J. Neuropath. Exp. Neurol.* 22:594, 1963.

Cammermeyer, J. Species differences in the initial retrograde reaction of motor neurons. *J. Neuropath. Exp. Neurol.* 27:114, 1968.

Carmel, P. W. and Stein, B. M. Cell changes in sensory ganglia following proximal and distal nerve sections in the monkey. *J. Comp. Neurol.* 135:145, 1969.

Casey, K. L. and Melzack, R. Neural mechanisms of pain: A conceptual model. *New Conception in Pain and its Clinical Management.* Ed. by E. L. Way, F. A. Davis, Co., Philadelphia, 1967.

Collins, W. F., Nulsen, F. E., and Randt, C. T. Relation of peripheral nerve fiber size and sensation in man. *Archs. Neurol.* (Chicago) 3:380, 1960.

Cowan, W. M., *et al.* An experimental study of the avian visual system. *J. Anat.* (London) 95:545, 1961.

Crosby, E. C. and Yoss, R. E. The phylogenetic continuity of neural mechanisms as illustrated by the spinal tract of V and its nucleus. *Proc. Ass. Res. Nerv. Ment. Dis.* 33:174, 1954.

Crosby, E. C., Humphrey, T., and Lauer, E. W. *Correlative Anatomy of the Nervous System.* Macmillan Co., New York, 1962.

Cupedo, R. N. J. A trigeminal midbrain-cerebellar fiber connection in the rat. *J. Comp. Neurol.* 124:61, 1965.

Dalessio, D. J. A reappraisal of the trigger zones of tic douloureux. *Headache.* 9:73, 1969.

Dandy, W. E. Lesions of the cranial nerves. I. Trigeminal neuralgia and trigeminal tic douloureux. *Lewis-Walters Practice of Surgery.* W. F. Prior Co., Hagerstown, Maryland, 12:167, 1966.

Darian-Smith, I., Matton, P., and Proctor, R. Functional organization of tactile cutaneous afferents within the semilunar ganglion and trigeminal spinal tract of the cat. *J. Neurophysiol.* 28:682, 1965.

Darian-Smith, I. Presynaptic component in the afferent inhibition observed within trigeminal brain-stem nuclei of the cat. *J. Neurophysiol.* 28:695, 1965.

Dawson, I. M., Hossack, J., and Wyburn, G. M. Observations on the Nissl substance, cytoplasmic filaments, and the nuclear membrane of spinal ganglion cells. *Proc. Roy. Soc. B.* 144:132, 1955.

Detwiler, S. R. On the hyperplasia of nerve centers resulting from excessive peripheral loading. *Proc. Nat. Acad. Sci.* (Washington) 6:96, 1920.

Dixon, A. D. Fine structure of nerve-cell bodies and satellite cells in the trigeminal ganglion. *J. Dent. Res.* 42:990, 1963.

Dixon, A. D. and Kaley, J. D. Central effects of stereotaxic lesions of the trigeminal ganglion. *Int. Assoc. for Dent. Res.* 46th General Meeting, p. 149, 1968.

Dubner, R. Interaction of peripheral and central input in the main sensory nucleus of the cat. *Exp. Neurol.* 17:186, 1967.

Eccles, J. C., Schmidt, R. F., and Willis, W. D. Depolarization of central terminals of cutaneous afferent fibers. *J. Neurophysiol.* 26:646, 1963.

Emmons, W. F. and Rhoton, A. L. Functional subdivision of the trigeminal sensory root. *Surg. Forum.* 19:440, 1968.

Fink, R. and Heimer, L. Two methods for selective silver impregnation of degenerating axons and their synaptic endings in the central nervous system. *Brain Res.* 4:369, 1967.

Gabbiani, G. Action of cadmium chloride on sensory ganglia. *Experientia.* 22:261, 1966.

Gasser, H. S. Conduction in nerves in relation to fiber types. *Proc. Ass. Res. Nerv. & Ment. Dis.* 15:35, 1935.

Geist, F. D. Chromatolysis of efferent neurons. *Arch. Neurol. Psychiat.* 29:88, 1933.

Goldstein, N., Gibilisco, J., and Rushton, J. Trigeminal neuropathy and neuritis. *J. A. M. A.* 184:458, 1963.

Gorlin, R. J. and Pindborg, J. J. *Syndromes of the Head and Neck.* McGraw-Hill, New York, 1964.

Grant, G. and Aldskogius, H. Silver impregnation of degenerating dendrites, cells and axons central axonal transection. A Nauta study on the hypoglossal nerve in kittens. *Exp. Brain Res.* 3:150, 1967.

Gudden, B. Experimental-untersuchungen uber das Peripherische und centrale Nervensystem. *Arch. Psychiat.* 2:693, 1870.

Hamburger, V. Regeneration in the central nervous system of reptiles and birds. In *Regeneration in the Central Nervous System.* Ed. by W. F. Windle, Springfield, Ill., 1955.

Hamburger, V. Experimental analysis of the dual origin of the trigeminal ganglion in the chick embryo. *J. Exp. Zool.* 148:91, 1961.

Hamburger, V. and Levi-Montalcini, R. Proliferation, differentiation and degeneration in the spinal ganglia of the chick embryo under normal and experimental conditions. *J. Exp. Zool.* 111:457, 1949.

Harris, W. Rare forms of paroxysmal trigeminal neuralgia and their relation to disseminated sclerosis. *Brit. Med. J.* 2:1015, 1950.

Hartmann, J. F. Electron microscopy of motor nerve cells following section of axons. *Anat. Rec.* 118:19, 1954.

Heinbecker, P., Bishop, G. H., and O'Leary, J. L. Pain and touch fibers in peripheral nerves. *Archs. Neurol. Psychiat.* (Chicago) 29:771, 1935.

Hernandez-Peon, R. and Hagbarth, K. E. Interaction between afferent and cortically induced reticular responses. *J. Neurophysiol.* 18:44, 1955.

Hess, A. Reactions of mammalian fetal spinal cord, spinal ganglia and brain to injury. *J. Exp. Zool.* 132:349, 1956.

Huber, G. C. and Lewis, D. Amputation neuromas, their development and prevention. *Arch. Surg.* (Chicago) 1:85, 1920.

Huber, G. C. Experimental observations on peripheral nerve repair. In *The Medical Department of the U. S. in the World War.* U. S. Government Printing Office, Washington, D. C., 1927.

Humphrey, T. Some correlations between the appearance of human fetal reflexes and the development of the nervous system. *Prog. in Brain Res.* 4:93, 1964.

Jerge, C. R. The function of the nucleus supratrigeminalis. *J. Neurophysiol.* 26:393, 1963.

Jilek, L., Fischer, J., Krulich, L., and Trojan, S. The reaction of the brain to stagnant hypoxia and anoxia during ontogeny. *Prog. in Brain Res.* 9:113, 1964.

Johnson, R. T. and Mims, C. A. Pathogenesis of viral infections of the nervous system. *New Engl. J. Med.* 278:23, 84, 1968.

Johnston, M. C. A radioautographic study of the migration and fate of cranial neural crest cells in the chick embryo. *Anat. Rec.* 156:143, 1966.

Kahn, G. Zoster and herpes simplex. Simultaneous occurrence in the same patient. *Arch. Derm.* (Chicago) 95:298, 1967.

Kerr, F. W. L. The etiology of trigeminal neuralgia. *Arch. Neurol.* 8:15, 1963.

Kerr, F. W. L. and Lysak, W. R. Somatotopic organization of trigeminal-ganglion neurons. *Arch. Neurol.* 11:593, 1964.

Kerr, F. W. L. Pathology of trigeminal neuralgia: light and electron microscopic observations. *J. Neurogurg.* 26 (Suppl.):151, 1967.

Kerr, F. W. L., Kruger, L., Schwassmann, H. O., *et al.* Somatotopic organization of mechanoreceptor units in the trigeminal nuclear complex of the macaque. *J. Comp. Neurol.* 134:127, 1968.

Kirkpatrick, J. B. Chromatolysis in the hypoglossal nucleus of the rat: An electron microscopic analysis. *J. Comp. Neurol.* 132:189, 1968.

Koelliker, A. Der feiners Bau des verlangerten Markes. *Anat. Anz.* 6:427, 1891.

Koenig, H. Acute axonal dystrophy caused by fluorocitrate: The role of mitochondrial swelling. *Science.* 164:310, 1969.

Lance, J. W. Behavior of pyramidal axons following section. *Brain.* 77:314, 1954.

La Velle, A. and La Velle, F. W. Neuronal swelling and chromatolysis as influenced by the state of cell development. *Amer. J. Anat.* 102:219, 1958.

La Velle, A. and La Velle, F. W. Neuronal reaction to injury during development. Severence of the seventh nerve in utero. *Exp. Neurol.* 1:82, 1959.

Lele, P. P. and **Weddell,** G. The relationship between neurohistology and corneal sensibility. *Brain.* 79:119, 1956.

Liu, Ch. N. The innervation of Clark's nucleus and the lateral cuneate nucleus in the cat. *Anat. Record.* 121:332, 1955.

Lubinska, L. Axoplasmic streaming in regenerating and normal nerve fibers. *Prog. in Brain Res.* 13:1, 1964.

Margolis, G. and Pickett, J. New applications of the luxol fast myelin stain. *Lab. Invest.* 5:459, 1956.

McKinney, A. S., Sears, R. A., and Heinz, E. R. Fungus infection of the gasserian ganglion. *Arch. Neurol.* (Chicago) 19:208, 1968.

Melzak, R. and Wall, P. Pain mechansims: A new theory. *Science.* 150:971, 1965.

Muller, J. Zur vergleichended Physiologie des Gesichtinnes des Menschen und der Thiere nebst einem Versuch uber die Bewegungen der Augen und uber den menschlichen Blick. C. Cnobloh, Leipzig, 1862.

Nakai, J. Dissociated dorsal root ganglia in tissue culture. *Amer. J. Anat.* 99:81, 1956.

Nauta, W. J. H. and Gygax, P. A. Silver impregnation of degenerating axons in the central nervous system: A modified technique. *Stain Tech.* 29:91, 1954.

Nissl, F. Uber die Veranderungen der Ganglienzellen am Facialiskern des Kaninchems nach Ausreissung der Nerven. *Allg. Z. Psychiat.* 48:197, 1892.

Noordenbos, W. *Pain.* Amsterdam:Elsevier, 1959.

Nord, S. G. Somatotopic organization in the spinal trigeminal nucleus, the dorsal column nuclei and related structures in the rat. *J. Comp. Neurol.* 130:343, 1967.

Oderfold-Nowak, B. and Niemierko, S. Synthesis of nucleic acids in the Schwann cells as the early cellular response to nerve injury. *J. Neurochem.* 16:235, 1969.

Piatt, J. Regeneration in the central nervous system of amphibia. In *Regeneration in the Central Nervous System.* Ed. by W. F. Windle, Springfield, Ill., 1955.

Pilling, L. Psychosomatic aspects of facial pain. In *Facial Pain.* Ed. by C. Alling, Lea & Febiger, Philadelphia, 1968.

Porter, R. W., Hohmann, G. W., Bors, E., and Franch, J. D. Cordotomy for pain following cauda equina injury. *Archs. Surg.* (Chicago) 92:765, 1966.

Ramon Y Cajal. *Degeneration and regeneration of the nervous system.* (Translated by R. M. May.) Oxford University Press, London, 1928.

Rand, C. W. and Courville, C. B. Histologic changes in the brain in cases of fatal injury to the head. *Arch. Nevr. Psychiat.* 55:79, 1946.

Sasa, M., Fukuda, N., and Takaori, S. Effects of aminopyrine and phenylbutazone on the activity of neurons in the trigeminal nuclei and hypothalamus. *Jap. J. Pharmacol.* 19:363, 1969.

Sauerland, E. K. Effect of ethyl alcohol on trigeminal sensory neurons. *Bull. Los Angeles Neurol. Soc.* 35:16, 1970.

Shelden, C. H., Pudenz, R. H., and Doyle, J. Electrical control of facial pain. *Amer. J. Surg.* 114:209, 1967.

Singer, M. The influence of the nerves in regeneration of the amphibian extremity. *Quant. Rev. Biol.* 27:169, 1952.

Sjoqvist, O. Studies on pain conduction in the trigeminal nerve. A contribution to the surgical treatment of facial pain. *Acta. Psychiat. Scand.* 1 (Suppl. 17), 1938.

Smith, K. R. The fine structure of neurons of the dorsal root ganglia after stimulating or cutting the sciatic nerve. *J. Comp. Neurol.* 116:103, 1961.

Smith, R. D., Marcarian, H. Q., and Niemer, W. T. Bilateral relationships of the trigeminal mesencephalic nuclei and mastication. *J. Comp. Neurol.* 131:79, 1967.

Sperling, E. and Stender, A. "Tic douloureux" and Gesichtsschmerz. (Therapeutische und Pathogenetisches Betrachtungen). *Deutsch. Z. Nervenheilk.* 173:161, 1955.

Sperry, R. W. Patterning of central synapses in regeneration of the optic nerve in teleosts. *Physio. Zool.* 21:351, 1948.

Strassburg, M. Morphologic reaction of the trigeminal ganglion after experimental surgery on the maxillodental region. *J. Oral Surg.* 25:107, 1967.

Swank, R. L. and Davenport, H. A. Marchi Staining method. Studies of some of the underlying mechanisms involved. *Stain Tech.* 9:11, 1934.

Thoma, K. *Oral Pathology*. C. V. Mosby, St. Louis, 1941.

Torvik, A. Afferent connections to the sensory trigeminal nuclei, the nucleus of the solitary tract and adjacent structures. An experimental study in the rat. *J. Comp. Neurol.* 106:51, 1956.

Torvik, A. and Heding, A. Effect of actinomycin D on retrograde nerve cell reaction. *Acta. Neuropath.* 14:62, 1969.

Tower, S. S. Regenerative capacity of ventral roots after avulsion from the spinal cord. *Arch. Neurol. & Psychiat.* 49:1, 1943.

Van Gehuchten, A. La degenerescence dite retrograde ou degenerescence walleriene indirecte. *Nevraxe.* 5:108, 1903.

Visoso, A. D. and Young, J. Z. Internode length and fiber diameter in developing and regenerating nerves. *J. Anat.* (London) 82:110, 1948.

Waller, W. H. Observations sur les effets de la section des racines spinales et du nerf pneumogastrique au-dessus de son ganglion inferieur chez les mammifere. *C. R. Acad. Sci.* (Paris) 34:582, 1852.

Weddell, G. The pattern of cutaneous innervation in relation to cutaneous sensibility. *J. Anat.* (London) 75:346, 1941.

Weiss, P. Nervous system (neurogenesis). In *Analysis of development*. Ed. by D. H. Willier, P. A. Weiss and V. Hamburger, Saunders, Philadelphia, 1955.

White, J. C. and Sweet, W. H. *Pain: Its Mechanisms and Neurosurgical Control.* C. C. Thomas, Springfield, Ill., 1955.

Windle, W. F. Non-bifurcating nerve fibers of the trigeminal nerve. *J. Comp. Neurol.* 40:229, 1926.

Woodburne, R. T. A phylogenetic consideration of the primary and secondary centers and connections of the trigeminal complex in a series of vertebrates. *J. Comp. Neurol.* 65:403, 1936.