Title: Staging and Grading Discussion of Borderline Cases in Gray Zones.

Authors:

Larissa Steigmann, DMD[*]; Celia Sommer, DMD, MPH[*]; Kenneth Kornman DDS, PhD[*], and Hom-Lay Wang, DDS, MSD, PhD[*]

[*] Department of Periodontics and Oral Medicine, School of Dentistry, University of Michigan, Ann Arbor, Michigan, USA.

Conflict of interest and source of funding statement: The authors declare that they have no conflicts of interest. No author received any monetary compensation for this manuscript.

Word count: 1,475

Tables: 0

Figures: 4

Short running title: Staging and Grading Assignment for Borderline Cases.

Summary: Clinical judgment is needed in order to properly assign staging and grading to chronic periodontitis cases that fall into gray zones within the confines of the classification.

Keywords: Periodontitis; disease management; diagnosis; classification.

This article has been accepted for publication and undergone full peer review but has not been through the copyediting, typesetting, pagination and proofreading process, which may lead to differences between this version and the Version of Record. Please cite this article as doi: 10.1111/10129.

This article is protected by copyright. All rights reserved.

Accepted Article

Authorship & acknowledgments:

LS, CS, KK and HLW: Case documentation, manuscript draft and preparation and final revision.

Abstract:

Introduction: Staging and grading for chronic periodontal disease, as described in 2018 [1], is designed to focus on key distinctions with the recognition that there is a subset of individuals who are on a different clinical trajectory of disease. The staging and grading framework aids the clinician in generating a periodontal diagnosis, however some cases fall into gray zones in which the simple diagnostic parameters make it challenging to categorize the patient[2]. These cases do not present with clear clinical findings and medical and dental histories that fit within the simple guidelines defined in the staging and grading tables and subsequent algorithms.

Case: Two cases are presented and demonstrate typical clinical scenarios that fall into gray zones when it comes to differentiating whether the patient is more likely to respond predictably to standard principles of care. Case one presents a scenario in which patient's early history suggests the potential for disease progression and increases the likelihood that the patient is less likely to respond predictably and may develop a need for complex rehabilitation due to periodontal breakdown. Clinical judgment was used to evaluate whether the patient remained at elevated risk and the potential implications and was diagnosed as Stage III, Grade B. The second case has a higher severity and complexity, however the need for complex rehabilitation was not primarily due to periodontitis and was diagnosed as Stage IV, Grade C.

Conclusion: Decision guidelines and algorithms help in establishing a standardized diagnosis, however cases that fall into gray zones require clinical judgment in order to establish the most appropriate diagnosis to guide a treatment plan that is personalized based on current knowledge.

This article is protected by copyright. All rights reserved.

Accepted Article

Background:

Staging and grading for chronic periodontal disease, as described in 2018 [1], is designed to focus on key distinctions from prior classifications. The primary distinction is the recognition that there is a subset of individuals who are on a different clinical trajectory of disease that is evident by the early 30s [3] and even earlier. In addition, evidence supports that 20 to 25% of periodontitis patients do not respond predictably to standard principles of prevention and treatment as established in the Michigan and Gothenburg studies.[4, 5] The new classification also acknowledges that there is currently inconsistent evidence that implicates specific microorganisms or an altered pathophysiology as the causal factors in the cases that are on a different disease trajectory.

The primary goals of the new classification were to provide key parameters that allow clinicians to more predictably differentiate between the periodontitis cases that should predictably respond to standard principles of prevention and treatment of periodontitis from cases that are unlikely to respond as predictably. The goal was not to provide a definitive diagnosis but to more reliably classify patients into multiple staging and grading categories that provide a classification framework to aid the clinician in generating a treatment plan for control and long term management of individual periodontitis and reconstruction cases as needed to establish masticatory function, esthetics, and comfort. However, it is clear that some cases do not present with clear clinical findings and medical and dental histories that fit within the simple guidelines defined in the staging and grading tables [1, 6] and subsequent algorithms. [7] Experienced clinical judgment should bridge some of the "gray zones" as discussed below and previously.[8] Both patients completed a written informed consent at consultation, where treatment options were discussed in detail.

This article is protected by copyright. All rights reserved.

Accepted Article

Clinical Presentation:

Case 1: A systemically healthy 66-year old female with a family history of periodontitis and diagnosis of periodontitis at the age of 14 (Figs. 1.1-1.2). The patient has a history of non-surgical periodontal therapy, routine maintenance therapy every six months, and four tooth extractions due to periodontitis. Limited finances have prevented the patient from seeking professional periodontal care in the past three years. The patient exhibited signs of parafunctional bruxism and clenching, with secondary occlusal trauma, severe ridge defects, and tooth migration. The patient has generalized interproximal attachment loss $\geq$ 5 mm that is affecting > 30% of the teeth, as well as generalized radiographic bone loss extending to the mid-third of the root with three localized vertical defects (tooth #13, 14, and 26) that extends beyond the mid-third of the root (Figs. 1.1-1.2).

Case 2: A systemically healthy 64-year old female with no family history of periodontitis and diagnosis of periodontal disease as an adult (Figs. 2.1-2.2). The patient has had no extractions due to periodontitis, no history of periodontal therapy, and no routine preventive dental care. The patient exhibited signs of parafunctional bruxism with secondary occlusal trauma. The patient has generalized interproximal attachment loss $\geq$ 5 mm that is affecting > 30% of the teeth, as well as generalized radiographic bone loss extending to the coronal-third of the root with eight localized vertical defects (tooth #2, 4, 5, 14, 15, 19, 21, 30) that extend to the mid-third of the root or beyond. The patient has several periapical lesions and one implant with peri-implant disease (Figs. 2.1-2.2).

This article is protected by copyright. All rights reserved.

Accepted Article

Case management

Clinical Outcome:

Both clinical cases represent scenarios in which the periodontal diagnosis distinction is not straight forward. The main differentiating aspect between a Stage III or Stage IV classification is the complexity of the case, which includes the anticipated disease trajectory as part of the clinical judgment and anticipated treatment outcome. A complex case may require reestablishing the vertical dimension of occlusion, advanced surgical procedures in order to rehabilitate the patient with multiple implants, close monitoring for potential periodontal breakdown and its effects on the overall treatment plan, and a more involved interdisciplinary team to rehabilitate and manage, therefore being able to identify when a borderline Stage III/IV case has a potential to become a stage IV complexity is key. The clinical judgement for the diagnosis of these two borderline cases demonstrates that there are complex factors involved in categorizing a patient into a disease classification.

Case 1 presents a patient with a clear stage III/IV severity based on generalized clinical attachment loss (AL), radiographic bone loss, and tooth loss due to periodontitis. The patient has 24 remaining teeth, 11 occluding pairs, and no masticatory dysfunction. Although the patient has localized secondary occlusal trauma, severe ridge defects, and drifting; the need for complex rehabilitation does not yet exist given the patients current occlusion (Fig. 1.1.)[9]. A Stage III diagnosis would be appropriate given the patient's current clinical presentation. Given the patient's history of an early diagnosis of periodontitis and removal of teeth due to periodontitis, non-surgical periodontal therapy and management of the patient's occlusion may not be able to preserve her remaining dentition, which may result in the patient losing another 3-5 teeth to periodontal disease and may

This article is protected by copyright. All rights reserved.

Accepted Article

experience significant masticatory dysfunction. In spite of the history of an early periodontitis diagnosis the maximum radiographic bone loss/age is less than 1.0 and there are no clear signs of overt risk factors for progression. Although the periodontal destruction seems to be more than one might expect given relatively minor biofilm deposits, this characteristic is not a strong predictor of future progression given the amount of total tissue destruction at the patient's current age, therefore a Grade B diagnosis seems to be appropriate for the rate of disease progression.

Case 2 presents a patient with generalized clinical attachment loss (AL) and radiographic bone loss, however the severity of the case is multifactorial. The patient has 25 remaining teeth, 13 occluding pairs, and concerns about reduced masticatory function on the right side (Fig. 2.2.). After removal of hopeless teeth, the patient will have a need for complex rehabilitation to regain sufficient masticatory function. This will leave the patient with 10 occluding pairs, a deep impinging overbite, and secondary trauma from occlusion. Initial interpretation of this case suggests a Stage IV classification due to the complexity of the rehabilitation. The patient is susceptible to periodontal disease, and the radiographic bone loss given the patient's age qualifies the case for a Grade C classification which indicates that the patient should be monitored closely. Notably, it should be noted that the primary reason for the severity of the case appears to be strongly related to endodontic lesions, vertical root fractures, root perforations, heavy occlusal loads from existing restorative crowns, and a parafunctional bruxism habit. Despite the need for rehabilitation under the management of an interdisciplinary team, the close monitoring of the case, as indicated by Grade C, is also justified to verify that the response to periodontal treatment and maintenance is consistent with all aspects of the risk profile of the case.

This article is protected by copyright. All rights reserved.

Accepted Article

Discussion:

Simple decision guidelines and algorithms facilitate the implementation of a diagnosis system in clinical practice, however, there comes a point in which intuitive judgment is needed in order to navigate the limitations of a binary algorithm. Cases that are borderline and fall into gray zones, such as the ones described, do not have a definitive diagnosis (Figs. 1.1-1.2 and Figs. 2.1-2.2.). Variability may exist between clinicians and may change during the course of treatment. Key is to integrate clinical judgement needed in establishing a diagnosis that is appropriate for the patient's overall health and the development of an individualized patient specific treatment plan.

In the cases presented, neither patient has known co-morbidities or any environmental factors, such as smoking, that contribute to the periodontal disease progression. What appears to distinguish these cases is the degree of periodontal disease susceptibility. The early onset of periodontitis in Case 1, and the clinical and radiographic presentation in later years implicates intrinsic risk factors that adversely affected the patient's host response to bacterial challenges, but regular professional maintenance care (Figs. 1.1-1.2) appears to have helped to moderate progression of the patient's periodontitis for many years. The phenotypic response of Case 1 may lead to continued tissue breakdown and could indicate a higher risk for future tooth loss.

Detailed evaluation of Case 2 reveals a less severe phenotypic response that is exacerbated by non-periodontitis related factors. It is anticipated that this patient will respond well to standard therapy given the overt presence of local contributing etiologies. With the limited amount of bone loss in areas where other etiologies are excluded and no history of therapy, the degree of progression is not nearly as severe as it initially appears. It is clear, however, that this case requires a multidisciplinary approach to manage current endodontic and reconstructive challenges.

This article is protected by copyright. All rights reserved.

Accepted Article

Once a stage of the disease is determined, the patient receives a grading diagnosis that considers the patient's known risk factors to project anticipated rate of progression and likely responsiveness to current principles of treating periodontitis. The risk for future periodontal breakdown can be projected by an indirect measure of the patient's disease progression using a bone loss to age ratio. As demonstrated by case 2, the bone loss progression is severe and the calculated ratio would place the patient in a rapid rate of progression, however the etiology is not entirely due to periodontitis and the case phenotype is one that resembles a less susceptible clinical presentation.

Rather than debate how borderline cases must fit into a specific diagnosis within the parameters of a simple guideline, we should embrace the strategy of utilizing clinical experience in the decision-making process. A diagnostic distinction may be difficult to reach for borderline cases, however developing the appropriate treatment plan based on evidence based therapeutic interventions and clinical experience is the ultimate goal. These cases highlight, how clinical judgment is needed to arrive at the most appropriate diagnosis unique for each patient.

Summary:

Why are these cases new information?	Borderline cases require clinical judgment and often cannot be classified following simple diagnostic guidelines. Being able to identify when a borderline Stage III/IV has a potential to become a stage IV complexity is a key discriminatory factor.
What are the keys to successful management of these cases?	A thorough assessment of the patient's disease history, periodontal phenotype, and recognition of systemic and local contributing factors and how they interplay with existing primary

This article is protected by copyright. All rights reserved.

Accepted Article

	etiologies are important assessments in composing an overall view of the patient's health. Borderline cases require clinicians to additionally rely on their clinical judgement to overcome strict algorithmic assessments outside of the parameters of the general guidelines in order to arrive at an appropriate diagnosis and treatment plan.
What are the primary limitations to success in these cases?	Differences in clinical training and experience may result in different diagnoses among clinicians, however this may also lead to meaningful discussions that help clinician's recognize borderline type of cases and its implication for treatment. With continued scientific research and discoveries, the existing classification system will continue to evolve.

References:

1. Tonetti MS, Greenwell H, Kornman KS. Staging and grading of periodontitis: Framework and proposal of a new classification and case definition. *J Periodontol* 2018;89 Suppl 1:S159-S172.
2. Chandra A, Khullar D, Lee TH. Addressing the challenge of gray-zone medicine. *N Engl J Med* 2015;372:203-205.
3. Billings M, Holtfreter B, Papapanou PN, Mitnik GL, Kocher T, Dye BA. Age-dependent distribution of periodontitis in two countries: Findings from NHANES 2009 to 2014 and SHIP-TREND 2008 to 2012. *J Periodontol* 2018;89 Suppl 1:S140-S158.
4. Ramfjord SP, Knowles JW, Nissle RR, Burgett FG, Shick RA. Results following three modalities of periodontal therapy. *J Periodontol* 1975;46:522-526.
5. Lindhe J, Nyman S. Long-term maintenance of patients treated for advanced periodontal disease. *J Clin Periodontol* 1984;11:504-514.

This article is protected by copyright. All rights reserved.

Accepted Article

6. Papapanou PN, Sanz M, Buduneli N, et al. Periodontitis: Consensus report of workgroup 2 of the 2017 World Workshop on the Classification of Periodontal and Peri-Implant Diseases and Conditions. *J Periodontol* 2018;89 Suppl 1:S173-S182.

7. Tonetti MS, Sanz M. Implementation of the new classification of periodontal diseases: Decision-making algorithms for clinical practice and education. *J Clin Periodontol* 2019;46:398-405.

8. Kornman KS, Papapanou PN. Clinical application of the new classification of periodontal diseases: Ground rules, clarifications and "gray zones". *J Periodontol* 2020;91:352-360.

9. Gotfredsen K, Walls AWG. What dentition assures oral function? *Clin Oral Impl Res* 2007;18:34-45.

This article is protected by copyright. All rights reserved.

Accepted Article

Figure Legend:

Figure 1.1. Case 1. Healthy 66-year old female with periodontal disease diagnosis as a teenager with 8 missing teeth and 4 teeth likely lost due to periodontal disease. Periodontal charting with AL 6-11 mm and secondary occlusal trauma indicated through grade 2 mobility; Intraoral photographs; Staging according to severity and complexity of the patient; Outlined in red displays possible indication for stage IV classification; Underlined in blue indicates potential treatment needs and conditions.

Figure 1.2. Case 1. Healthy 66-year old with no history of smoking and is normoglycemic. Intraoral photographs; Radiographs with extent of bone loss indicated at the worst sites; Primary criteria for grading calculated by bone loss/age ratio and evidence of destruction that exceeds predictions given the biofilm deposition.

*Figure 2.1. Case 2. (*Exemplary*) Healthy 64-year old with no history of periodontal therapy. Periodontal charting with AL 6-13 mm and secondary occlusal trauma indicated through grade 3 mobility and fremitus; Intraoral photographs; Staging according to severity and complexity of the patient. Outlined in red displays possible indication for stage III classification; Underlined in blue indicates potential treatment needs.*

*Figure 2.2. Case 2. (*Exemplary*) Healthy 64-year old with no history of smoking and is normoglycemic. Intraoral photographs; Intraoral photographs of case 2; Radiographs with extent of bone loss indicated at the worst sites; Primary criteria for grading calculated by bone loss/age ratio and evidence of progression commensurate with biofilm destruction.*

This article is protected by copyright. All rights reserved.

Accepted Article

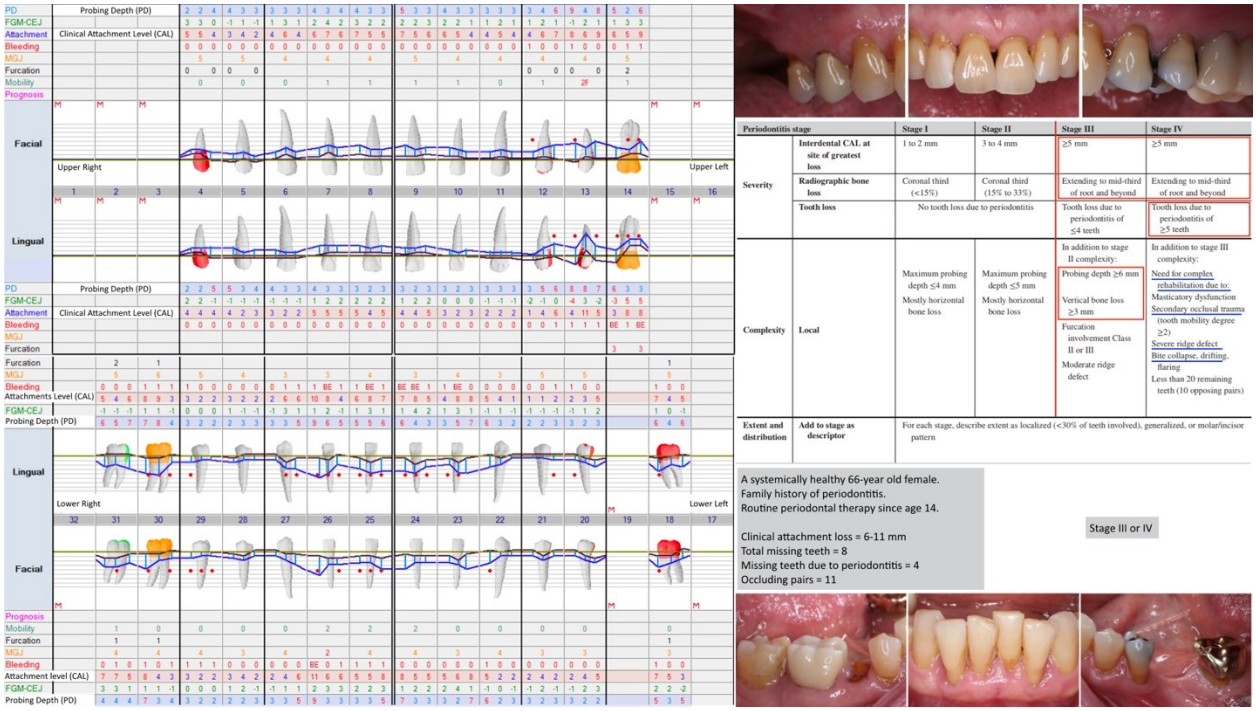

Figure 1.1. Case 1. *Healthy 66-year old female with periodontal disease diagnosis as a teenager with 8 missing teeth and 4 teeth likely lost due to periodontal disease. Periodontal charting with AL 6-11 mm and secondary occlusal trauma indicated through grade 2 mobility; Intraoral photographs; Staging according to severity and complexity of the patient; Outlined in red displays possible indication for stage IV classification; Underlined in blue indicates potential treatment needs and conditions.*

This article is protected by copyright. All rights reserved.

Accepted Article



Figure 1.2. Case 1. *Healthy 66-year old with no history of smoking and is normoglycemic. Intraoral photographs; Radiographs with extent of bone loss indicated at the worst sites; Primary criteria for grading calculated by bone loss/age ratio and evidence of destruction that exceeds predictions given the biofilm deposition.*

This article is protected by copyright. All rights reserved.

Accepted Article

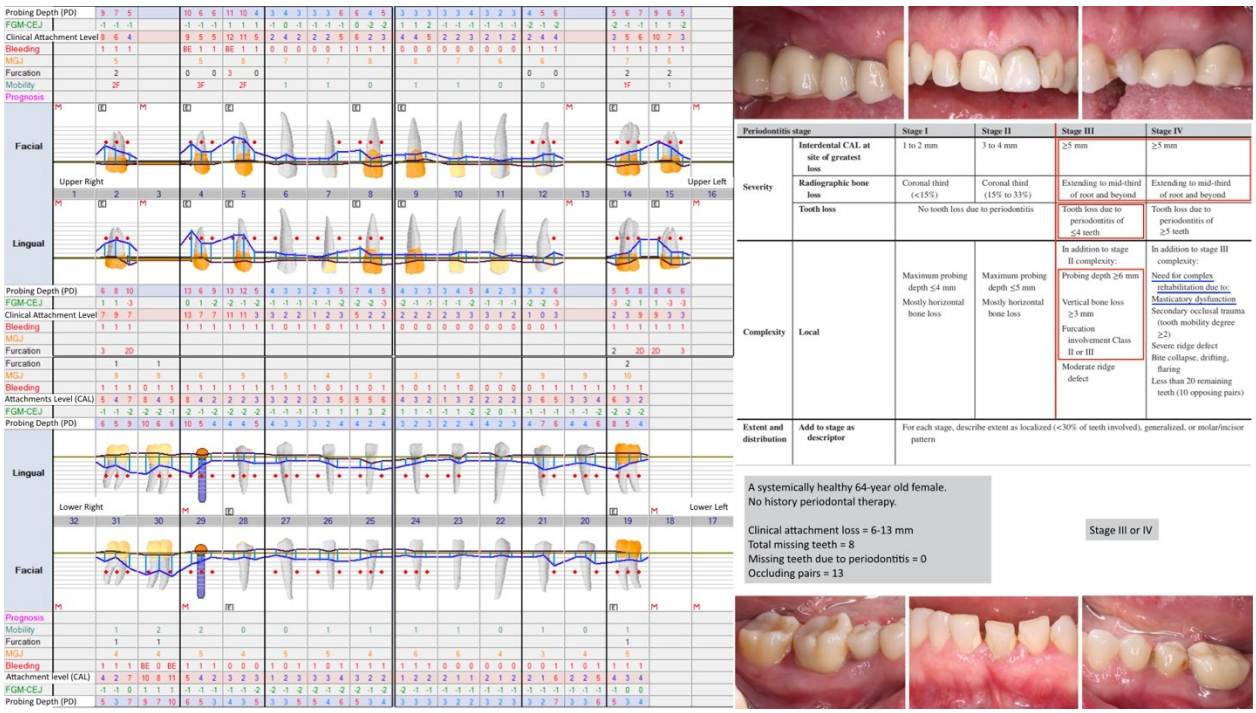

Figure 2.1. Case 2. *Healthy 64-year old with no history of periodontal therapy. Periodontal charting with AL 6-13 mm and secondary occlusal trauma indicated through grade 3 mobility and fremitus; Intraoral photographs; Staging according to severity and complexity of the patient. Outlined in red displays possible indication for stage III classification; Underlined in blue indicates potential treatment needs.*

This article is protected by copyright. All rights reserved.

Accepted Article



Periodontitis grade			Grade A: Slow rate of progression	Grade B: Moderate rate of progression	Grade C: Rapid rate of progression
Primary criteria	Direct evidence of progression	Longitudinal data (radiographic bone loss or CAL)	Evidence of no loss over 5 years	<2 mm over 5 years	≥2 mm over 5 years
	Indirect evidence of progression	% bone loss/age	<0.25	0.25 to 1.0	>1.0
		Case phenotype	Heavy biofilm deposits with low levels of destruction	Destruction commensurate with biofilm deposits	Destruction exceeds expectation given biofilm deposits; specific clinical patterns suggestive of periods of rapid progression and/or early onset disease (e.g., molar/incisor pattern; lack of expected response to standard bacterial control therapies)
Grade modifiers	Risk factors	Smoking	Non-smoker	Smoker <10 cigarettes/day	Smoker ≥10 cigarettes/day
		Diabetes	Normoglycemic/ no diagnosis of diabetes	HbA1c <7.0% in patients with diabetes	HbA1c ≥7.0% in patients with diabetes

Radiographic bone loss = (70% of root) / (64 years old) = 1.09

Grade B or C

Figure 2.2. Case 2. Healthy 64-year old with no history of smoking and is normoglycemic. Intraoral photographs; Intraoral photographs of case 2; Radiographs with extent of bone loss indicated at the worst sites; Primary criteria for grading calculated by bone loss/age ratio and evidence of progression commensurate with biofilm destruction.

This article is protected by copyright. All rights reserved.