Author Manuscript

Experience with Trametinib in a pediatric patient with MAP2K1 related cervicofacial arterio-venous malformation (AVM)

Neeraja Swaminathan MBBS [1], Joshua D. Smith MD [2], Hemant A. Parmar MBBS [3], Joseph J. Gemmete MD [2, 3, 4], Steven W Pipe MD [5], David A. Zopf MD, MS [2]

1 Department of Pediatrics, Pediatric Hematology Oncology, University of Michigan

2 Department of Otolaryngology- Head and Neck Surgery, University of Michigan

3 Department of Radiology, University of Michigan

4 Department of Neurosurgery, University of Michigan

5 Department of Pediatrics and Pathology, University of Michigan

Corresponding Author:

Neeraja Swaminathan, MD

Assistant Professor of Pediatrics, Division of Pediatric Hematology Oncology,

Vanderbilt University Medical Center

2220 Pierce Avenue, Nashville TN 37232

Phone: 615-936-2022

Email: neeraja.swaminathan@vumc.org

Main text word count- 849

Figures: 2

Brief running title: Trametinib experience in patient with AVM

Keywords: Trametinib, arterio-venous malformation, AVM, MEK inhibitors

Abbreviations:

RAS/MAPK: RAS/ mitogen activated protein kinase.

AVM: Arterio-venous malformation

MAP2K1: Mitogen activated protein kinase kinase 1

MEK: Mitogen activated protein-extracellular signal regulated kinase one.

This is the author manuscript accepted for publication and has undergone full peer review but has not been through the copyediting, typesetting, pagination and proofreading process, which may lead to differences between this version and the Version of Record. Please cite this article as doi: 10.1002/pbc.31298.

This article is protected by copyright. All rights reserved.

Author Manuscript

To the Editor:

Arterio-venous malformations (AVMs) of the head and neck are complex vascular lesions associated with substantial risk of hemorrhage, deformity, and functional impairment. Mutations in the RAS/ MAPK pathway have been described in patients with AVMs, opening the potential for targeted therapies, however there is limited safety and efficacy data. We report our 36 months experience with trametinib in a patient with extensive cervicofacial AVM harboring a somatic MAP2K1 mutation.

Our patient is an 11-year-old girl with an AVM of the right hemiface including the auricle, nasal cavity, nasopharynx, oropharynx, hemithyroid, and extends contralaterally to the uvula, soft palate, and tonsillar fossae, bilateral supraglottis and subglottis, sparing the vocal folds. She was previously treated with embolizations, yttrium aluminum garnet (YAG)-laser treatment of the skin component, bilateral adenotonsillectomy with uvulectomy, partial excision and reconstruction of the right upper lip. She had steady growth of her AVM through infancy and early childhood leading to recurrent epistaxis. She was treated with oral propranolol for one year which was stopped due to lack of clinical improvement. After establishing care at our center, she continued to have intermittent spontaneous epistaxis and oral bleeding requiring hospital admission 1-2 times annually and close follow-up by our Otolaryngology- Head and Neck Surgery (OTO-HNS) team. At age seven, she was admitted to our pediatric intensive care unit for management of spontaneous soft palatal hemorrhage. At this time, she was initiated on oral sirolimus which was discontinued after one month as she developed throat ulceration. Later that same year, she underwent extraction of retained primary molars and impacted bicuspids

This article is protected by copyright. All rights reserved.

Author Manuscript

which was complicated by profuse hemorrhage from the right glosso-tonsillar sulcus requiring surgical control. Tracheostomy was discussed several times with the family due to the concern for life-threatening airway bleeding with possible accelerated AVM growth approaching puberty; however, this was not performed. For the next several years, she had intermittent coblation treatments to address epistaxis associated with her intranasal AVM.

Given continued concern about AVM progression, genetic sequencing was performed which revealed a somatic MAP2K1 mutation. A few months after, she was found to have progression of her AVM based on MRI imaging. She was started on trametinib at 0.5 mg once daily. Four weeks later, the dose was escalated to 0.5 mg twice daily which she remains on. Dosing was based on phase 2 studies in pediatric patients with solid tumors [1].

Medical treatment options are limited for AVMs, and surgery carries a high risk of recurrence and disease progression [2]. Since AVMs frequently undergo rapid progression, complete surgical excision requires extensive and high-risk procedures, if even technically possible. Endovascular embolization with alcohol may offer another treatment approach; however, a large lesion like this requires multiple embolizations with the risk of possible stroke, skin pruritus, mucosal breakdown, and significant radiation exposure [3]. Recently, mutations in different genes of the RAS/ MAPK pathway (BRAF, KRAS, NRAS, MAP2K1) have been detected in patients with vascular malformations [4]. A study showed that somatic mutations in the MAP2K1 gene (mitogen activated protein kinase kinase 1) cause extracranial AVMs [5]. Since this gene encodes for MAP-extracellular signal regulated kinase one (MEK1), targeted agents such as trametinib are a treatment option for these malformations.

This article is protected by copyright. All rights reserved.

Author Manuscript

Our patient was initiated on trametinib given her refractory clinical course, need for frequent surgical intervention, lack of other medical options, and impending puberty likely to accelerate AVM growth. Since starting therapy at the age of 11, her bleeding symptoms have dramatically reduced in volume and frequency which has led to less procedural intervention. The patient and her parents are pleased with the lighter appearance of her skin and quiescence of the malformation despite being well within puberty. Figure 1 shows the right hemiface before (1A) and two years after trametinib therapy (1B). The vessels on the right hemiface appear less engorged (Fig 1B). She has tolerated the medication well over the last 36 months with minimal side effects including hair lightening and low volume hair loss. Common side effects with trametinib include headache, cutaneous and gastrointestinal toxicity, alopecia, paronychia, pyrexia, and cytopenias, based on case reports in AVM patients [6,7] and use in pediatric cancers [1] . Ocular complications including uveitis, retinopathy and cardiac dysfunction have also been reported with MEK inhibitors [1,8]. Her blood counts, liver and kidney function tests, and coagulation studies have remained normal over the last three years (supplemental table S1). Echocardiograms and ophthalmologic exams performed while she has been treated with trametinib have been normal. The appearance of the internal component of her AVM is improved, based on serial OTO-HNS evaluations by the senior author via flexible laryngoscopy. Our team has not had tracheostomy discussions for several years. The AVM has not demonstrated any evidence of progression based on clinical exam or imaging (Figures 2A, 2B and 2C) since she started trametinib.

Our case report is the first to describe treatment of an extensive AVM in the aerodigestive tract preventing the need for tracheostomy. To our knowledge, this is the longest period reported about the use of trametinib in a patient with extensive

This article is protected by copyright. All rights reserved.

Author Manuscript

cervicofacial AVM and supports its clinical benefit and safety. It highlights the importance of timely genetic testing in patients with vascular anomalies since it can lead to life altering therapies. Further research is needed to advance our understanding about the safety, optimal dosing, and duration of therapy with these agents.

Conflict of Interest Statement: The authors report no conflicts of interest.

Ethics Statement: Informed consent was obtained from the parent of the patient prior to writing this paper and it has been documented in her medical chart.

Acknowledgements:

The authors would like to thank and acknowledge Drs James Bennett and Jonathan Perkins at Seattle Children`s Hospital for genetic sequencing and biologic guidance. The authors would like to acknowledge Dr. Rajen Mody at the University of Michigan for guidance about dosing of MEK inhibitors.

REFERENCES:

1. Bouffet E, Geoerger B, Moertel C, et al. Efficacy and Safety of Trametinib Monotherapy or in Combination With Dabrafenib in Pediatric BRAF V600-Mutant Low-Grade Glioma. *J Clin Oncol*. Jan 20 2023;41(3):664-674. doi:10.1200/JCO.22.01000
2. Liu AS, Mulliken JB, Zurakowski D, Fishman SJ, Greene AK. Extracranial arteriovenous malformations: natural progression and recurrence after treatment. *Plast Reconstr Surg*. Apr 2010;125(4):1185-1194. doi:10.1097/PRS.0b013e3181d18070
3. Dmytriw AA, Ter Brugge KG, Krings T, Agid R. Endovascular treatment of head and neck arteriovenous malformations. *Neuroradiology*. Mar 2014;56(3):227-36. doi:10.1007/s00234-014-1328-0
4. Al-Olabi L, Polubothu S, Dowsett K, et al. Mosaic RAS/MAPK variants cause sporadic vascular malformations which respond to targeted therapy. *J Clin Invest*. Nov 1 2018;128(11):5185. doi:10.1172/JCI124649
5. Couto JA, Huang AY, Konczyk DJ, et al. Somatic MAP2K1 Mutations Are Associated with Extracranial Arteriovenous Malformation. *Am J Hum Genet*. Mar 2 2017;100(3):546-554. doi:10.1016/j.ajhg.2017.01.018
6. Nicholson CL, Flanagan S, Murati M, et al. Successful management of an arteriovenous malformation with trametinib in a patient with capillary-malformation arteriovenous malformation syndrome and cardiac compromise. *Pediatr Dermatol*. Mar 2022;39(2):316-319. doi:10.1111/pde.14912

This article is protected by copyright. All rights reserved.

Author Manuscript

7. Lekwuttikarn R, Lim YH, Admani S, Choate KA, Teng JMC. Genotype-Guided Medical Treatment of an Arteriovenous Malformation in a Child. *JAMA Dermatol*. Feb 1 2019;155(2):256-257. doi:10.1001/jamadermatol.2018.4653
8. Du Y, Hu YT. Association of bilateral pan-uveitis with the use of trametinib for Langerhans cell histiocytosis. *Am J Transl Res*. 2022;14(12):8768-8772.

Figure Legends:

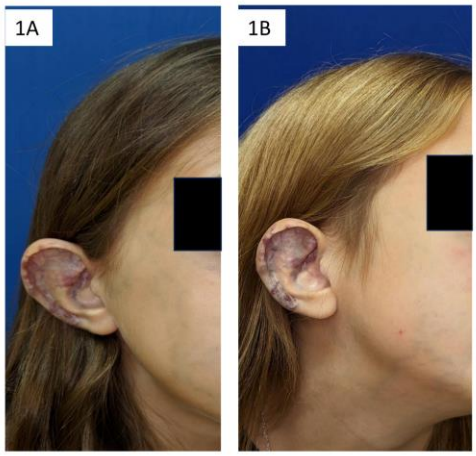

Figure 1: Right Oblique view of the hemiface, pre trametinib (Fig 1A) and 2 years post trametinib therapy (Fig 1B). Note vessels on the right hemiface and auricle in Fig 1B appear less engorged and prominent.

This article is protected by copyright. All rights reserved.

Author Manuscript

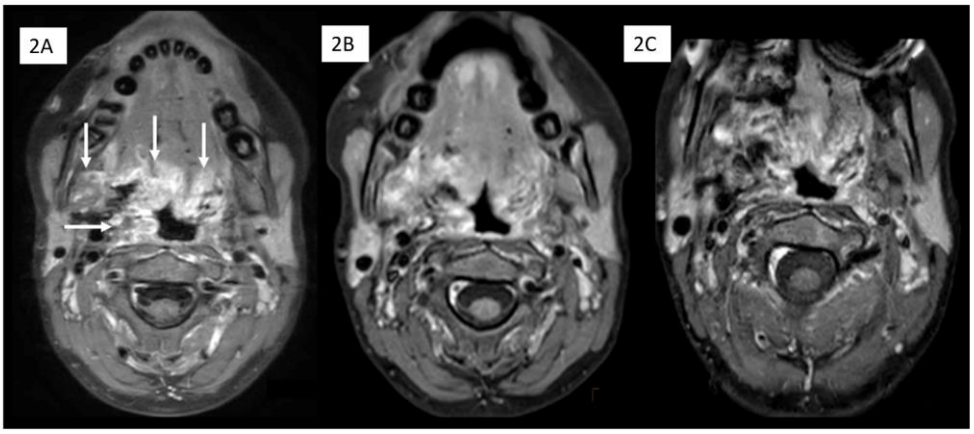

Figure 2: Serial post-contrast enhanced T1 weighted MRI images with fat suppression at the level of oral cavity from 6/2021 (2A), 6/2022 (2B) and 9/2023 (2C) show enhancing and serpiginous vascular malformation involving the base of tongue and pharyngeal wall (arrows in A). Additional involvement was noted within larynx, bilateral carotid, and right masticator spaces (not shown). Overall, there was stability of this malformation from 06/2021 until 09/2023.

This article is protected by copyright. All rights reserved.