Dental Long Axes using Digital Dental Models Compared to Cone-Beam Computed Tomography

Running title: Dental Long Axes in Digital Models

Amalia Cong
DDS; Orthodontic Resident
Department of Orthodontics and Pediatric Dentistry, School of Dentistry, University of Michigan, Ann Arbor, MI, United States

Camila Massaro
DDS, MS; Visiting Scholar and PhD Student
Department of Orthodontics, Bauru Dental School, University of São Paulo, Bauru, São Paulo, Brazil, SP, Brazil

Antonio Carlos de Oliveira Ruellas
DDS, MS, PhD; Professor
Department of Orthodontics, School of Dentistry, Federal University of Rio de Janeiro, Rio de Janeiro, RJ, Brazil
Associate Professor
Department of Orthodontics and Pediatric Dentistry, School of Dentistry, University of Michigan, Ann Arbor, MI, United States

Mary Barkley
DDS, MS; Adjunct Clinical Assistant Professor
Department of Orthodontics and Pediatric Dentistry, School of Dentistry, University of Michigan, Ann Arbor, MI, United States

Marilia Yatabe

Author Manuscript

This is the author manuscript accepted for publication and has undergone full peer review but has not been through the copyediting, typesetting, pagination and proofreading process, which may lead to differences between this version and the Version of Record. Please cite this article as doi: 10.1111/OCR.12489

This article is protected by copyright. All rights reserved

DDS, MS, PhD; Clinical Assistant Professor
Department of Orthodontics and Pediatric Dentistry, School of Dentistry, University of Michigan, Ann Arbor, MI, United States

Jonas Bianchi
DDS, MS, PhD; Assistant Professor
Department of Orthodontics, University of the Pacific, Arthur A. Dugoni School of Dentistry, San Francisco, CA, United States

Marcos Ioshida
DDS, Restorative Resident
Department of Cariology, Restorative Sciences & Endodontics, School of Dentistry, University of Michigan, Ann Arbor, MI, United States

María Antonia Alvarez
DDS, MS; Department of Orthodontics, CES University, Medellin, Colombia

Juan Fernando Aristizabal
DDS, MS; Titular Professor
Department of Orthodontics, University of Valle, Cali, Colombia

Diego Rey
DDS; Associate Professor
Department of Orthodontics, CES University, Medellin, Colombia

Lucia Cevidanes
DDS, MS, PhD; Associate Professor
Thomas and Doris Graber Endowed Professor of Dentistry
Department of Orthodontics and Pediatric Dentistry, School of Dentistry, University of Michigan, Ann Arbor, MI, United States

Author Manuscript

This article is protected by copyright. All rights reserved

Corresponding Author

Lucia Cevidanes

University of Michigan School of Dentistry

1011 North University Avenue

Ann Arbor, MI 48109 -1078

United States

Telephone: (919) 3578603

E-mail: luciacev@umich.edu

Author Manuscript

This article is protected by copyright. All rights reserved

DR CAMILA MASSARO (Orcid ID : 0000-0001-6011-7946)
DR MARILIA YATABE (Orcid ID : 0000-0002-8748-6714)
DR JONAS BIANCHI (Orcid ID : 0000-0002-3749-0918)
DR MARÍA ANTONIA ÁLVAREZ (Orcid ID : 0000-0002-2710-7428)
DR JUAN ARISTIZABAL (Orcid ID : 0000-0003-4391-7188)
DR LUCIA CEVIDANES (Orcid ID : 0000-0001-9786-2253)

Article type : Original Article

Dental Long Axes using Digital Dental Models Compared to Cone-Beam Computed Tomography

Abstract

Objective

Standard methods of evaluating tooth long axes are not comparable (digital dental models [DDMs], panoramic and cephalometric radiographs) or expose patients to more radiation (cone-beam computed tomography [CBCT]). This study aimed to compare angular changes in tooth long axes using DDMs versus using CBCTs.

Settings and sample population

Secondary data analysis of DDMs and CBCTs, taken before and after orthodontic treatment with piezocision of 24 patients.

Methods

Angular changes in tooth long axes were evaluated using landmarks on first molars (center of the occlusal surface and center of the furcation), canines and incisors (cusp tip and center of the root at the cementoenamel junction). Wilcoxon test, intraclass correlation coefficient (ICC) and Bland-Altman plots were used to test intra- and inter-rater agreement and compare DDM and CBCT measurements.

This article is protected by copyright. All rights reserved

Author Manuscript

Results

The mesiodistal angulation and buccolingual inclination DDM measurements were reproducible. Overall mean differences between DDM and CBCT measurements of mesiodistal angulation, 1.9°±1.5°, and buccolingual inclination, 2.2±2.2°, were not significant for all teeth. ICC between DDM and CBCT measurements ranged from good (0.85 molars) to excellent (0.94 canines; 0.96 incisors). The percentages of measurements outside the range of ±5 were 17.4% for molars, 13.8% for canines, and 4.5% for incisors.

Conclusions

DDM assessment of changes in tooth long axes has good reproducibility and yields comparable measurements to those obtained from CBCT within a 5° range. These findings lay the groundwork for machine learning approaches that synthesize crown and root canal information towards planning tooth movement without the need for ionizing radiation scans.

Key words:

Dental long axis, digital dental models, CBCT

Introduction

Proper placement of the entire tooth is crucial to treatment planning tooth movement, monitoring and maintaining periodontal health,[1] attaining stable treatment outcomes and occlusal function,[2] and satisfying Andrews' six keys to normal occlusion.[3] An understanding of angular changes in tooth long axes due to orthodontic treatment and/or ageing yields clinical insights to the three-dimensional positioning of the whole tooth.[4] In 1972, Dr. Larry Andrews pioneered the assessment of dental long axes angulation using the clinical crown in dental casts.[3,5] However, the methodology relied on a tangent line to the buccal crown contour, making it technically challenging and calling into question its reproducibility and robustness to anatomical variations.[3,5]

Angular changes in tooth long axes can be mesiodistal or buccolingual. Mesiodistal changes are typically assessed with panoramic radiography.[6] Nonetheless, panoramic x-rays have inherent image distortions from incorrect focal trough size and shape, projection effects from non-orthogonal

This article is protected by copyright. All rights reserved

Author Manuscript

x-rays beams directed at teeth, and errors in head positioning.[7-9] Buccolingual inclination of incisors[10] and molars can be evaluated using, respectively, lateral and posteroanterior cephalograms; but 2D cephalometric measurements are subject to tracing and landmark identification errors,[11] structural superimpositions, inconsistencies with radiographic equipment, patient positioning, and/or distortion due to patient movement.[12] In contrast, cone-beam computed tomography (CBCT) scans accurately evaluate root positions, dental buccolingual and mesiodistal angulations, and dentofacial structures.[13-15] However, the associated radiation dose demands prudence in prescribing CBCTs, especially in children, as multiple scans may be required.[16] Alternative techniques merge CBCTs with digital dental models (DDMs) and create setups to assess root position post-treatment.[17-18]

Digital dental models accurately evaluate clinical crown position in three-dimensions without radiation exposure to the patient.[19] Several commercial software now allow estimation of tooth roots position from the crown position in the DDM; however, the current tools use the crown buccal surface for estimation of the root position and have not yet been validated. Massaro el al[4] investigated changes in tooth long axes derived from the buccal surfaces of crowns in DDMs and occlusal/incisal surface and root apex in CBCT scans and reported significant differences when using DDMs compared to CBCT measurements. For these reasons, there is an unmet clinical need to elucidate the similarity of estimations of root position and angulation in DDM compared to CBCT as the gold standard. The present study does not utilize the buccal crown surface as a reference to estimate root position. This study proposes and evaluates a new method for assessing angular changes in tooth long axes using the occlusal surface and the furcation or mid-point at the cementoenamel junction level, comparing DDMs measurements to those calculated from CBCTs. We hypothesize that measurements of the dental long axes angular changes derived from an axis through the center of dental crowns in DDMs are comparable to CBCTs.

Material and Methods

The methodology described for this retrospective secondary data analysis was approved by and granted IRB exemption (HUM00167839) from the University of Michigan. The study sample consisted of before treatment (T1) and after treatment (T2) CBCT scans and DDMs of 24 consecutive patients that were prospectively collected in a previous study on treatment outcomes of

This article is protected by copyright. All rights reserved

Author Manuscript

piezocision,[20] where mandibular post treatment CBCTs were acquired to determine treatment response to mucograft as part of an ethically approved and registered clinical trial. The mean age of the sample was 22 years, ranging from 17 to 35 years old, with Angle's Class I and mild Class II or III malocclusion, moderate mandibular anterior crowding and healthy periodontium, who underwent orthodontic treatment with passive self-ligating bracket system (Damon SL; Ormco, Orange, Calif) for 13.9± 5.5 months.

The mandibular small field of view CBCTs used for the analysis were not acquired for the purpose of the present study. The available scans had been acquired adjusting parameters to reduce ionizing radiation effects following the as low as diagnostically acceptable principles,[21] using the Veraviewepocs 3D R100 (J Morita Corp, Tokyo, Japan) following the acquisition protocol: 90 kV; 3-5 mA; 0.16-mm^3 voxel size; scan time, 9.3 seconds; and field of view of 100X 80 mm. The DDMs were acquired with the TRIOS 3D intraoral scanner (version 1.3.4.5; 3Shape, Copenhagen, Denmark) with an accuracy of 6.9± 0.9 μm. The sample size was determined using preliminary statistics derived from a 10-patient subsample.[4] For a standard deviation of 6.5° for the buccolingual inclination of canines, and a minimal difference between the two methods of 4° to be detected, a sample of 23 was required to provide 80% statistical power with α of 5%.[4]

The image processing procedures followed previously published methods,[4,22-24] using 2 open-source software (ITK-SNAP,[25] version 2.4.0, www.itksnap.org, and 3D SlicerCMF,[26] version 4.0) for construction of 3D volumetric label maps, orientation of mandibular surface models, manual approximation, voxel-based registration of CBCTs, and landmark-based registration of the DDMs to the registered CBCTs.

The quantitative methods tested in the present study for measuring dental long axis are as follows:

1. Pre-labeling: Twelve 3D landmarks were placed on the oriented (T1) and registered (T2) segmentations obtained from the CBCTs by changing the color of the label without modifying the dental anatomy. Two landmarks used to generate the tooth long axes were positioned on each of the following teeth, bilaterally: first molar (center of the occlusal surface and center of the furcation), canine (cusp tip and center of the root at the level of the cementoenamel junction [CEJ]), and central incisor (center of the incisal edge and center of the root at the level of the CEJ), as shown in Figure 1.

This article is protected by copyright. All rights reserved

Author Manuscript

The center of the root at the furcation or CEJ levels were selected instead of the root apex to avoid the frequently observed curvature in root morphology, possible root dilacerations and/or resorptions or incomplete root development.

2. For DDMs, both T1 and T2, landmarks were placed on the first molars, canines, and central incisors, bilaterally), using the "Quantification of 3D Components" (Q3DC) tool.[20] For each tooth, two landmarks were placed on the cervical part of the crown just above the gingival margin (midpoint of the buccal and midpoint of the lingual). The midpoint of these two cervical landmarks, is defined in this study as the "centroid" of the tooth (Figure 1). A third point was placed on each tooth: the center of the occlusal surface for the molar, the cusp tip for the canine, and the center of the incisal edge for the incisor, as shown on Figure 1. The predicted long axis was generated from this third occlusal/incisal landmark and the centroid generated from the first two cervical landmarks.

3. Measurements were performed using the Q3DC tool[20] to compare the changes in buccolingual inclination and mesiodistal angulation between T1 and T2 generated from DDMs versus CBCTs (Figure 2). The two operators (AC and CM) were trained and calibrated before measuring.

Statistical analysis:

To evaluate the intra-rater agreement of DDM, rater 1 (AC) repeated 30% of the measurements after a waiting period of 2 weeks. To determine the inter-rater agreement, rater 2 (CM) measured the same sample. Intra and inter-rater agreement were tested by using the intraclass correlation coefficient (ICC), absolute agreement at a 95% confidence interval, and Bland-Altman plots.[27] Non-parametric tests were performed to compare DDM and CBCT methods, since Kolmogorov-Smirnov tests showed a non-normal distribution for 4 out of the 12 variables analyzed. The two-tailed Wilcoxon test ($P<.05$) was used to determine statistical significance in the differences between data obtained from DDMs and CBCTs. Bland-Altman plots were used to illustrate the comparison between DDM and CBCT assessments. All statistical analyses were performed by IBM SPSS Statistics software (version 26.0.0.1; SPSS Inc., Chicago, IL, USA). Bland-Altman plots were generated by GraphPad Prism 8 (version 8.4.3; GraphPad Software, LLC, San Diego, CA, USA).

Results

This article is protected by copyright. All rights reserved

Author Manuscript

The Wilcoxon test showed no difference when comparing left and right sides; therefore, the data were pooled together for subsequent analyses.

The ICCs varied from 0.72 to 0.98 for intra-rater agreement and from 0.67 to 0.88 for inter-rater agreement. All variables had good to excellent intra-rater agreement, except for molar mesiodistal angulation, which had moderate agreement. For inter-rater reproducibility, all variables had good agreement, except for molar mesiodistal angulation and incisor buccolingual inclination, which had moderate agreement.

The differences between measurements obtained from the DDMs and the CBCTs were not statistically significant (Table 1). When comparing the measurements obtained from the DDMs versus the CBCTs, both mesiodistal and buccolingual angular changes for molars showed good agreement, while all other variables showed excellent agreement, with ICCs ranging from 0.82 to 0.99. The mean angular changes from T1 to T2 were the smallest for molars (<0.2° average change for both mesiodistal and buccolingual measurements) and largest for canine mesiodistal angular change (averaging around 5° of proclination).

Figures 3 and 4 show the Bland-Altman plots for intra and inter-rater reproducibility, and comparison of measurements, in degrees, obtained from DDMs and CBCTs for each tooth type and movement. For each plot, the x-axis represents the mean of the compared measurements, and the y-axis represents the difference between the compared measurements. The black dotted line represents the bias, and the red dotted lines represent the upper and lower limits of agreement.

The means and standard deviations of the difference between the DDMs and CBCTs measurements for operator 1 are shown in Table 2. The overall mean differences were 1.9° ± 1.5° of all measurements for mesiodistal angulation and 2.2° ± 2.2° for buccolingual inclination. The percentages of difference in measurements between the DDMs and the CBCTs outside the ±2.5° or ±5° clinically acceptable ranges, are reported in Table 2.

Author Manuscript

Discussion

Proper root position is one of the requirements for orthodontic treatment success as determined by the American Board of Orthodontics.[28] DDMs are reliable for measuring tooth size,

This article is protected by copyright. All rights reserved

arch dimensions, and irregularity index.[29-30] It behooves orthodontic professionals to explore the potential wealth of DDM data and extract clinically meaningful information, one of which may be the angular changes in dental long axes during orthodontic treatment, as a proxy for predicting root position, which is critical in planning tooth movements before and during treatment. Current commercial software such as OrthoAnalyzer® (3Shape A/S, Denmark)[31], iTero® (Align Technology, Inc., California)[32] and ArchForm[33] among others use artificial intelligence to automatically locate landmarks that clinicians can visually edit in the buccal surface of DDMs and then estimate the tooth long axis. However, the virtual simulation of the tooth long axis has not yet been validated.
The present study is the first step to integrate information from DDMs and CBCTs, using CBCT as the gold standard, in a secondary analysis of available data sets. This study evaluated the reproducibility of a new method to measure angular changes in tooth long axes on DDMs, compared with measurements obtained from CBCT scans.

The Bland-Altman plots for inter- and intra-rater reliability testing had biases that were close to zero (Figure 3), with most points within upper and lower limits of agreement of 5 degrees, demonstrating that the mesiodistal angulation and buccolingual inclination measurements by the two operators were reproducible between and within them. Intra-rater reliability (ICC range: 0.72-0.98) and inter-rater reliability (ICC range: 0.67-0.88) were consistent with other studies.[4,17]

For all tooth and movement types investigated, no significant differences were observed between measurements obtained from DDMs and CBCTs (Table 1). ICC agreement between DDM and CBCT measurements ranged from good (0.85 for molars) to excellent (0.94 for canines; 0.96 for incisors). The Bland-Altman plots[34-5] indicate that most differences between DDM and CBCT measurements for all tooth types are within 5 degrees, with a few outliers (Figure 4). These findings differ from those reported by Massaro et al[4] who used the buccal crown surfaces of DDMs to estimate the long axis and observed that changes in angular measurements were discordant when measured in the digital models (clinical crown) and in the CBCT images (whole tooth).

The present study considered the percentages of measures between a range of 2.5° and between 5° (Table 2). Approximately 31% of mesiodistal angulation measurements and 33% of buccolingual inclination measurements were outside the ±2.5° range. By tooth type, 42.9% of molar measurements, 36.6% of canine measurements, and 18.8% of central incisor measurements were outside the ±2.5° range. When we extend the range to ±5°, then the percentage of measurements

This article is protected by copyright. All rights reserved

Author Manuscript

falling outside the range drops to a mean of 17.4% for molars, 13.8% for canines, and 4.5% for incisors. The mean differences between measurements from DDMs and CBCT scans were 1.9° ± 1.5° for mesiodistal angulation and 2.2° ± 2.2° for buccolingual inclination. Previous studies that used panoramic radiographs and therefore have other intrinsic errors, considered a clinical acceptability range of 2.5° for assessment of root angulation, with 53% to 73% of root angulations falling outside this clinically acceptable range when measured.[8-9] In the study of Lee at al,[17] the average of 5 times repeated measurements was used to compare post-treatment setups to post-treatment CBCTs, with a 2.5° clinically acceptable range.

In this study, pre- and post-treatment CBCT models were first superimposed using the mandibular regional voxel-based registration methods, validated by Ruellas et al.[23] DDMs were then superimposed to the CBCT models.[22] Clinically, the before and after treatment registration of the DDMs validated by Ioshida et al[22] does not require a pretreatment CBCT. If CBCT images are not taken, the pre- and post-treatment DDMs can be directly superimposed using stable reference anatomical landmarks in the intraoral scan, such as the mucogingival junction for the mandibular models[22] and the palatal rugae for maxillary models.[36] While DDM superimposition methods using these landmarks have been validated and can be performed quickly, it adds an extra step. One recent innovation along this vein is the iTero® Element TimeLapse.[37] However, the structures of reference used for registration and quantification approaches in commercial software have not yet been investigated and their clinical validity remains unknown. The superimposition of teeth between timepoints using whole crown surface anatomies has been proposed by Lee et al,[38] with superimposition of each crown individually in the initial DDM to CBCT, as well as in progress and final DDMs to the setup. In that method[17,38] as long as the patient has a pretreatment CBCT and pretreatment DDM, then the root position setup can be generated, and at any time during treatment when a DDM is taken, each crown on a treatment progress DDM can be superimposed individually to the root position setup, in such a way that the root positions mid-treatment can be evaluated without a mid-treatment CBCT or panoramic x-ray.

A limitation of this study was that we did not assess axial rotations. However, rotational movement can create challenges in landmark placement on DDMs, as the gingival contour may change significantly with derotation. Therefore, if a tooth was initially severely rotated, we must

This article is protected by copyright. All rights reserved

Author Manuscript

interpret the result with caution. In fact, a previous study has even excluded teeth with severe rotations when performing angulation assessment.[39] Upon inspection, many of the outliers found in this study are associated with severe rotation in the initial malocclusion, but we decided to include all the teeth in the sample to more accurately represent clinical situations. As always, practitioners should exercise their best clinical judgment when using DDMs in the clinic to assess long axes changes and predict root positions. Another limitation is that the method may not be accurate in the case of significant attrition, fracture, or restorations on the cusp tips, incisal edges, or if gingival recession occurs during orthodontic treatment after the initial DDM was acquired.

This study presents a new method for precise quantification of Andrew's keys of occlusion for angular and torque changes of the dental long axis, not the crown buccal surface, using DDMs. Outliers can occur, however, meaning this new method merits further refinement using machine learning approaches and practitioners' best judgment when applied in a clinical setting. While the unique non-extraction sample had available previously acquired small field of view high-resolution CBCTs, the estimation of the dental long axis using DDMs is much improved with the new methods presented here. Ongoing work machine learning approaches[40] are refining the methods presented in this study to synthesize information from crown, root, and root canal morphology towards planning tooth movement without the need for ionizing radiation scans. Such advances will be applicable to the evaluation of biomechanics of tooth movement with any treatment modality, and generalizable for planning crown restorations and implant loading axes. Future studies to assess teeth with greater angular changes between two time points may further elucidate the combined effect of multiple tooth movements and patterns of displacement.

Conclusions

The proposed DDM method of assessing changes in tooth long axes has good intra- and inter-rater reproducibility and yields comparable measurements to those obtained from CBCT within a 5° range. The results from this study lay the groundwork for machine learning approaches that synthesize information from crown and root canal morphology towards understanding dental movement for each patient without the need for ionizing radiation scans.

Acknowledgments

This article is protected by copyright. All rights reserved

Author Manuscript

Supported by NIDCR R01DE024550 and AAOF 2020 B.F. Dewel Memorial Biomedical Research Award.

References

1. Vermylen K, De Quincey GN, van't Hof MA, Wolffe GN, Renggli HH. Classification, reproducibility and prevalence of root proximity in periodontal patients. J Clin Periodontol 2005; 32:254-9.
2. Dewel BF. Clinical observations on the axial inclination of teeth. Am J Orthod 1949; 35:98-115.
3. Andrews LF. The six keys to normal occlusion. Am J Orthod 1972; 62:296-309.
4. Massaro C, Losada C, Cevidanes L, et al. Comparison of linear and angular changes assessed in digital dental models and cone-beam computed tomography. Orthod. Craniofacial Res. 2020; 23(1):118–28.
5. Andrews LF. The straight-wire appliance. Explained and compared. J Clin Orthod. 1976;10(3):174-195.
6. Keim RG, Gottlieb EL, Nelson AH, Vogels DS. 2008 JCO study of orthodontic diagnosis and treatment procedures, part 1: results and trends. J Clin Orthod 2008; 42:625-40.
7. Lagravere MO, Carey J, Toogood RW, Major PW. Three-dimensional accuracy of measurements made with software on conebeam computed tomography images. Am J Orthod Dentofacial Orthop 2008; 134:112-6.
8. Mckee IW, Glover KE, Williamson PC, Lam EW, Heo G, Major PW. The effect of vertical and horizontal head positioning in panoramic radiography on mesiodistal tooth angulations. Angle Orthod 2001; 71:442-51.
9. Owens AM, Johal A. Near-end of treatment panoramic radiograph in the assessment of mesiodistal root angulation. Angle Orthod 2008; 78:475-81.
10. Jabbal A, Cobourne M, Donaldson N, Bister D. Assessing lower incisor inclination change: a comparison of four cephalometric methods. Eur J Orthod 2016; 38(2):184-9.
11. Major PW, Johnson DE, Hesse KL, Glover KE. Landmark identification error in posterior anterior cephalometrics. Angle Orthod. 1994; 64:447–54.
12. Malkoc S, Sari Z, Usumez S, Koyuturk AE. The effect of head rotation on cephalometric radiographs. Eur J Orthod. 2005; 27:315–21.

This article is protected by copyright. All rights reserved

Author Manuscript

13. Tong H, Enciso R, Van Elslande D, Major PW, Sameshima GT. A new method to measure mesiodistal angulation and faciolingual inclination of each whole tooth with volumetric cone-beam computed tomography images. Am J Orthod Dentofacial Orthop. 2012; 142(1):133-143.
14. Bouwens DG, Cevidanes L, Ludlow JB, Phillips C. Comparison of mesiodistal root angulation with posttreatment panoramic radiographs and cone-beam computed tomography. Am J Orthod Dentofacial Orthop. 2011; 139(1):126-132.
15. Kim J, Heo G, Lagravere MO. Accuracy of laser-scanned models compared to plaster models and cone-beam computed tomography. Angle Orthod. 2014; 84(3):443-450.
16. Brooks SL. CBCT dosimetry: orthodontic considerations. Semin Orthod 2009; 15:14-8.
17. Lee RJ, Pi S, Park J, et al. Accuracy and reliability of the expected root position setup methodology to evaluate root position during orthodontic treatment. Am J Orthod Dentofacial Orthop. 2018;154(4):583-595.
18. Staderini E, Guglielmi F, Cornelis MA, Cattaneo PM. Three-dimensional prediction of roots position through cone-beam computed tomography scans-digital model superimposition: A novel method. Orthod Craniofac Res. 2019;22(1):16-23.
19. Burhardt L, Livas C, Kerdijk W, van der Meer WJ, Ren Y. Treatment comfort, time perception, and preference for conventional and digital impression techniques: a comparative study in young patients. Am J Orthod Dentofac Orthop. 2016;150:261–267.
20. Alvarez MA, Mejia A, Alzate D, Rey D, Ioshida M, Aristizabal JF, Rios HF, Bellaiza-Cantillo W, Tirado M, Ruellas A, Cevidanes L. Buccal bone defects and transversal tooth movement of mandibular lateral segments in patients after orthodontic treatment with and without piezocision: A case-control retrospective study. Am J Orthod Dentofacial Orthop. 2021;159(3):e233-e243.
21. Jaju PP, Jaju SP. Cone-beam computed tomography: time to move from ALARA to ALADA. Imaging Sci Dent 2015;45:263-5.
22. Ioshida M, Munoz BA, Rios H, et al. Accuracy and reliability of mandibular digital model registration with use of the mucogingival junction as the reference. Oral Surg Oral Med Oral Pathol Oral Radiol. 2019;127(4):351-360.
23. Ruellas AC, Yatabe MS, Souki BQ, et al. 3D mandibular superimposition: comparison of regions of reference for voxel-based registration. PLoS ONE. 2016;11(6):e0157625.
24. Ruellas AC, Huanca Ghislanzoni LT, Gomes MR, et al. Comparison and reproducibility of 2 regions of reference for maxillary regional registration with cone-beam computed tomography. Am J Orthod Dentofacial Orthop. 2016;149(4):533-542.

This article is protected by copyright. All rights reserved

Author Manuscript

25.Yushkevich PA, Gerig G. ITK-SNAP: an intractive medical image segmentation tool to meet the need for expert-guided segmentation of complex medical images. IEEE Pulse. 2017;8(4):54-57.
26. Slicer CMF. https ://sites.google.com/a/umich.edu/dentistry-imagecomputing/Download. Accessed March 15, 2020.
27. Bland JM, Altman DG. Statistical methods for assessing agreement between two methods of clinical measurement. Lancet. 1986;1(8476):307-310.
28.Casko JS, Vaden JL, Kokich VG, et al. Objective grading system for dental casts and panoramic radiographs. American Board of Orthodontics. Am J Orthod Dentofacial Orthop 1998;114:589-99.
29. Fleming PS, Marinho V, Johal A. Orthodontic measurements on digital study models compared with plaster models: a systematic review. Orthod Craniofac Res. 2011;14(1):1-16.
30. Cuperus AM, Harms MC, Rangel FA, Bronkhorst EM, Schols JG, Breuning KH. Dental models made with an intraoral scanner: a validation study. Am J Orthod Dentofacial Orthop. 2012;142(3):308-313.
31. OrthoAnalyzer®, 3shape, https://www.3shape.com/en/software/ortho-system. Accessed Jan 11, 2021.
32. Itero®, Align technology, https://itero.com/. Accessed on Jan 11, 2021.
33. ArchForm®, ArchForm, California, https://www.archform.co/. Accessed Jan 11, 2021.
34. Kalra, A. Decoding the Bland–Altman plot: Basic review. J Pract Cardiovasc Sci. 2017, 3:36-38.
35. Giavarina D. Understanding Bland Altman analysis. Biochem Med (Zagreb). 2015; 25:141-51.
36. Garib D, Miranda F, Yatabe MS, et al. Superimposition of maxillary digital models using the palatal rugae: Does ageing affect the reliability? Orthodontics & Craniofacial Research 2019;22(3):183-193.
37. iTero® Element. http://www.iterotimelapse.com/. Accessed Jan 11, 2021.
38. Lee RJ, Weissheimer A, Pham J, et al. Three-dimensional monitoring of root movement during orthodontic treatment. Am J Orthod Dentofacial Orthop. 2015;147(1):132-42.
39. Shewinvanakitkul W, Hans MG, Narendran S, Martin PJ. Measuring buccolingual inclination of mandibular canines and first molars using CBCT. Orthod Craniofac Res. 2011;14(3):168-174.
40. Dumont M, Prieto JC, Brosset S, et al. Patient Specific Classification of Dental Root Canal and Crown Shape. Shape Med Imaging (2020). 2020;12474:145-153.

Author Manuscript

This article is protected by copyright. All rights reserved

Tables

Table 1. Comparison and absolute agreement of CBCT and DDM measurements with Wilcoxon's test, and Intraclass Correlation (ICC)

	n	CBCT Mean (SD)	DDM Mean (SD)	Wilcoxon *P*-value	ICC	ICC 95% CI Lower-Upper	Agreement
Molar BL	48	-0.1 (5.0)	-0. (4.6)	0.89	0.82	0.68-0.90	Good
Molar MD	48	0.2 (4.2)	-0.2 (3.5)	0.35	0.87	0.78-0.93	Good
Canine BL	48	0.3 (5.5)	-0.6 (7.3)	0.16	0.93	0.87-0.96	Excellent
Canine MD	48	-5.0 (5.6)	-5.5 (5.3)	0.14	0.95	0.91-0.97	Excellent
Incisor BL	48	-2.5 (6.0)	-2.8 (6.2)	0.13	0.99	0.97-0.99	Excellent
Incisor MD	48	1.1 (4.4)	0.6 (4.6)	0.06	0.93	0.88-0.96	Excellent

Note: Angular measurements in degrees (°). Positive values (distal and lingual angulation changes) and negative values (mesial and buccal angulation changes).

Abbreviations: BL, buccolingual inclination; MD, mesiodistal angulation; CBCT, cone-beam computed tomography; DDM, digital dental model; ICC, intraclass correlation coefficient; r_s, Spearman's correlation coefficient; SD, standard deviation. Statistically significant at $P < 0.05$.

Table 2. Differences between CBCT measurements and DDM measurements

Tooth and Movement	Mean Absolute Difference	Difference by Tooth	Difference by Movement	Measurements > ±2.5°					Measurements > ±5°				
				Operator 1 Set 1; n=48	Operator 1 Set 2; n=16	Operator 2 n=48	Pooled n=112	By tooth n= 224	Operator 1 Set 1; n=48	Operator 1 Set 2; n=16	Operator 2 n=48	Pooled n=112	By tooth n= 224
Molar BL	2.7° ± 2.8°	Molars: 2.3° ± 2.3°	BL: 2.2° ± 2.2°	19 (39.58%)	7 (43.75%)	23 (47.92%)	49 (43.75%)	Molars: 96 (42.86%)	5 (10.42%)	3 (18.75%)	10 (20.83%)	18 (16.07%)	Molars: 39 (17.41%)
Molar MD	1.9° ± 1.6°			17 (35.42%)	3 (18.75%)	27 (56.25%)	47 (41.96%)		3 (6.25%)	0 (0%)	18 (37.50%)	21 (18.75%)	
Canine BL	2.7° ± 2.1°	Canines: 2.3° ± 1.9°		19 (39.58%)	8 (50.00%)	20 (41.67%)	47 (41.96%)	Canines: 82 (36.61%)	8 (16.67%)	3 (18.75%)	7 (14.58%)	18 (16.07%)	Canines: 31 (13.84%)
Canine MD	1.9° ± 1.5°		MD: 1.9° ± 1.5°	13 (27.08%)	2 (12.50%)	20 (41.67%)	35 (31.25%)		4 (8.33%)	2 (12.50%)	7 (14.58%)	13 (11.61%)	
Incisor BL	1.20° ± 0.9°	Incisors: 1.5° ± 1.2°		6 (12.50%)	0 (0%)	11 (22.92%)	17 (15.18%)	Incisors: 42 (18.75%)	2 (4 .17%)	0 (0%)	2 (4.17%)	4 (3.57%)	Incisors: 10 (4.46%)
Incisor MD	1.8° ± 1.4°			9 (18.75%)	1 (6.25%)	15 (31.25%)	25 (22.32%)		4 (8.33%)	1 (6.25%)	1 (2.08%)	6 (5.36%)	

This article is protected by copyright. All rights reserved

Author Manuscript

Total		83 (28.82%)	21 (21.88%)	116(40.28%)	220 (32.74%)		26 (9.03%)	9 (9.38%)	45 (15.63%)	80 (11.90%)	

Abbreviations: BL, buccolingual inclination; MD, mesiodistal angulation.

Author Manuscript

Figure Legends

Figure 1. Root morphology and choice of landmarks to quantify tooth long axis in the CBCT images and DDMs. Note that the natural curvature commonly observed in the root morphology of posterior (**A**) and (**B**) anterior teeth make the root apex not representative of the dental long axis. **C, D and E**, dental long axis of the incisor; **F, G and H**, dental long axis of the canine; **I, J and K**, dental long axis of the first molar. Note that in the CBCT images (**C, F and I)** the landmarks are placed on the occlusal/incisal surface and at the root canal/furcation level; in DDMs (**D, E, G, H, J and K**) the landmarks are placed on the occlusal/incisal surface and at the gingival level. The red and green dots represent surface landmarks; yellow dots represent the midpoints of the two green dots; the dental long axis is formed by the red and yellow dots.

Figure 2. Quantification of dental long axes in DDMs. The red and green dots represent surface landmarks; yellow dots represent the midpoints of the two green dots; the dental long axis is formed by the red and yellow dots**. A**, occlusal view of the dental long axis of first molars, canines and incisors; **B and C,** dental long axes for mandibular central incisor at T1 and T2; **D and E,** dental long axes for the first molar at T1 and T2; **B and D**, mesiodistal angulation; **C and E**, buccolingual inclination.

Figure 3. Bland-Altman plots for intra and inter-rater reliability of DDM measurements.

Figure 4. Bland-Altman plots for measurements obtained from CBCT versus DDM.

This article is protected by copyright. All rights reserved

Author Contribution

Fangdi Cong: Formal analysis, Investigation, Methodology, Project administration, Writing original draft. **Camila Massaro**: Conceptualization, Formal analysis, Investigation, Methodology, Project administration, Writing – review & editing. **Antonio Ruellas:** Conceptualization, Formal analysis, Investigation, Methodology, Project administration, Writing – review & editing. **Mary Barkley:** Conceptualization, Writing – review & editing. **Marilia Yatabe:** Conceptualization, Writing – review & editing. **Jonas Bianchi:** Conceptualization, Statistical Methodology, Writing – review & editing. **Maria Antonia Alvarez:** Data curation, Writing – review & editing. **Juan Fernando Aristizabal:** Data curation, Writing – review & editing. **Diego Rey:** Data curation, Writing – review & editing. **Lucia Cevidanes:** Conceptualization, Formal analysis, Investigation, Methodology, Funding acquisition, Project administration, Software, Writing – review & editing.

Conflict of Interest Statement

The authors declare no potential conflicts of interest with respect to the authorship and/or publication of this article.

Data Availability Statement

The data that support the findings of this study are available on request from the corresponding author. The data are not publicly available due to privacy or ethical restrictions.

Author Manuscript

This article is protected by copyright. All rights reserved

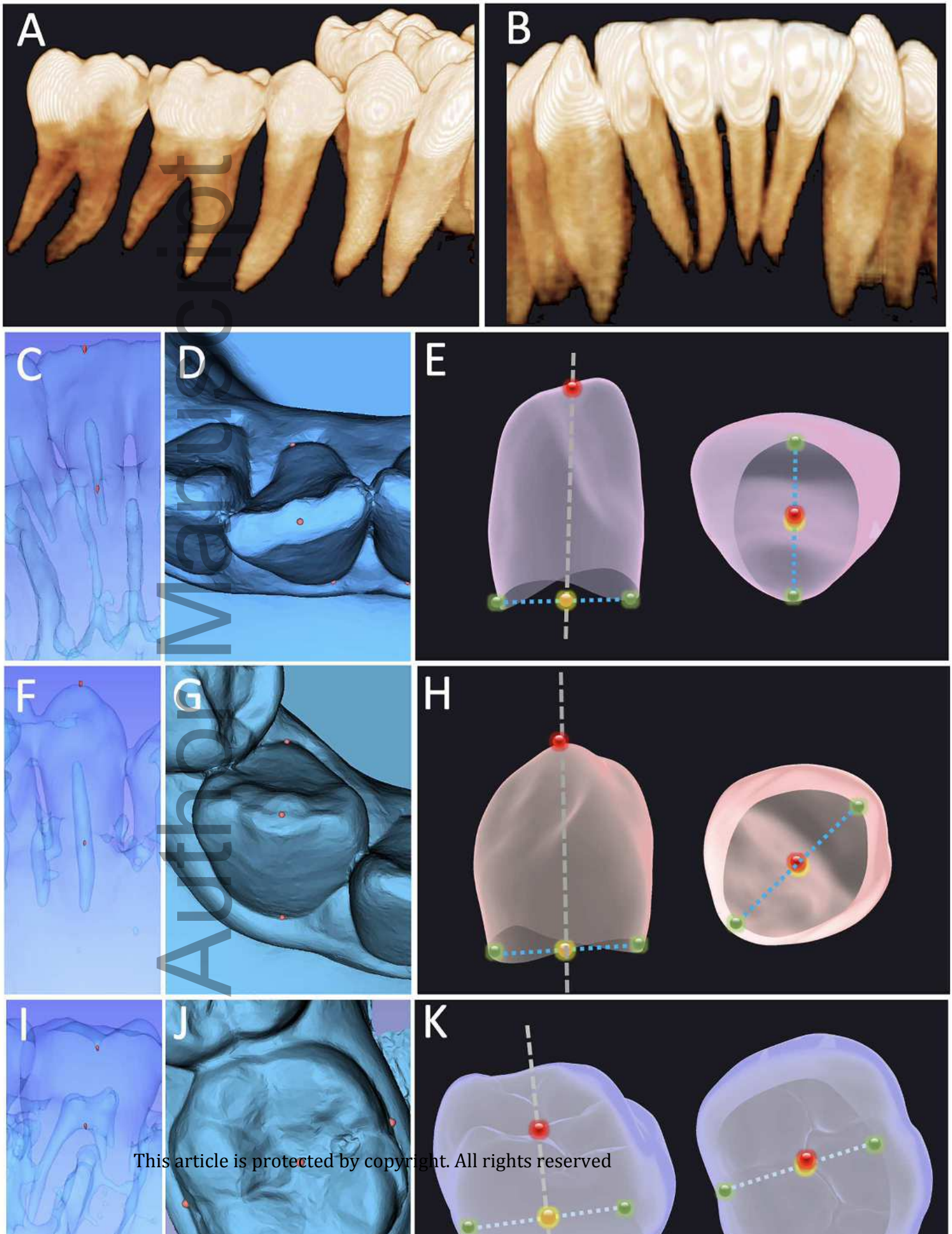

Author Manuscript

This article is protected by copyright. All rights reserved

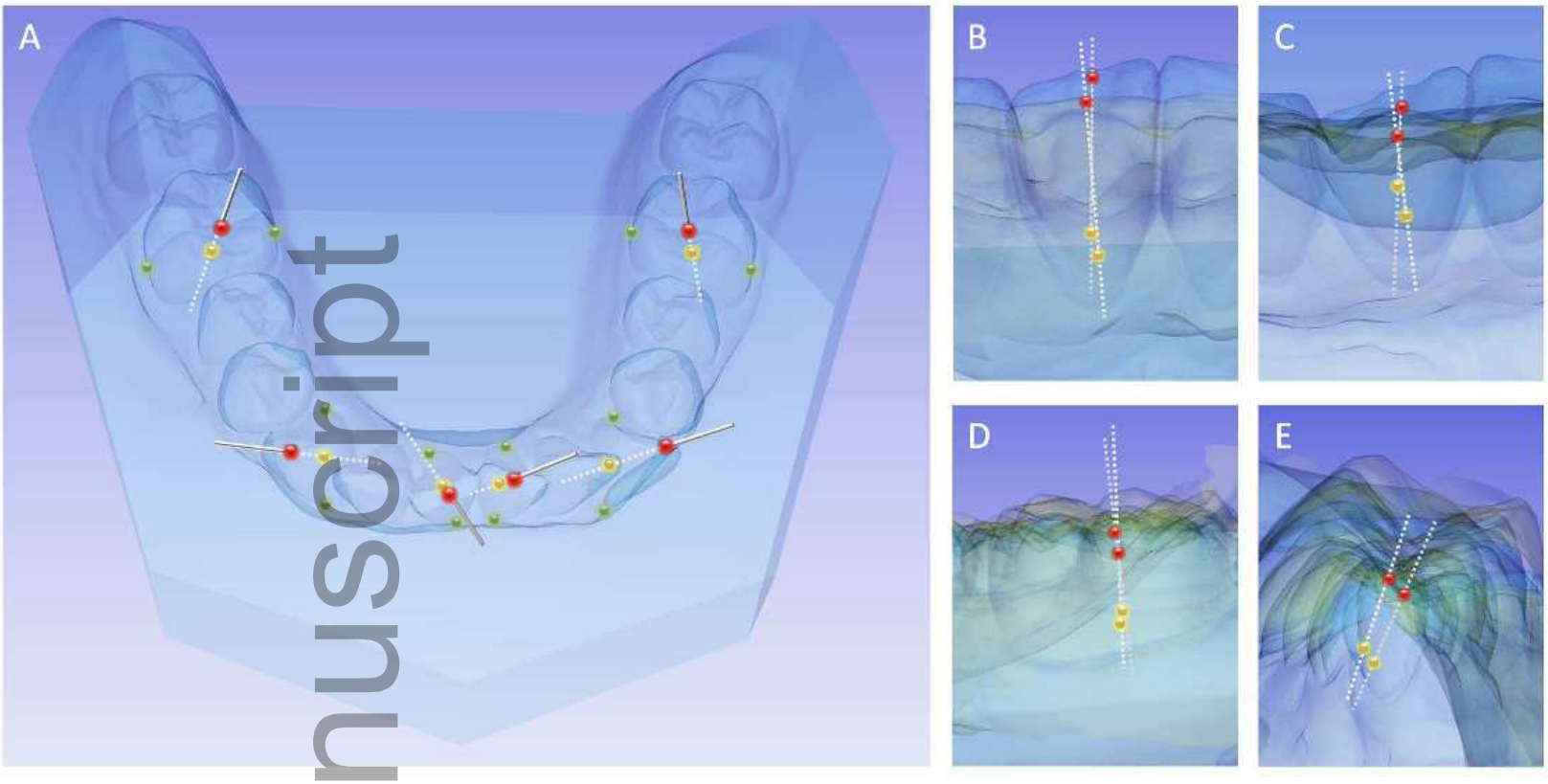

ocr_12489_f2.eps

Author Manuscript

This article is protected by copyright. All rights reserved

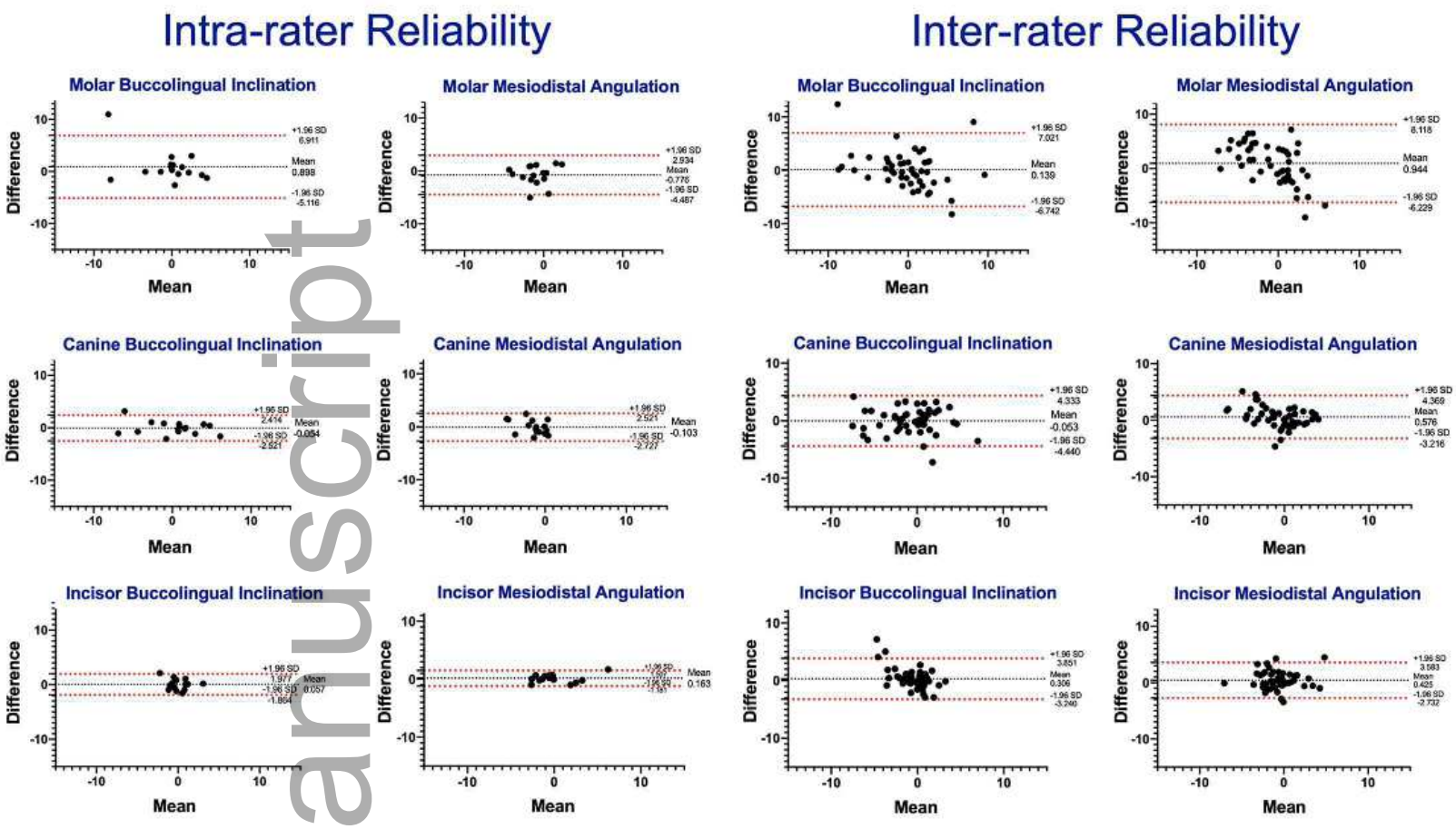

ocr_12489_f3.eps

Author Manuscript

This article is protected by copyright. All rights reserved

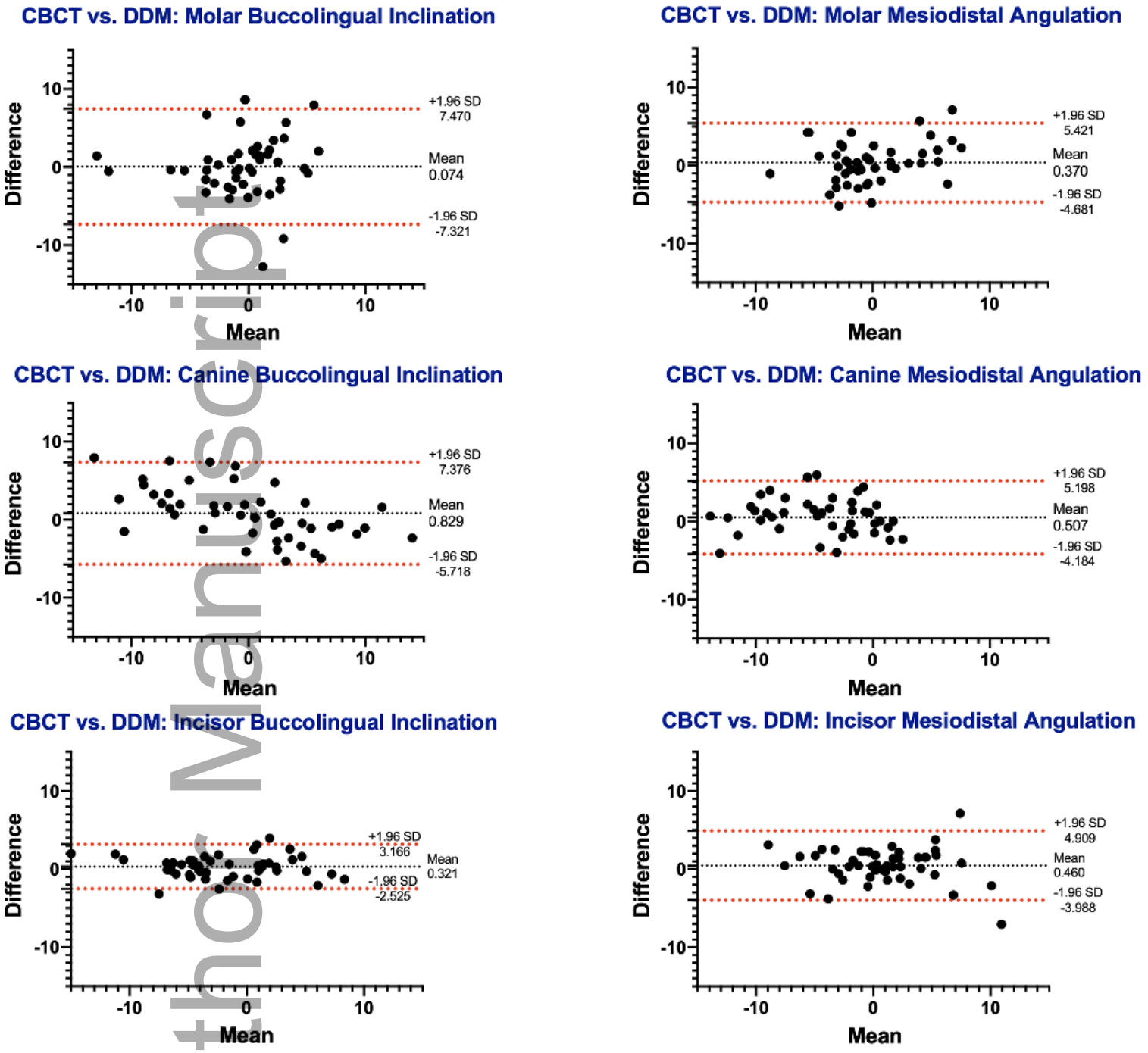

ocr_12489_f4.eps

Author Manuscript

This article is protected by copyright. All rights reserved