Gerami Pedram (Orcid ID: 0000-0002-6194-1037)
Busam Klaus J. (Orcid ID: 0000-0003-0888-9601)

Abstract

Guidelines have been proposed for the pathology reporting of melanoma to ensure inclusion of data elements important for patient care. Compliance with guidelines has been made a yardstick for quality performance. However, there is controversy about how comprehensive a report must be, which is why the American Society of Dermatopathology has formed a task force with the goal of defining minimum data elements that should be included in a pathology report of a primary cutaneous melanoma. Importantly, additional information can or at times should be documented, if a pathologist believes it is valuable to the clinical care team of a particular patient. The proposed minimum reporting guidelines outlined herein largely reflect core reporting elements by various professional organizations. Data elements must be included if they are needed for pathologic staging. Excisions require a margin status, but detailed margin metrics are not required for most cases. Furthermore, histopathologic subtyping of melanoma in situ is not routinely needed. Whether or not invasive melanoma should be subclassified depends on clinical relevance and whether the available evidence permits a definitive melanoma subclassification. When the minimum data elements are included, a pathology report should be considered compliant with quality reporting guidelines.

Author Manuscript

This is the author manuscript accepted for publication and has undergone full peer review but has not been through the copyediting, typesetting, pagination and proofreading process, which may lead to differences between this version and the Version of Record. Please cite this article as doi: 10.1111/cup.14848

This article is protected by copyright. All rights reserved.

Key words: melanoma, guidelines, reporting, synoptic

Author Manuscript

Author Manuscript

Background

Pathology reports of primary cutaneous melanoma play an integral role in the clinical care of patients. Ideally, they not only correctly document the presence of melanoma, but also provide key prognostic information relevant for staging and, in the case of an excision, specify the margin status. In order to promote consistent reporting of clinically relevant information by practitioners nationally and internationally, professional societies have created reporting guidelines. The International Collaboration on Cancer Reporting (ICCR) leads global efforts[1]. For pathologists in the United States, the most widely known reporting guidelines for various cancer types are those issued by the College of American Pathologists (CAP)[2].

Both the ICCR and CAP guidelines include core and non-core elements[3,4]. Core elements are considered mandatory and include patient identifiers, procedure type, anatomic site, and histopathologic parameters needed for staging. Non-core elements are considered worthwhile reporting in select case scenarios but are not essential for clinical care of every patient with melanoma. With regard to the reporting format, a synoptic template is generally recommended for ease of collection of the structured data elements[3-5].

In the United States, compliance with CAP reporting guidelines has been designated as standard for excellence by the American College of Surgeons [6]. For melanoma, compliance with CAP reporting guidelines is also a quality parameter for the merit-based incentive payment system (MIPS)[7]. Accordingly, CAP reporting guidelines have been incorporated as structured data synoptic templates into various laboratory

Author Manuscript

information systems. Pathologists are often monitored for compliance with these guidelines.

While guidelines usually reflect consensus recommendations of a panel of academic pathologists, opinions may vary on what must be included in a melanoma pathology report. One such controversy is related to the level of detail needed for the margin status. The CAP protocol for the examination of specimens from patients with melanoma of the skin posted in February 2015 designated detailed margin metrics specifying the distance in millimeters between both in situ and invasive melanoma to the nearest peripheral and deep margins, respectively, as core (mandatory) reporting element[8]. However, this CAP recommendation was met with disapproval and resistance by practitioners because of the added workload with no apparent benefit to patients or many clinicians, who prefer a simple statement as to whether margins are positive or negative.

ASDP Melanoma Reporting Task Force

Since the level of detail mandated by reporting guidelines can be burdensome and there may be financial consequences for non-compliance, the American Society of Dermatopathology (ASDP) decided to form a Melanoma Reporting task force charged with developing minimum reporting recommendations for a quality melanoma pathology report. To be clear, the objective was not to develop guidelines for the most comprehensive report, but a proposal for essential information that clinicians require for patient management.

Author Manuscript

The Melanoma Reporting task force comprised experts from different geographic regions in the United States including both Dermatology and Pathology-trained dermatopathologists. Proposals were discussed at virtual meetings, submitted for further review to the ASDP Quality Committee and then to the board of directors. The guidelines were made available to ASDP members. Feedback from the general membership was reviewed, and a final draft was submitted to the Board of Directors for acceptance in October 2024. The details of the ASDP guidelines for histopathologic reporting of primary cutaneous melanoma and their rationale are discussed herein.

PATHOLOGY REPORTING GUIDELINES OF PRIMARY CUTANEOUS MELANOMA

The guidelines proposed herein address histopathologic findings. The ASDP endorses standard of practice recommendations for documenting patient identifiers (name, date of birth, medical record number), anatomic site, and date and type of surgical procedure that was performed.

TUMOR DIAGNOSIS

The most important data element of a melanoma pathology report is the correct diagnosis. It should be clearly stated as melanoma or not (e.g., nevus, lentigo, other), except for when the diagnosis is uncertain. For primary cutaneous melanoma, a distinction needs to be made between in situ and invasive melanoma.

PATHOLOGY REPORTING OF MELANOMA IN SITU

Author Manuscript

For biopsies of melanoma in situ, it is sufficient to report the diagnosis "melanoma in situ". No further histopathologic detail, such as histopathologic subtype, is necessary for a report to meet minimum quality standards. Providing further details is encouraged, such as the presence of a scar or features of regression. While one does not need to specify the margin status of melanoma in situ when only a partial biopsy was performed, one should consider doing so. The information may be helpful to the pathologist reviewing the subsequent excision, especially if the slides or digital image of the prior biopsy are not available. For excisional biopsies or wide local excisions of melanoma in situ, reporting the margin status is required.

PATHOLOGY REPORTING OF INVASIVE MELANOMA

In addition to documenting the diagnosis of invasive melanoma, minimum quality standards for a pathology report require the provision of prognostic data elements relevant for patient care (Table 1). Algorithms for surgical management, such as eligibility for sentinel lymph node biopsy depend on primary tumor stage (T-category). Thus, if possible, the data elements required for staging must be recorded and the primary tumor stage be specified. For the current (8th) edition of the AJCC staging system of melanoma[9], a measured value of tumor thickness in millimeters is needed, and documentation as to whether tumor ulceration is present or absent. Because it affects tumor stage and prognosis, the presence or absence of a locoregional metastasis (aka "satellite") is also a core data element. A distinction between macroscopic and microscopic satellite is not needed. The requirement for reporting on

satellites applies to excisions. It is usually not applicable to a shave or punch biopsy, since an excision specimen is generally needed for diagnosing a primary melanoma with satellite metastasis.

Although currently tumor mitotic rate (TMR), lymphovascular invasion (LVI), and neurotropism do not affect AJCC staging, the ASDP concurs with CAP and ICCR to designate them as core reporting elements because of their prognostic value. While a margin status is not necessary for many partial tumor biopsies, when invasive melanoma is transected at the deep aspect of a biopsy sample (Fig.1) we recommend reporting this finding to convey that the final tumor thickness (and primary tumor stage) may be greater upon review of the subsequent excision. For excisional biopsies or wide local excisions, it is mandatory to document whether the surgical margins are free of tumor or not. Measuring the distance to the nearest side and deep margin is usually not required (Fig.2). If margins are positive for in situ and/or invasive melanoma, that needs to be documented and pinpointed, if possible, as in the case of an oriented specimen. For reporting the data elements of invasive melanoma, a synoptic format is generally recommended.

DISCUSSION

The guidelines for reporting histopathologic data elements in primary cutaneous melanoma presented herein are not a proposal for an optimal pathology report. Their purpose is to present a consensus on what minimum data elements the ASDP would accept for a pathology report to meet quality standards.

Author Manuscript

Author Manuscript

Since guidelines for surgical management of invasive melanoma in the United States[10] are based on AJCC staging criteria, a pathology report should contain all data elements needed for tumor staging, if those parameters can be obtained, which is not always possible. The ability to report comprehensive histopathologic data elements relies in part on the type of biopsy performed (partial or complete) and quality of the available histopathologic features. Tangential sectioning or folding of tissue, for instance, may render some parameters unreliable or unattainable. If no epidermis is seen, ulceration cannot be assessed. The data elements currently needed for staging include a measurement of tumor thickness, the ulceration status and the presence or absence of locoregional metastases ("satellites"). While for pT1a melanomas the initial biopsy often permits definitive assessment of all parameters relevant for staging, that is not always the case. If the subsequent excision contains residual invasive melanoma, an attempt should be made to correlate and unify the findings from the original biopsy and subsequent excision.

Since currently TMR, LVI and neurotropism do not determine AJCC tumor stage, some members of the ASDP proposed that these parameters could be designated as optional for reporting. However, the prognostic value of TMR is well established[3], which is why it is used as data element in risk calculators for patients with a primary cutaneous melanoma[11]. Several studies also support as strong association of LVI at the site of the primary tumor and regional lymph node involvement[12,13]. While neurotropism has limited prognostic value *per se* and there is insufficient knowledge about interobserver reproducibility, neurotropism is relevant for clinical care decisions as patients with

Author Manuscript

neurotropism may benefit from post-surgical radiation therapy [14,15]. Thus, for reasons of clinical relevance beyond tumor staging and for the sake of harmonization of reporting guidelines across different organizations, the ASDP task force endorses the designation of TMR, LVI and neurotropism as core elements.

Finally, in the case of an excisional biopsy or wide local excision a pathologist must report on the margin status so that the surgeon and patient know whether the surgical procedure has achieved complete removal of the tumor or not. In most cases, a simple statement suffices as to whether tumor extends to a surgical margin or not. This can be communicated in a variety of terms, such as that the margins are "positive" or "negative", "involved" or "not involved". Precise measurement of margin clearance is usually not necessary[16]. If a melanoma in situ, for example, is clearly surrounded by a rim of normal skin in all available sections, documenting that the clearance to the nearest side margin is 3.4 mm has no added clinical value beyond the statement that the margins are negative. Aside from the fact there is a limit to the level of precision of microscopic measurements, especially in the setting of staged excisions with *en face* margins, providing a numerical margin clearance is, in our experience, often confusing to clinicians and patients who may wonder whether the reported value is sufficient or not. Furthermore, adequacy of clearance is not only a function of tumor distance to the margin. It largely depends on the growth pattern of the tumor[16]. A sharply circumscribed tumor can be safely removed with a narrow margin, while a tumor with irregular growth and ill-defined borders needs a wider "safety" clearance to ensure complete removal. Thus, in select scenarios, whenever it is thought to be clinically

Author Manuscript

beneficial, we encourage to provide details, such as when an ill-defined melanoma in situ or invasive desmoplastic melanoma extend to within less than 1 mm of the nearest side or deep margins, respectively.

There are other histopathologic features which may be worthwhile reporting, but are best considered optional because of currently limited impact on clinical management in most cases. Such parameters include the pattern of lymphocytic infiltrates (tumor-infiltrating lymphocytes) [17-19], regression[20], incipient ulceration[21], the presence of an associated melanocytic nevus, angiotropism[22] or severe solar elastosis[23]. These findings may be of interest in some cases, which is why we do not discourage their reporting. Their status as optional data elements simply means that we do not consider them as mandatory for every pathology report to meet minimum quality standards.

The issue of histopathologic subtyping also needs to be addressed. For cases of conventional melanoma in situ, the histopathologic subclassification as superficial spreading (aka pathway I low chronic sun damage melanoma), lentigo maligna (aka high chronic sun-damage melanoma) or acral “type” adds little, if any useful information beyond what is already obvious from the anatomic location of the tumor, skin phenotype and age of the patient. Furthermore, especially on a small partial biopsy, the distinction of superficial spreading melanoma in situ of sun-damaged skin from lentigo maligna melanoma in situ can be difficult and is subject to significant interobserver variability. Thus, we do not think that the histopathologic subclassification of melanoma in situ should be mandatory for reporting.

Author Manuscript

Similar considerations apply to most superficially invasive conventional melanomas. However, for some melanomas discerning the histopathologic subtype is important for clinical care purposes, in which case it should then be specified in the pathology report. Those scenarios include pure desmoplastic melanoma[24], blue nevus-like melanomas[25], and melanomas arising in giant congenital nevi[26]. Desmoplastic melanomas pose a unique challenge for clinical detection and locoregional surgical control. For desmoplastic melanomas further classification into pure versus mixed is recommended, if possible, since this may affect the decision whether or not to perform a sentinel lymph node biopsy[27,28]. For the blue nevus-related melanomas and nodular subepithelial melanomas arising in a giant congenital nevus, the melanoma subclassification helps alert the clinician that prognostic models for microstaging melanomas have limited predictive value for patients with these rare tumors.

There is also value in some situations to apply the terms nodular, nevoid, undifferentiated, and Spitz or spitzoid melanoma[26]. The annotation “nodular” melanoma is helpful to convey the need for clinicopathologic correction to be certain about the primary nature of the tumor. Nevoid, undifferentiated, spitzoid and Spitz melanomas alert to diagnostic challenges, possible prognostic differences from conventional melanomas, and the related common need for ancillary studies to establish a definitive diagnosis[29-31].

Since a synoptic format is often the preferred way to document histopathologic features associated with a cancer diagnosis[5,6], such as melanoma, we recommend the incorporation of a template that includes mandatory fields for core elements, but also

Author Manuscript

allows for some flexibility, especially for partial biopsy samples and for excisions whenever some data fields of potential interest cannot be evaluated or adequately be assessed. If a synoptic template is used, one may simply enter “cannot be evaluated”, “not applicable” or “to be determined in the resection specimen”, if a data field simply cannot be assessed, such as the presence or absence of microsatellites in a shave biopsy. If a data element, such as histopathologic subtype is considered irrelevant in a particular case or uncertain, one may simply enter “not specified”.

There are numerous situations when a pathologist may require flexibility in reporting even core elements. For example, if a curettage biopsy is performed in the case of a clinically unsuspected melanoma, one may only report that fragments of melanoma are present, attempt to provide a minimum tumor thickness (with the designation “at least”) and comment on the ulceration status, if possible. For a re-excision of a previously biopsied melanoma with no residual invasive tumor, it should suffice to state if there is residual melanoma in situ at the site of the scar and to provide information on the margin status. A summative final report of a melanoma is encouraged, if an excision contains residual invasive melanoma and the slides or digital images of the prior biopsy are available for review.

Guidelines proposed for the reporting of the histopathologic features of invasive melanoma are intended to ensure quality care. Therefore, these guidelines apply to anybody interpreting microscopic sections of melanoma and reporting on them, whether they are dermatopathologists, general pathologists, dermatologists or dermatologic (Mohs) surgeons. While recording prognostically relevant histopathologic

data elements is important for clinical care decisions, the single most important data element remains the correct tumor diagnosis. Establishing a precise diagnosis often depends on the clinical context, which is why we strongly encourage those who submit skin biopsies or excisions for histopathologic review to provide relevant clinical information, such as the size of a pigmented lesion. Access to photos of the clinical lesion, if possible/available, is also encouraged as it may improve diagnostic accuracy.

ACKNOWLEDGEMENTS

The authors wish to thank the members of the ASDP executive team and Board of Directors for supporting the task force and approving it final proposal. We also want to thank the Quality Committee and all members who responded during the period of public comments for their suggestions for edits.

Author Manuscript

Author Manuscript

References

1. https://www.iccr-cancer.org/datasets/published-datasets/skin/melanoma/.
2. Protocols. CoAPCR. https://www.cap.org/protocols-and-guidelines/cancer-reporting-tools/cancer-protocols. In:2021.
3. Scolyer RA, Judge MJ, Evans A, et al. Data set for pathology reporting of cutaneous invasive melanoma: recommendations from the international collaboration on cancer reporting (ICCR). *Am J Surg Pathol.* 2013;37(12):1797-1814.
4. Scolyer RA, Rawson RV, Gershenwald JE, Ferguson PM, Prieto VG. Melanoma pathology reporting and staging. *Mod Pathol.* 2020;33(Suppl 1):15-24.
5. Sluijter CE, van Lonkhuijzen LR, van Slooten HJ, Nagtegaal ID, Overbeek LI. The effects of implementing synoptic pathology reporting in cancer diagnosis: a systematic review. *Virchows Arch.* 2016;468(6):639-649.
6. Zheng L FA, Deming S, et al Synoptic reporting for cancer surgery:. *American College of Surgeons Bulletin.* 2021.
7. https://mdinteractive.com/mips_quality_measure/2022-mips-quality-measure-397.
8. https://documents.cap.org/protocols/cp-melanoma-skin-2015-v3301.pdf.
9. Keung EZ, Gershenwald JE. The eighth edition American Joint Committee on Cancer (AJCC) melanoma staging system: implications for melanoma treatment and care. *Expert Rev Anticancer Ther.* 2018;18(8):775-784.
10. Swetter SM, Johnson D, Albertini MR, et al. NCCN Guidelines(R) Insights: Melanoma: Cutaneous, Version 2.2024. *J Natl Compr Canc Netw.* 2024;22(5):290-298.
11. https://melanoma.org.au/for-clinicians/risk-calculators/.
12. Moy AP, Duncan LM, Kraft S. Lymphatic invasion and angiotropism in primary cutaneous melanoma. *Lab Invest.* 2017;97(2):118-129.
13. Xu X, Chen L, Guerry D, et al. Lymphatic invasion is independently prognostic of metastasis in primary cutaneous melanoma. *Clin Cancer Res.* 2012;18(1):229-237.
14. Pinkham MB, Herschtal A, Hong AM, et al. ASO Author Reflections: The Role of Postoperative Radiation Therapy Following Wide Excision of Neurotropic Melanoma of the Head and Neck: Now and into the Future. *Ann Surg Oncol.* 2024;31(9):6118-6119.
15. Varey AHR, Goumas C, Hong AM, et al. Neurotropic melanoma: an analysis of the clinicopathological features, management strategies and survival outcomes for 671 patients treated at a tertiary referral center. *Mod Pathol.* 2017;30(11):1538-1550.
16. Weyers W. "Personalized Excision" of Malignant Melanoma-Need for a Paradigm Shift in the Beginning Era of Personalized Medicine. *Am J Dermatopathol.* 2019;41(12):884-896.
17. Aung TN, Shafi S, Wilmott JS, et al. Objective assessment of tumor infiltrating lymphocytes as a prognostic marker in melanoma using machine learning algorithms. *EBioMedicine.* 2022;82:104143.

Author Manuscript

18. Maibach F, Sadozai H, Seyed Jafari SM, Hunger RE, Schenk M. Tumor-Infiltrating Lymphocytes and Their Prognostic Value in Cutaneous Melanoma. *Front Immunol.* 2020;11:2105.
19. Schatton T, Scolyer RA, Thompson JF, Mihm MC, Jr. Tumor-infiltrating lymphocytes and their significance in melanoma prognosis. *Methods Mol Biol.* 2014;1102:287-324.
20. Gardner LJ, Strunck JL, Wu YP, Grossman D. Current controversies in early-stage melanoma: Questions on incidence, screening, and histologic regression. *J Am Acad Dermatol.* 2019;80(1):1-12.
21. Paver EC, Ahmed T, Burke H, et al. Prognostic Significance of Incipient Ulceration in Primary Cutaneous Melanoma. *JAMA Dermatol.* 2023;159(12):1359-1367.
22. Barnhill R, Dy K, Lugassy C. Angiotropism in cutaneous melanoma: a prognostic factor strongly predicting risk for metastasis. *J Invest Dermatol.* 2002;119(3):705-706.
23. Lezcano C, Luo L, Shen R, Orlow I, Thomas NE, Berwick M, Busam KJ. Solar elastosis correlates with high tumor mutation burden and better 5-year disease-specific survival in patients with stage II/III melanoma. *EJC Skin Cancer.* 2024;2.
24. Busam KJ. Desmoplastic melanoma. *Clin Lab Med.* 2011;31(2):321-330.
25. Costa S, Byrne M, Pissaloux D, et al. Melanomas Associated With Blue Nevi or Mimicking Cellular Blue Nevi: Clinical, Pathologic, and Molecular Study of 11 Cases Displaying a High Frequency of GNA11 Mutations, BAP1 Expression Loss, and a Predilection for the Scalp. *Am J Surg Pathol.* 2016;40(3):368-377.
26. Boutko A, Hagstrom M, Lampley N, et al. PRAME Immunohistochemical Expression and TERT Promoter Mutational Analysis as Ancillary Diagnostic Tools for Differentiating Proliferative Nodules From Melanoma Arising in Congenital Nevi. *Am J Dermatopathol.* 2023;45(7):437-447.
27. Dunne JA, Wormald JC, Steele J, Woods E, Odili J, Powell BW. Is sentinel lymph node biopsy warranted for desmoplastic melanoma? A systematic review. *J Plast Reconstr Aesthet Surg.* 2017;70(2):274-280.
28. Busam K GP, Scolyer R. *The Pathology of Melanocytic Tumors.* Philadelphia, PA: Elsvier; 2019.
29. Quan VL, Zhang B, Zhang Y, et al. Integrating Next-Generation Sequencing with Morphology Improves Prognostic and Biologic Classification of Spitz Neoplasms. *J Invest Dermatol.* 2020;140(8):1599-1608.
30. Kasago IS, Chatila WK, Lezcano CM, et al. Undifferentiated and Dedifferentiated Metastatic Melanomas Masquerading as Soft Tissue Sarcomas: Mutational Signature Analysis and Immunotherapy Response. *Mod Pathol.* 2023;36(8):100165.
31. Jackett LA, Colebatch AJ, Rawson RV, et al. Molecular Profiling of Noncoding Mutations Distinguishes Nevoid Melanomas From Mitotically Active Nevi in Pregnancy. *Am J Surg Pathol.* 2020;44(3):357-367.

Author Manuscript

Table

Table 1: Data elements recommended for invasive melanoma.

Data Element	Entries
1. Diagnosis	Melanoma
2. Tumor thickness	# mm
3. Ulceration	Present; Absent
4. Tumor mitotic rate	# mitoses/mm2
5. Margin Status	Involved; Not involved
6. Neurotropism	Present; Absent
7. Lymphovascular Invasion	Present; Absent
8. Satellitosis	Present; Absent
9. AJCC Tumor Stage	pT1a; pT1b; pT2a; etc.

= numerical value reported in millimeters

Comments:

If a data element cannot adequately be evaluated, one should indicate that accordingly (e.g., “cannot be evaluated”). In addition to the core elements listed above, a pathologist may report or discuss other histopathologic findings (e.g., melanoma subtype, presence of a nevus, regression) to the extent that they can be reliably evaluated and as judged appropriate based on the potential clinical relevance (e.g., primary nodular vs metastatic melanoma, pure vs mixed desmoplastic melanoma).

Author Manuscript

FIGURE LEGEND

Figure 1.



Figure 1: Shave biopsy of a melanoma. When invasive melanoma is transected at the deep margin as in this case, this should be documented, such as by stating “transected at the deep margin”. The thickness value should then be preceded by “at least”.

Author Manuscript

Figure 2:

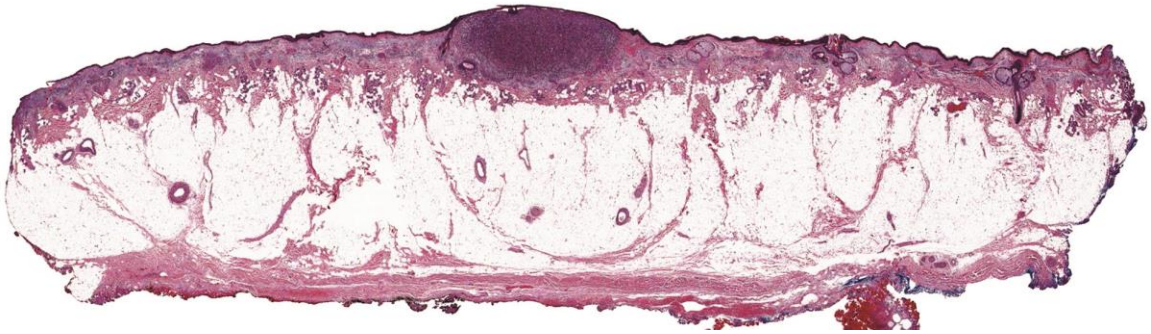

Note: Wide local excision of a primary cutaneous melanoma. In this case, it is sufficient to state that the margins are negative. No detailed measurement of margin clearances (e.g. 8 mm distance from the nearest side margin) is needed in this case.