ESC European Society of Cardiology

European Heart Journal - Case Reports (2025) **9**, ytaf004
https://doi.org/10.1093/ehjcr/ytaf004

GRAND ROUND
Cardiovascular imaging

An aortic root abscess mimic identified by multi-disciplinary imaging review: a case report

Juan Caceres [1], Abdulbaset Sulaiman[2], Mark Edwards[1], Shiwei Zhou[3], Sarah Kurz[3], Zoe Raglow[3], Barbara Hamilton[4], and Andrew W. Harris [2]*

[1]Department of Internal Medicine, Michigan Medicine, 1500 E. Medical Center Dr., Ann Arbor, MI 48109, USA; [2]Department of Internal Medicine, Division of Cardiovascular Medicine, Michigan Medicine, 2722 Cardiovascular Center, 1500 E. Medical Center Dr., Ann Arbor, MI 48109, USA; [3]Department of Internal Medicine, Division of Infectious Diseases, Michigan Medicine, 1500 E. Medical Center Dr., Ann Arbor, MI 48109, USA; and [4]Department of Cardiac Surgery, Michigan Medicine, 1500 E. Medical Center Dr., Ann Arbor, MI 48109, USA

Received 19 March 2024; revised 12 July 2024; accepted 6 January 2025; online publish-ahead-of-print 15 January 2025

Background While echocardiography and cardiac positron emission tomography (PET) can aid in the diagnosis of prosthetic valve endocarditis (PVE), post-operative changes can lead to false-positive imaging findings. We report a case of a patient with an aortic valve prosthesis with remnant BioGlue deposits mimicking a para-valvular abscess on imaging in the setting of suspected PVE.

Case summary A 67-year-old man presented with 2 days of fever, chills, and altered mentation. He had a history of two prior aortic root replacements—19 and 4 years prior to his presentation. He had blood cultures that were persistently positive for *Pseudomonas aeruginosa*. Initial transoesophageal echocardiogram (TEE) was notable for a thickening of the posterior aortic root thought to be consistent with post-surgical changes. Cardiac PET showed significant uptake around the prosthetic aortic valve, concerning for a para-valvular abscess. However, given the patient's high risk for re-do surgery, clearance of blood cultures, and preserved valve function, our multi-disciplinary endocarditis team (MET) recommended non-surgical management and close follow-up. After 6 weeks of appropriate antibiotics, a TEE demonstrated concern for an evolving para-valvular abscess. The MET performed extensive review of his prior surgical interventions and cardiac imaging, revealing the previous use of surgical BioGlue and stability in the aortic root on imaging, consistent with non-infectious post-surgical changes, and conservative management was recommended.

Discussion Thorough review of prior interventions and serial imaging in patients with suspected PVE through a multi-disciplinary team approach is essential in elucidating the complete, often complex, clinical picture and recommending the most appropriate management.

Keywords Case report • Prosthetic valve endocarditis • Multi-disciplinary endocarditis team • Echocardiography • Cardiac imaging

ESC curriculum 2.2 Echocardiography • 2.1 Imaging modalities • 4.11 Endocarditis • 4.10 Prosthetic valves • 7.5 Cardiac surgery

Learning points

- A multi-disciplinary endocarditis team is essential for the appropriate diagnosis and management of patients with suspected prosthetic valve endocarditis (PVE).
- A thorough understanding of a patient's past surgical interventions is crucial for accurate interpretation of imaging findings.
- Review of a patient's serial imaging can help distinguish expected post-surgical changes from active infection in suspected PVE.

* Corresponding author. Tel: +1 888 287 1082, Email: harrisaw@med.umich.edu
Handling Editor: Jan Henzel
Peer-reviewers: Carlos Nicolas Perez-Garcia; Yehia Saleh; Dimitrios Karelas
© The Author(s) 2025. Published by Oxford University Press on behalf of the European Society of Cardiology.
This is an Open Access article distributed under the terms of the Creative Commons Attribution-NonCommercial License (https://creativecommons.org/licenses/by-nc/4.0/), which permits non-commercial re-use, distribution, and reproduction in any medium, provided the original work is properly cited. For commercial re-use, please contact reprints@oup.com for reprints and translation rights for reprints. All other permissions can be obtained through our RightsLink service via the Permissions link on the article page on our site—for further information please contact journals.permissions@oup.com.

Downloaded from https://academic.oup.com/ehjcr/article/9/2/ytaf004/7954263 by guest on 20 February 2025

Primary specialties involved other than cardiology

Internal medicine; Infectious diseases; Cardiac surgery; Nuclear medicine; and Social work

Introduction

Transoesophageal echocardiography (TEE) is the standard of care for evaluation of suspected prosthetic valve endocarditis (PVE), particularly for the diagnosis of vegetations and para-valvular complications due to higher sensitivity than transthoracic echocardiography. However, the sensitivity and specificity of TEE remain limited by acoustic shadowing and artefact, respectively.[1,2] Cardiac positron emission tomography (PET) can play a valuable role in the evaluation of suspected PVE due to its high sensitivity. However, specificity is limited by possible [^{18}F]Fluorodeoxyglucose (FDG) uptake due to non-infectious inflammation.[3] We report a case of a patient with an aortic valve prosthesis with remnant surgical adhesive deposits causing inflammation and mimicking a para-valvular abscess in the setting of suspected PVE.

Timeline

Day	Event
Nineteen years prior to admission	Underwent a stentless bioprosthetic modified inclusion root procedure, replacement of the ascending aorta and total arch due to severe aortic regurgitation and aortic aneurysm
Four years prior to admission	Re-do total aortic root replacement with a composite conduit was performed. Procedure complicated by complete heart block requiring permanent pacemaker
Day 0	Admitted to the hospital after 2 days of fever, chills, and altered mental status. Blood cultures positive for *Pseudomonas aeruginosa*; he was started on cefepime.
Day 6	Transoesophageal echocardiogram (TEE) notable for possible vegetation on pacemaker lead and thickened posterior aortic root. Persistently positive cultures despite dual antibiotic therapy (cefepime + levofloxacin). Last day of positive blood culture for *P. aeruginosa*
Day 9	Cardiac positron emission tomography notable for significant uptake around the prosthetic aortic valve concerning for para-valvular abscess
Day 12	Multi-disciplinary endocarditis team (MET) recommended extraction of pacemaker and medical management. At this point, blood cultures were negative, and he had clinically improved
Day 17	Pacemaker removed and replaced with a leadless pacemaker
Day 18	Repeat TEE with stable findings. Subsequently discharged with a planned 6-week course of cefepime
Six weeks after discharge	TEE demonstrated mildly thickened aortic valve leaflets with newly recognized fluid space, concerning for evolving aortic abscess
	Case re-discussed with the MET. Upon further review of the patient's prior imaging, the findings in question are consistent with post-operative changes and prior use of BioGlue. Patient maintained on 1 year of suppressive levofloxacin

Case presentation

A 67-year-old man presented with 2 days of fever, chills, and altered mental status. He had a history of a bicuspid aortic valve with severe aortic regurgitation and aortic aneurysm leading to a stentless modified inclusion root procedure, replacement of the ascending aorta, and total arch replacement. Fifteen years later, he required a total root replacement with a composite conduit due to structural valve degeneration, which was complicated by complete heart block, requiring placement of a dual-chamber permanent pacemaker.

Upon presentation to the emergency department, his temperature was 37.3°C, blood pressure 102/68 mmHg, pulse 76 bpm, and his oxygen saturation was 97% on room air. On initial examination, he was non-toxic appearing, had no notable findings on lung auscultation, had a regular heart rate, and had a normal rhythm without any murmurs on auscultation. His neurologic exam was initially normal. On re-evaluation, his temperature increased to 39.5°C, and he became acutely confused. Given this clinical change, computerized tomography (CT) of his head was performed, which did not show any acute findings.

His initial diagnostic assessment was notable for a white blood cell count of 8.3 K/μL with neutrophilic predominance, haemoglobin of 13.1 (g/dL), and platelets of 94 K/μL. Metabolic panel was notable for a sodium of 131 mmol/L, urea nitrogen 35 mg/dL, and creatinine 1.84 mg/dL. Lactate was 2.7 mmol/L. Three sets of blood cultures were obtained prior to the administration of antibiotics. Urinalysis was notable for pyuria. Chest radiograph did not show any acute pulmonary findings.

The patient was initially started on ceftriaxone (2 g dose), ampicillin (2 g dose), vancomycin (1.25 g dose), and acyclovir (800 mg every 12 h) due to concern for meningitis. However, he was transitioned to cefepime (2 g every eight hours) monotherapy for the treatment of sepsis after his blood cultures resulted positive for *Pseudomonas aeruginosa*. Transthoracic echocardiogram on Day 2 of his hospitalization did not show evidence of endocarditis or valve dysfunction.

Infectious Diseases were consulted and recommended further evaluation for endocarditis or other endovascular infection, due to persistent bacteraemia. Computerized tomography of the chest on Day 5 was notable for a soft tissue density around the aortic root, which was stable compared with prior CT scans, with no definitive signs of infection (*Figure 1A*). Magnetic resonance of the pelvis revealed evidence of prostatitis, which was thought to be the infectious source in the setting of pyuria. Transoesophageal echocardiogram was performed on Day 6, which demonstrated evidence of thickening of the posterior aortic root, with mild prosthetic leaflet thickening, both of which were favoured to represent non-infectious post-surgical changes (*Figure 1B* and *C*, Supplementary material online, *Videos 1* and 2). Transoesophageal echocardiogram was also notable for a small mobile density attached to the right atrial lead, possibly representing a fibrinous strand vs. small

Downloaded from https://academic.oup.com/ehjcr/article/9/2/ytaf004/7954263 by guest on 20 February 2025

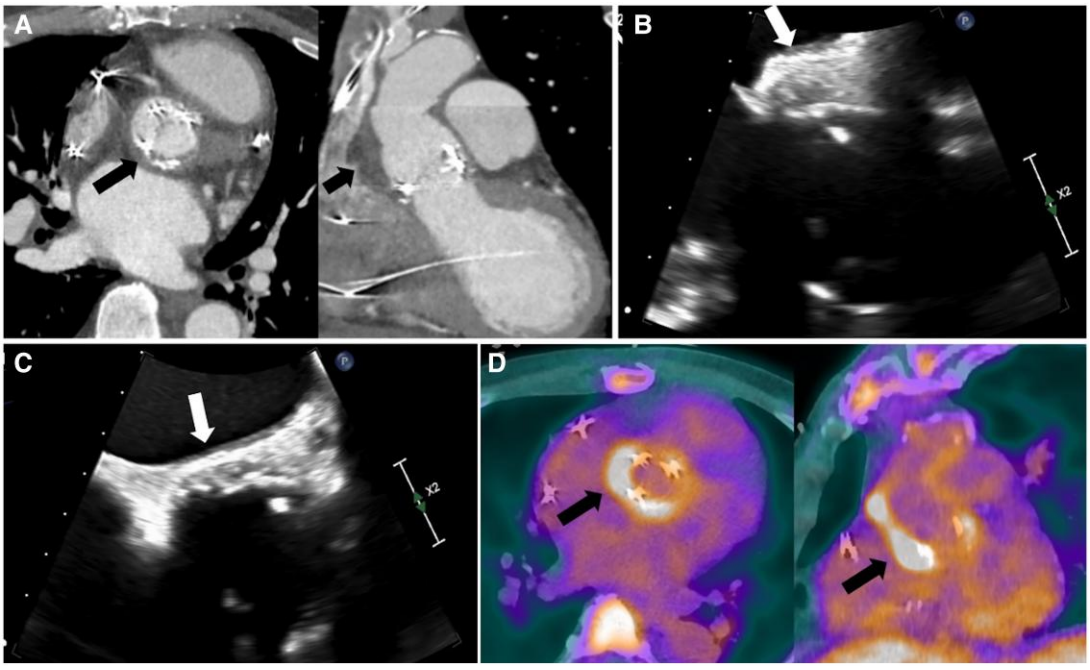

Figure 1 (*A*) Complex aortic para-valvular appearance with abnormal soft tissue density (black arrow) and para-valvular calcifications; posterior aortic root thickening with heterogeneous appearance seen on (*B*) long-axis and (*C*) short-axis transoesophageal echocardiogram images; (*D*) intense uptake by FDG positron emission tomography surrounding aortic valve prosthesis, concerning for para-valvular abscess.

vegetation. Cardiac surgery and electrophysiology were consulted. Blood cultures remained positive for *Pseudomonas*, so levofloxacin (750 mg daily) was added.

Cardiac PET 3 days later demonstrated intense FDG uptake around the aortic valve prosthesis, increasing concern for a para-valvular abscess (*Figure 1D*). No abnormal FDG uptake was observed in association with the pacemaker leads or pocket. After the MET discussion on Day 12, surgical management was not recommended due to his high surgical risk, clinical improvement, blood culture clearance, and preserved valve function. Despite lack of abnormal FDG uptake on the pacemaker leads or pocket, the consensus of the MET was to proceed with removal of the entire pacemaker system due to persistent high-grade bacteraemia and possible lead vegetation by TEE. The patient's pacemaker was subsequently removed and replaced with a leadless pacemaker on Day 17. There were multiple cultures of the extracted pacemaker, including the right atrium lead tip, right ventricle lead tip, and the pocket. The pacemaker tip cultures were positive for *Corynebacterium* species, which was thought to be a contaminant. No *Pseudomonas* was isolated from the explanted pacemaker.

After completion of his IV antibiotics, a repeat TEE was performed with initial interpretation concerning for evolving aortic root abscess and possible vegetation of the aortic valve (*Figure 2*, Supplementary material online, *Videos 3* and *4*). He was promptly re-discussed at the MET conference. On review of his serial TEE exams, there was concern for a fluid space not previously seen on his prior TEEs within the posterior aortic root seen on aortic valve short-axis images, though findings were similar in the long-axis view. It was unclear whether these findings represented a true change or rather represented visualization of different areas of the reconstructed aortic root.

A decision on whether the findings on FDG PET and TEE were consistent with an evolution of an aortic abscess would inform the need for a high risk re-do operation vs. ongoing medical management with suppressive oral antibiotics. Therefore, a multi-disciplinary in-depth review of his prior CT scans, FDG PET scans, and echocardiograms was performed by the MET. On review of his serial CT scans, there was evidence of a complex fluid space surrounding the aortic root since his initial operation. His initial operation consisted of stentless (Freestyle^{TM}, Medtronic, Minneapolis, MN, USA) aortic valve implanted via modified inclusion root technique, utilizing a surgical adhesive called BioGlue (CryoLife Inc., Kennesaw, GA, USA) at the areas of surgical anastomosis. Following this operation, a CT scan demonstrated the presence of contrast leak between the aortic graft and the surrounding native aortic tissue, both of which were stable over a few years. He underwent a second operation in 2019 for structural valve degeneration of his aortic valve, requiring a total root replacement with a stented bioprosthetic aortic valve. This operation was extremely challenging due to extensive adhesions in the aortic root, thought to be related to the prior use of BioGlue. Follow-up CT scans after this operation demonstrated resolution of the contrast leak but persistent soft tissue thickening around the aortic root. Comparison of his CT scan on admission (*Figure 1A*) with his CT scan performed before and after his second operation (*Figure 3*) demonstrated identical findings.

Although the clinical suspicion for PVE was high, our extensive multi-disciplinary review led us to strongly favour a different explanation for his abnormal imaging findings: post-operative surgical changes and BioGlue. Although the fluid space in the posterior aortic root by TEE was suspicious for abscess, the chronicity of the CT scan findings provided reassurance that perceived changes by TEE were due to changes in the visualization of this heterogeneous space. Furthermore, BioGlue is a

Downloaded from https://academic.oup.com/ehjcr/article/9/2/ytaf004/7954263 by guest on 20 February 2025

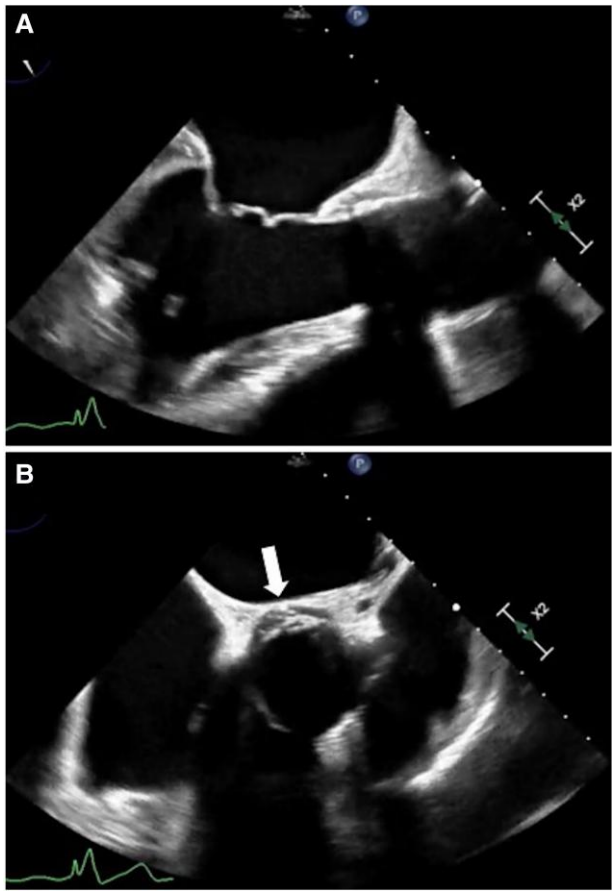

Figure 2 Transoesophageal echocardiogram images of bioprosthetic aortic valve by (*A*) long-axis and (*B*) short-axis views. Although the long-axis image demonstrates stable findings compared with *Figure 1B*, the short-axis images demonstrate a more prominent fluid space than previously recognized. This tomographic plane is more inferior (lower in the aortic root); therefore, it is challenging to determine whether this represented an evolving fluid space or a different representative tomographic plane.

known cause of false-positive FDG PET scans. A repeat CT scan performed at 5 months from his index presentation confirmed stable findings.

Ultimately, our team recommended against surgical intervention at this time due to the lack of convincing evidence for para-valvular involvement and infectious diseases recommended long-term suppressive antibiotics with levofloxacin (750 mg daily) given the prosthetic valve and prosthetic material in the aorta. The patient continued to do well at 12-month follow-up without evidence of recurrent infection or valve dysfunction. Antibiotics were discontinued after a year per patient preference.

Discussion

Prosthetic valve endocarditis continues to be associated with high morbidity and mortality despite improvements in diagnostic evaluation and therapeutic approaches. In addition to echocardiography, cardiac PET and CT imaging can improve diagnostic accuracy in evaluating prosthetic valve infection.[4] The European Society of Cardiology (ESC) recommends PET CT in suspected PVE.[5] Furthermore, PET imaging has now been included as a major criteria in the newly revised Duke criteria.[5,6]

With multiple diagnostic modalities, interpretation and subsequent therapeutic decisions are becoming increasingly more complex. Both TEE and PET are frequently used adjunctively to diagnose PVE. Abnormalities detected on these studies have significant implications for the need for re-do (often high risk) surgical interventions; therefore, it is essential that interpreting physicians have a high level of expertise and are familiar with non-infectious mimics. A multi-disciplinary review of these imaging modalities can help to integrate this information with clinical findings and surgical history to arrive at an accurate diagnosis and inform optimal management in these complex patients. In our case, the multi-disciplinary nature of the team allowed experts from cardiology, nuclear medicine, infectious diseases, radiology, and cardiac surgery to integrate the complex findings on his multi-modality imaging and other data points to inform optimal care.

This case describes a unique presentation of a patient with suspected PVE with residual post-surgical changes on imaging, mimicking a para-valvular abscess. This case highlights multiple complex decisions that must be made in the care of patients with suspected PVE. An understanding of the primary source of infection can inform the likelihood of persistent bacteraemia being related to the primary source or rather due to endovascular infection. In our case, we suspect that the primary source of the bacteraemia was prostatitis due to findings of pyuria present on initial urinalysis and evidence of prostatitis on magnetic resonance imaging. No other source of bacteraemia was identified on thorough evaluation. However, no urine culture was obtained prior to antibiotics, so we are unable to confirm the presence of a genitourinary source of infection. Nevertheless, our antibiotic regimen covered the presumed prostatitis broadly, including *Pseudomonas*.

We were highly suspicious of an endovascular source of infection due to the persistence of bacteraemia for 9 days. Possible sites of endovascular infection were the bioprosthetic aortic valve, aortic root prosthesis, and/or pacemaker leads. Echogenic masses identified on leads by echocardiography are non-specific and can represent a non-infectious aetiology; therefore, an updated statement by the AHA endorses the use of FDG PET for evaluation of patients with possible cardiovascular implantable electronic device (CIED) lead infection.[7] Despite the absence of abnormal FDG uptake by the pacemaker system in our case, prior studies have demonstrated modest sensitivity for detection of CIED infection isolated to the leads. A prior meta-analysis demonstrated a pooled sensitivity of 65% (95% confidence interval 53%–76%) in this context.[8] Furthermore, pacemaker system removal is typically recommended in patients with endocarditis with valve involvement, due to risk of recurrent bacteraemia.[9] Therefore, despite initial plans for non-surgical management for this patient, the MET recommended removal of the pacemaker system due to concern for CIED lead infection and to reduce the risk of recurrent infection.

Although the findings of the most recent TEE and intense peri-aortic FDG uptake by PET raised concern for the need for urgent surgical intervention for treatment of evolving para-valvular abscess, an in-depth review of his prior imaging and surgical interventions led us to conclude that prior use of surgical BioGlue and non-infectious post-operative changes were responsible for these findings and that the patient did not have surgical indications. Prior case studies have reported peri-valvular inflammation and other post-surgical complications related to BioGlue.[10,11] BioGlue has been associated with granulomatous inflammation and fibroblastic proliferation, which explained the intense uptake around the prosthetic valve in our patient.[12] Nonetheless, it is essential to appropriately discern between infection and post-surgical inflammation, which can be done more effectively with thorough investigation of a patient's prior surgeries and serial imaging in the context of an MET.

Downloaded from https://academic.oup.com/ehjcr/article/9/2/ytaf004/7954263 by guest on 20 February 2025

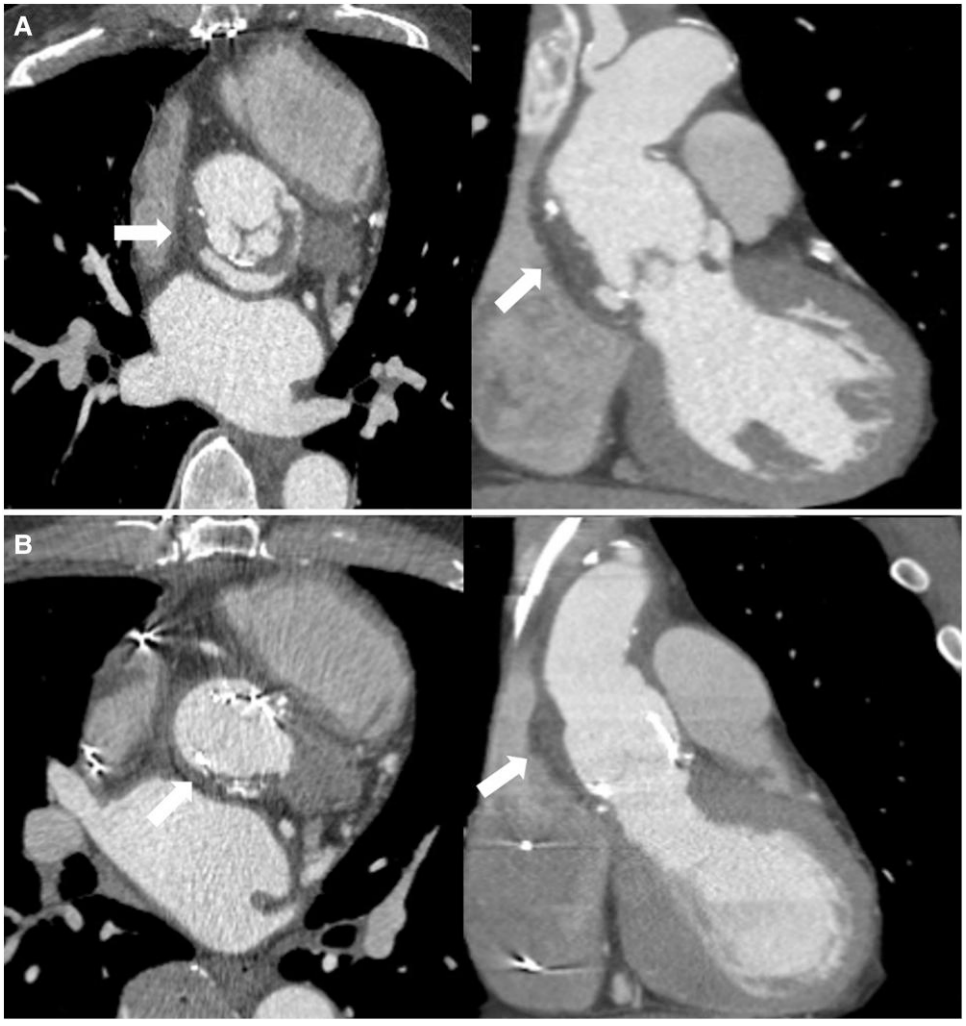

Figure 3 (*A*) Computed tomography scan performed prior to first re-do operation demonstrating abnormal contrast accumulation between aortic graft and native aortic tissue following modified inclusion root technique with nearby soft tissue density (white arrows). (*B*) Persistent soft tissue abnormalities with para-valvular calcifications following re-do total root reconstruction (white arrows). Findings are identical to computerized tomography performed during index hospitalization (*Figure 1A*).

Although evolving para-valvular abscess was able to be ruled out by thorough imaging evaluation, in the presence of persistent bacteraemia and prosthetic material, it can be challenging to definitively exclude infection of the bioprosthetic valve or aortic root graft. While there are limited data, some guidelines recommend long-term antibiotic suppression for suspected infection of retained graft material, especially in cases of aggressive organisms including *Pseudomonas*.[13] Therefore, after multi-disciplinary discussion, the Infectious Disease team recommended long-term antibiotic therapy after completion of IV antibiotics. In this case, levofloxacin was used for a total of 1 year of therapy. In such cases, risks and benefits of indefinite antibiotic therapy need to be made on an individualized basis via informed decision-making. In this scenario, based on his excellent clinical response with antibiotics and pacemaker removal without definitive evidence of prosthetic valve/aortic root involvement, the patient opted to discontinue antibiotics after 1 year due to concerns for side effects.

This case highlights three key points that can help inform optimal management of patients with suspected PVE: (1) an MET should be involved early in the care of patients with suspected PVE; (2) a thorough evaluation and understanding of a patient's past surgical interventions, including prior use of surgical adhesives, and expected post-operative findings can help clarify abnormalities on imaging; and (3) review of a patient's serial imaging is essential in distinguishing post-surgical changes from active infection in PVE.

The ESC guidelines highlight the value of an MET, which can improve diagnostic accuracy and has other significant benefits.[5] At our institution, the implementation of an MET led to a significant decrease in in-hospital mortality in patients with definite endocarditis.[14] Additionally, a recent meta-analysis by Roy *et al.*[15] emphasized the benefit of an MET in the management of patients with infectious endocarditis of with a risk ratio of 0.61 for mortality. Increasing complexity in the diagnostic evaluation of patients with suspected PVE further highlights the need for a collaborative evaluation involving infectious diseases, cardiac imaging, and cardiac surgery experts.

Downloaded from https://academic.oup.com/ehjcr/article/9/2/ytaf004/7954263 by guest on 20 February 2025

Lead author biography



Juan Caceres graduated from the University of Michigan Medical School in 2021 and completed Internal Medicine residency at the University of Michigan. He is currently a Vascular Medicine fellow at the University of Michigan and is applying to Cardiovascular Medicine fellowship programmes.

Supplementary material

Supplementary material is available at *European Heart Journal – Case Reports* online.

Acknowledgements

We would like to thank all members of the University of Michigan Multidisciplinary Endocarditis Team for the valuable contributions they make to caring for patients with infective endocarditis. We would specifically like to thank Dr G. Michael Deeb and Dr Lindsay Petty for being involved in the discussion of the case and review of the manuscript.

Consent: Written and verbal consent was obtained for the drafting, submission, and final publication of this report. The patient approved the writing and submission of this case report.

Conflict of interest: None declared.

Funding: None declared.

Data availability

Data from this case report were obtained through the electronic medical record. All relevant data were presented in the report. Additional patient information is not publicly available due to HIPAA restrictions.

References

1. Baddour LM, Wilson WR, Bayer AS, Fowler VG, Tleyjeh IM, Rybak MJ, et al. Infective endocarditis in adults: diagnosis, antimicrobial therapy, and management of complications: a scientific statement for healthcare professionals from the American Heart Association. *Circulation* 2015;**132**:1435–1486.
2. Bach DS. Transesophageal Echocardiographic (TEE). Evaluation of prosthetic valves. *Cardiol Clin* 2000;**18**:751–771.
3. Pizzi MN, Roque A, Fernández-Hidalgo N, Cuéllar-Calabria H, Ferreira-González I, Gonzàlez-Alujas MT, et al. Improving the diagnosis of infective endocarditis in prosthetic valves and intracardiac devices with ^{18} F-fluordeoxyglucose positron emission tomography/computed tomography angiography: initial results at an infective endocarditis referral center. *Circulation* 2015;**132**:1113–1126.
4. Ivanovic B, Trifunovic D, Matic S, Petrovic J, Sacic D, Tadic M. Prosthetic valve endocarditis—a trouble or a challenge? *J Cardiol* 2019;**73**:126–133.
5. Delgado V, Marsan NA, De Waha S, Bonaros N, Brida M, Burri H, et al. 2023 ESC guidelines for the management of endocarditis. *Eur Heart J* 2023;**44**:3948–4042.
6. Fowler VG, Durack DT, Selton-Suty C, Athan E, Bayer AS, Chamis AL, et al. The 2023 Duke-International Society for Cardiovascular Infectious Diseases criteria for infective endocarditis: updating the modified Duke criteria. *Clin Infect Dis* 2023;**77**:518–526.
7. Baddour LM, Garrigos ZE, Sohail MR, Havers-Borgersen E, Krahn AD, Chu VH, et al. Update on cardiovascular implantable electronic device infections and their prevention, diagnosis, and management: a scientific statement from the American Heart Association. *Circulation* 2024;**149**:e201–e216.
8. Juneau D, Golfam M, Hazra S, Zuckier LS, Garas S, Redpath C, et al. Positron emission tomography and single-photon emission computed tomography imaging in the diagnosis of cardiac implantable electronic device infection: a systematic review and meta-analysis. *Circ: Cardiovascular Imaging* 2017;**10**:e005772.
9. Baddour LM, Epstein AE, Erickson CC, Knight BP, Levison ME, Lockhart PB, et al. Update on cardiovascular implantable electronic device infections and their management: a scientific statement from the American Heart Association. *Circulation* 2010;**121**:458–477.
10. Mistry NP, AlShaheen M, Leung E, Chow B, Wiefels C. Previous BioGlue repair mimicking cardiac infection with 18F-FDG PET imaging. *J Nucl Cardiol* 2023;**30**:420–424.
11. Sidhu S, Goyer C, Hatzakorzian R, Olivier JF, Devarennes B, Cote AV, et al. Transesophageal echocardiographic detection of intracardiac BioGlue postmitral valve replacement. *Anesth Analg* 2007;**105**:1572–1573.
12. Bhamidipati CM, Coselli JS, LeMaire SA. BioGlue in 2011: what is its role in cardiac surgery? *J Extra Corpor Technol* 2012;**44**:P6–12.
13. Wilson WR, Bower TC, Creager MA, Amin-Hanjani S, O'Gara PT, Lockhart PB, et al. Vascular graft infections, mycotic aneurysms, and endovascular infections: a scientific statement from the American Heart Association. *Circulation* 2016;**134**:e412–e460.
14. El-Dalati S, Cronin D, Riddell J, Shea M, Weinberg RL, Washer L, et al. The clinical impact of implementation of a multidisciplinary endocarditis team. *Ann Thorac Surg* 2022;**113**:118–124.
15. Roy AS, Hagh-Doust H, Abdul Azim A, Caceres J, Denholm JT, Dong MQD, et al. Multidisciplinary teams for the management of infective endocarditis: a systematic review and meta-analysis. *Open Forum Infect Dis* 2023;**10**:ofad444.

Downloaded from https://academic.oup.com/ehjcr/article/9/2/ytaf004/7954263 by guest on 20 February 2025