Received: 23 April 2019 | Revised: 14 June 2019 | Accepted: 12 August 2019

DOI: 10.1111/crj.13077

ORIGINAL ARTICLE

WILEY

Pleural dye marking of lung nodules by electromagnetic navigation bronchoscopy

Mark R. Bowling[1] | **Erik E. Folch**[2] | **Sandeep J. Khandhar**[3] | **Douglas A. Arenberg**[4] | **Omar Awais**[5] | **Douglas J. Minnich**[6] | **Michael A. Pritchett**[7] | **Otis B. Rickman**[8] | **Eric Sztejman**[9] | **Carlos J. Anciano**[1]

[1]Department of Internal Medicine, Division of Pulmonary, Critical Care and Sleep Medicine, Brody School of Medicine, East Carolina University, Greenville, North Carolina

[2]Massachusetts General Hospital, Harvard Medical School, Boston, Massachusetts

[3]Inova Health System, Virginia Cancer Specialists, Fairfax, Virginia

[4]Department of Internal Medicine, University of Michigan, Ann Arbor, Michigan

[5]University of Pittsburgh Medical Center, Mercy Health Center, Pittsburgh, Pennsylvania

[6]Division of Cardiothoracic Surgery, University of Alabama at Birmingham, Birmingham, Alabama

[7]Pinehurst Medical Clinic and FirstHealth Moore Regional Hospital, Pinehurst, North Carolina

[8]Vanderbilt University Medical Center, Nashville, Tennessee

[9]Virtua Medical Group, Marlton, New Jersey

Correspondence
Mark R. Bowling, Department of Internal Medicine, Division of Pulmonary, Critical Care and Sleep Medicine, Brody School of Medicine, East Carolina University, 521A Moye Blvd, Greenville, NC 27834.
Email: bowlingm@ecu.edu

Present address
Douglas J. Minnich, Princeton Baptist Medical Center, Birmingham, Alabama

Funding information
Medtronic

Abstract

Introduction: Electromagnetic navigation bronchoscopy (ENB)-guided pleural dye marking is useful to localize small peripheral pulmonary nodules for sublobar resection.

Objective: To report findings on the use of ENB-guided dye marking among participants in the NAVIGATE study.

Methods: NAVIGATE is a prospective, multicentre, global and observational cohort study of ENB use in patients with lung lesions. The current subgroup report is a prespecified 1-month interim analysis of ENB-guided pleural dye marking in the NAVIGATE United States cohort.

Results: The full United States cohort includes 1215 subjects from 29 sites (April 2015 to August 2016). Among those, 23 subjects (24 lesions) from seven sites underwent dye marking in preparation for surgical resection. ENB was conducted for dye marking alone in nine subjects while 14 underwent dye marking concurrent with lung lesion biopsy, lymph node biopsy and/or fiducial marker placement. The median nodule size was 10 mm (range 4-22) and 83.3% were <20 mm in diameter. Most lesions (95.5%) were located in the peripheral third of the lung, at a median of 3.0 mm from the pleura. The median ENB-specific procedure time was 11.5 minutes

Prior Presentation: Presented at the IASLC 18th World Conference on Lung Cancer, October 18, 2017 (Yokohama, Japan), Anciano et al. Journal of Thoracic Oncology. 2017;12:S1887.

 © 2019 John Wiley & Sons Ltd

(range 4-38). The median time from dye marking to resection was 0.5 hours (range 0.3-24). Dye marking was adequate for surgical resection in 91.3%. Surgical biopsies were malignant in 75% (18/24).

Conclusion: In this study, ENB-guided dye marking to localize lung lesions for surgery was safe, accurate and versatile. More information is needed about surgical practice patterns and the utility of localization procedures.

KEYWORDS

electromagnetic navigation bronchoscopy, lung cancer, lung nodule, pleural dye marking, video-assisted thoracoscopic surgery

1 | INTRODUCTION

Lung cancer is common and deadly.[1] Lung cancer screening will likely increase the incidence of small peripheral lung nodules and ground glass opacities detected by low-dose computed tomography (CT).[2] Surgical resection of these lesions is frequently done for diagnostic and therapeutic purposes. Minimally invasive techniques such as robot-assisted thoracoscopic surgery (RATS) and video-assisted thoracoscopic surgery (VATS) allow the surgeon to remove these lesions with a decrease in postoperative pain, air leak duration, length of hospital stay and overall complication rates with equivalent oncologic results to traditional open surgery.[3-5] However, these methods limit the surgeon's ability to identify lesions using bimanual palpation. This may be particularly challenging when the target nodule is small, further from the pleura, or predominately ground glass. While wires, fiducial markers, dyes and radiotracers percutaneously placed in or near the target lesion can aid in localization for resection,[6-11] small and non-solid nodules remain a challenge. Additionally, these techniques can be limited when performed outside the operating room. Wire dislodgement, widespread dye diffusion by the time of surgery and increased logistic requirements between hospital services may all result in failed localization, wider resections, increased conversion to open thoracotomy or repeat procedures.[12]

Electromagnetic navigation bronchoscopy (ENB) allows the surgeon or pulmonologist to mark lung lesions in the operating room just prior to the surgery.[12,13] This paper reports the findings on the use of ENB for pleural dye marking for surgical resection among participants in the NAVIGATE study. The objective of this subgroup analysis is to evaluate the ENB-guided dye marking usage patterns, techniques and performance in a multicentre experience. Results of ENB-guided fiducial marking in NAVIGATE have been previously published.[14]

2 | MATERIALS AND METHODS

NAVIGATE (www.clinicaltrials.gov, NCT02410837) is a prospective, multicentre, global, and single-arm cohort study evaluating ENB procedures.[14-17] All ENB procedures used the superDimension navigation system version 6.0 or higher (Medtronic, Minneapolis, MN). The success rate of dye marking demonstrated by successful surgical resection was prespecified as a secondary endpoint of the study. The current interim subgroup analysis presents the subset of NAVIGATE subjects from the United States (23/1215 subjects) who underwent ENB-guided pleural dye marking.

All consecutive, consented adult patients, who were not pregnant or nursing, and who were candidates for an elective ENB-guided dye marking procedure based on physician discretion per recommended guidelines and institutional standard-of-care, were eligible for enrolment. Subjects could also have concurrent lung lesion biopsy, fiducial marker placement or lymph node biopsy in the same procedure. The selection of patients for dye marking procedures, choice of dye, dye marking technique and all other complementary tools and procedures were performed at the operator's discretion. These choices were intentionally not mandated per protocol in order to provide a real-world multicentre evaluation of ENB usage patterns and outcomes.

Subjects were evaluated at baseline (within 30 days of the procedure), on the procedure day and at 1 month post-procedure. For the current subgroup analysis, prospectively captured endpoints included subject demographics, medical history and procedural characteristics (eg, anaesthesia type, concurrent imaging, procedure time, type of dye, time from dye placement to surgical resection and operator-reported adequacy for surgical resection). Prospectively captured complications included pneumothorax, bronchopulmonary hemorrhage and respiratory failure related to the ENB procedure or devices defined according to the validated Common

TABLE 1 Demographics and medical history ($n = 23$ subjects undergoing dye marking)

Age at consent (years)	66.0 [46.0-80.0] (23)
Female/Male	69.6%/30.4%
Tobacco history (current or former)	73.9% (17/23)
Current	17.6% (3/17)
Former	82.4% (14/17)
Chronic obstructive pulmonary disease	26.1% (6/23)
Asthma	26.1% (6/23)
FEV_1 (% of predicted)	104.0 [77.0-127.0] (11)
DLCO (% of predicted)	82.0 [51.0-128.0] (10)
Personal history of cancer	60.9% (14/23)

Note: Data are presented as % (*n*/*N* subjects) or median [range] (*N*).
Abbreviations: DLCO, diffusing capacity of the lung for carbon monoxide; FEV_1, forced expiratory volume in 1 second.

TABLE 2 Lesion characteristics ($n = 24$ lesions in 23 subjects)

Lung lesion size, mm	10.0 [4.0-22.0] (24)
<20 mm	83.3% (20/24)
≥20 mm	16.7% (4/24)
Lesion location	
Right upper lobe	25.0% (6/24)
Right middle lobe	4.2% (1/24)
Right lower lobe	29.2% (7/24)
Left upper lobe	25.0% (6/24)
Left lower lobe	16.7% (4/24)
Lung zone[a]	
Peripheral third of lung on CT	95.5% (21/22)
Middle third of lung on CT	4.5% (1/22)
Proximal third of lung on CT	0.0% (0/22)
Lesion visible on fluoroscopy	57.1% (12/21)[b]
Ground glass opacity (Suzuki Class 1 or 2)	9.1% (2/22)[b]
Spiculated lesion border	50.0% (10/20)[b]
Bronchus sign present on pre-procedure CT	12.5% (3/24)
Distance from lesion to pleura, mm	3.0 [0.0-48.0] (21)[b]

Note: Data are presented as % (*n*/*N* lesions) or median [range] (*N*).
[a]See Folch et al 2016 for definitions.[15] Missing lung zone data for two lesions.
[b]Missing fluoroscopy data for three lesions, GGO data for two lesions, border morphology data for four lesions and distance to pleura data for three lesions.

Terminology Criteria for Adverse Events scale and adjudicated by an independent medical monitor.[15]

Lesion characteristics (eg, size, location and morphology) and final diagnoses were prospectively captured in NAVIGATE for those lesions undergoing ENB-aided lung lesion biopsy but were not specifically captured for lesions undergoing ENB-aided pleural dye marking alone. Thus, lesion characteristics and final diagnoses based on surgical biopsy samples for dye marking cases were retrospectively captured by the operators using prospectively designed and independently monitored case report forms. The number of subjects with data for each variable is reported.

The ENB procedure and dye marking were conducted according to physician preferences and standard site practices. All operators used fluoroscopy during the dye marking procedure. There were slight variations by physician (see Online Supporting Information).

No sample size calculations were conducted for this single-arm, observational subgroup analysis. Analyses were performed using SAS Version 9.4 (SAS Inc., Cary, NC). Data were summarized by descriptive statistics, including frequency distributions and cross-tabulations for discrete variables and mean, standard deviation, median, minimum and maximum values for continuous variables. At least 20% of the data were verified against source files by the sponsor using risk-based monitoring.

3 | RESULTS

3.1 | Participants

A total of 1215 subjects were enrolled in the NAVIGATE United States cohort at 29 clinical sites (April 2015—August 2016).[17] Among those, 23 subjects (24 lesions) underwent pleural dye marking in preparation for surgical resection. Dye marking was conducted at seven sites by a single operator at each site (authors CA, DA, OA, DM, MP, OR and ES). A range of 1-6 subjects was enrolled per operator. Subject demographics and medical history are shown in Table 1.

3.2 | Lesion characteristics

Lesion characteristics are shown in Table 2. The median lung lesion size was 10.0 mm and 83.3% were less than 20 mm in

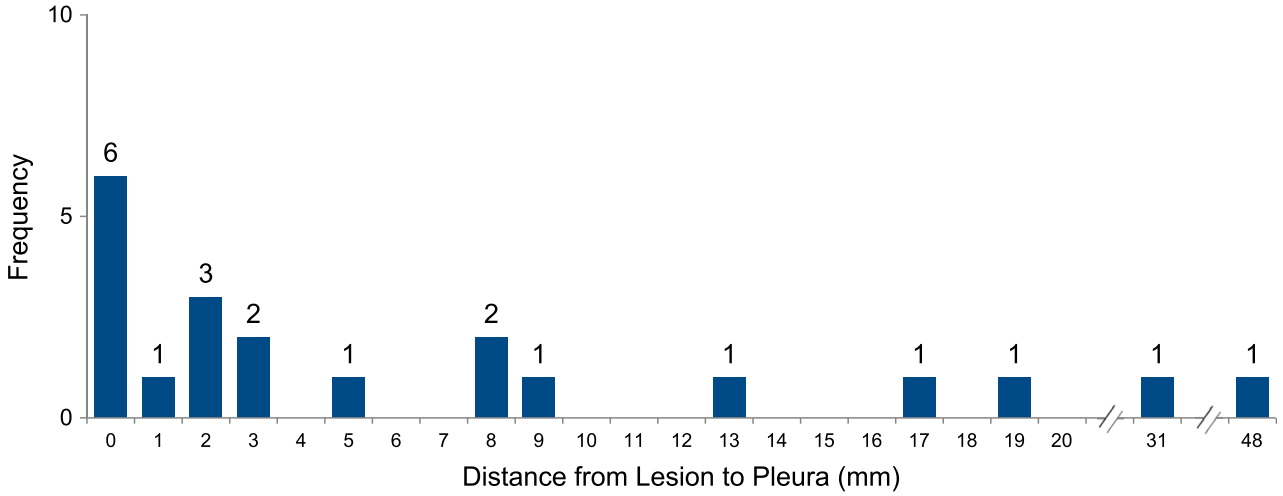

FIGURE 1 Distance from lesion to pleura

TABLE 3 Procedural characteristics ($n = 23$ procedures)

General anaesthesia	95.7% (22/23)
Moderate sedation	4.3% (1/23)
ENB software version	
Version 6	30.4% (7/23)
Version 7	69.6% (16/23)
Radial EBUS used during ENB procedure[a]	17.4% (4/23)
Cone beam CT used	8.7% (2/23)
Total procedure time (bronchoscope in/out), min	22.0 [6.0-167.0] (23)
ENB procedure time (EWC/LG in/out), min[b]	11.5 [4.0-38.0] (16)
Type of dye used	
Methylene blue	91.3% (21/23)
Methylene blue and omnipaque	4.3% (1/23)
Other (spot endoscopic marker)	4.3% (1/23)
Time from dye placement to surgical resection (hours)	0.5 (0.3-24.0) (22)
Dye marking adequate for subsequent surgical resection	91.3% (21/23)

Note: Data are presented as % (*n*/*N* procedures) or median [range] (*N*).
Abbreviations: CT, computed tomography; EBUS, endobronchial ultrasound; ENB, electromagnetic navigational bronchoscopy; EWC, extended working channel; LG, locatable guide.
[a]Other than for lymph node biopsy.
[b]Data only available for 16 subjects, because question was added to case report forms after enrolment had begun.

diameter. Half of the lesions were in the upper lobes and all but one was in the peripheral third of the lung. Two lesions were ground glass opacities. The median distance from the lesion to the pleura was 3.0 mm (range 0-48 mm, Figure 1). A bronchus sign was present on the pre-procedure CT scan in 12.5% (3/24).

3.3 | ENB procedural characteristics

Of the 23 subjects undergoing ENB-guided pleural dye marking, nine underwent dye marking alone (without lung lesion biopsy or fiducial placement), one underwent ENB-guided dye marking and ENB-guided lymph node biopsy, one underwent dye marking and lung lesion biopsy, six underwent dye marking and fiducial marker placement, and six underwent dye marking, lung lesion biopsy and fiducial marker placement. Subsequent surgical resection was attempted or conducted in all 23 subjects, as will be described below.

Characteristics of the ENB-guided dye marking procedures are shown in Table 3. General anaesthesia was used in 22/23 subjects. Fluoroscopy was used during the ENB-guided dye marking procedure in 21 cases and 57.1% of lesions were visible on fluoroscopy. Radial endobronchial ultrasound (EBUS) was used in 4/23. The total bronchoscopic procedure time was a median of 22.0 minutes. The ENB procedure time (first locatable guide/extended working channel entry to last exit) was a median of 11.5 minutes (range 4.0-38.0 minutes). Methylene blue dye was used in most cases (21/23).

3.4 | Complications

There were no instances of pneumothorax, bronchopulmonary hemorrhage, respiratory failure or death related to the ENB index procedure or devices among the 23 subjects undergoing dye marking.

3.5 | Surgical procedures and final diagnoses

Surgical resection was attempted in all subjects. The median time from dye marking to surgical resection was 30 minutes; surgery occurred within 1 hour of dye marking in all but one case in which it occurred 24 hours later.

Pleural dye placed under ENB guidance was visualized and considered adequate for surgical resection by the operator in 21/23 cases (91.3%). In one case, surgery occurred 30 minutes after dye marking and the thoracic surgeon noted that the methylene blue dye was not visible on the surface of the lung. However, concurrent fiducial marker placement in that case allowed confirmation of the lesion location. In the second case, an endoscopic dye as well as fiducial markers were placed. Left thoracoscopic upper lobe wedge resection, upper division segmentectomy (lingula-sparing) and mediastinal lymph node dissection were performed 24 hours after the ENB procedure. While the dye was not visible, the microcoil was present.

Surgical procedures were primarily done by VATS; there was one RATS procedure. Initial surgical approaches included 19 wedge resections, one segmentectomy and two lobectomies. In two cases, a wedge resection confirmed cancer and an open lobectomy was conducted in the same setting. One VATS procedure had to be aborted because of extensive adhesions when the patient refused more invasive approach.

Final diagnoses based on surgical biopsy are shown in Table 4. Among the 24 lesions (23 subjects), primary lung cancer was found in 13/24 (12 adenocarcinoma and one carcinoid tumour) and five were cancers of metastatic origin. The remaining six lesions were benign (one chondroid hamartoma, two granulomas and three with non-specific histologic findings).

4 | DISCUSSION

We report the findings of the only prospective, multicentre study to date evaluating the utility of ENB-guided pleural dye marking for surgical resection. Prior to NAVIGATE, all of the previous studies concerning preoperative localization for pulmonary nodules by any method have been either retrospective and/or a single centre experience.[12,18-20]

TABLE 4 Final diagnoses based on surgical biopsy ($n = 24$ lesions)

Malignant	75% (18/24)
Primary lung cancer	13/24
Adenocarcinoma	12/24
Carcinoid tumour	1/24
Metastatic carcinoma of extrathoracic origin[a]	5/24
Benign	25% (6/24)
Chondroid hamartoma	1/24
Non-specific histologic findings[b]	3/24
Granuloma	2/24

[a]Origin: Two renal, two colon and one thigh myxoid spindle cell.
[b]Organizing vasculature, anthracotic congestion.

In our cohort, there were no procedural complications and the dye marking was considered successful in 91% (21/23) of the cases. This is consistent with previous reports concerning ENB-guided pleural dye marking.[12,21-25] In comparison, localization with hookwire and CT-guided dye marking typically has success rates of 80-100% but with procedural related complications of 15%-50%,[9-11,26] higher than observed in the current ENB study. Additionally, hookwire dislodgment may result in failure to locate the lesion, thus requiring a conversion from a minimally invasive approach to a thoracotomy.[6,7,9,11,18]

In the current study, dye marking procedures were performed by seven physicians (four pulmonologists and three thoracic surgeons). The majority of dye marking procedures were done in the operating room just prior to the VATS or RATS, and all of the surgeons completed both the localization and the surgical procedure for their cases. One of the participants performed the dye marking procedure under moderate sedation in the endoscopy lab either the same day of the surgery or the day before the resection. The median bronchoscopy time was 22 minutes, which is faster than some previous studies (range 9.7-34.5 minutes).[12]

The median "waiting time" from the dye marking procedure to the VATS was 30 minutes in the current study. Bolton et al evaluated ENB-guided dye marking compared to CT-guided hookwire localization in 117 patients with small peripheral pulmonary nodules undergoing minimally invasive lung surgery. The waiting time was significantly longer with the CT-guided procedure compared to the ENB method (189 vs. 26 minutes, $P < .001$). Both techniques resulted in a 100% success rate and there were no conversions to a thoracotomy because of localization failure. A propensity matched analysis of same day CT-guided dye marking (30 patients) versus ENB-guided dye marking in the hybrid OR (15 patients) prior to VATS found similar localization success rates between the two methods but significantly shorter overall time from localization to surgery and a significantly lower pneumothorax rate in the ENB group (6.7% vs. 36.7%, $P = .03$).[27] Given our small cohort, we were unable to evaluate if the waiting time was shorter when localization was performed by the surgeon. However, since the majority of cases were done in the operating room under one anaesthetic episode just prior to the surgery, it is doubtful that this would have impacted the waiting time. Further investigation is required to evaluate the maximum operative efficiency concerning the timing, location and impact of the proceduralist related to ENB-guided localization.

In our study, 7/24 lesions had a biopsy of the target lesion at the same time as the dye marking procedure. In 2/7 of these patients, a definitive diagnosis of adenocarcinoma was obtained during the ENB procedure, which was confirmed by biopsy of the surgical specimen. A definitive diagnosis from a biopsy at the time of the localization procedure may

eliminate the need for a diagnostic wedge resection in the setting of primary lung cancer. If a malignant diagnosis is rendered, the surgeon can continue directly to a therapeutic lobectomy and if a non-malignant diagnosis is made, the patient may not need a surgical procedure at all in the appropriate clinical context. If a metastatic lesion is diagnosed, the surgeon may immediately proceed to a targeted parenchymal-sparing but oncologically sound resection. The versatility of ENB has been regularly reported in the literature.[12] Bolton et al described that in 19 patients with pulmonary nodules undergoing ENB-guided dye marking for localization for a diagnostic wedge resection, 74% (14/19) had an ENB-directed biopsy at the time of the localization procedure. Twenty-one percent (3/14) had a malignant diagnosis from the biopsy, as determined by rapid onsite pathologic examination and avoided the diagnostic wedge resection. These patients were able to proceed directly to a therapeutic lobectomy.[28] In a more recent study in patients with pulmonary nodules undergoing a diagnostic wedge resection, 75% (60/81) had a biopsy at the same time as the ENB-guided dye marking procedure. Twenty-seven percent (16/60) had a diagnosis of cancer, which changed the operative approach.[21] In contrast, in patients undergoing CT-guided hookwire localization, 0/36 had a biopsy in which 97% (35/36) had a wedge resection and one patient underwent a segmentectomy.[21]

While ENB was useful in localizing peripheral lung nodules in this analysis, fluoroscopy was also used in most cases and radial EBUS was used in four cases. However, the lesion was only visible by fluoroscopy in 12/21 cases. Radial EBUS has been shown effective for pleural dye marking in a recent study,[29] although lesion visualization may be challenging when the image is not concentric. The combined method of ENB, fluoroscopy and radial EBUS may be advantageous when indicated and available.

Despite the safety, accuracy and versatility of ENB-guided pleural dye marking for localization, it seemed to be an underutilized procedure in the NAVIGATE trial. Only 23 subjects out of 1215 subjects enrolled in the United States had a dye marking procedure. This is especially interesting given that in the overall NAVIGATE study, 63.6% were of a limited stage, 62.6% were located in the peripheral third of the lung[15] and 6.3% were classified as ground glass.[17] Of the 232 biopsy subjects with Stages I-II lung cancer in first interim analysis of NAVIGATE[16] there were 87 who had a surgical procedure and of those, 65 (75%) had no prior ENB-guided dye or fiducial marking. There have been 15 clinical studies (excluding single-patient case reports) concerning ENB-guided dye localization[12,21-24,27] and only three have enrolled over 50 patients.[21,30,31] These numbers suggest that perhaps dye marking is not underutilized, but rather not needed frequently. Further evaluation is required concerning the need for prior localization based on surgical practice patterns. A primary open thoracotomy approach in physicians not trained in VATS or RATS, lack of onsite pathology services or unavailability of interventional pulmonology or radiology teams to perform localization may all be contributing factors. The low proportion of ground glass lesions in NAVIGATE (6.3%) versus 17% (60/336) in other ENB-guided dye marking studies[12] could impact the use of localization techniques. Nonetheless, the authors note the majority of the cases were small solid or sub-solid lesions. This procedure may be particularly useful in the era of low-dose computed tomography screening for lung cancer, as we expect to find smaller resectable lung lesions. Thus, while not frequently used, ENB-guided dye localization is a safe, successful and efficient tool for the surgeon armamentarium with added benefits for surgical planning and parenchyma sparring interventions in the appropriate clinical settings.

Limitations of the study include a relatively small number of patients evaluated, as noted above, and the lack of a comparator group. In addition, the study did not identify why a localization procedure was not utilized. While the observational design allows an unrestricted, real-world snapshot of dye-marking practice patterns, the study was not designed to validate physician choice in patient selection for dye marking, dye marking methodology or surgical technique.

5 | CONCLUSIONS

In this multicentre study, ENB-guided dye marking for localization for lung surgery was safe, accurate and versatile. In prior studies, it has been shown to be as successful as other localization techniques with fewer complications, and biopsies can be performed at the same time as the dye marking procedure Despite the benefits, ENB-guided dye marking in NAVIGATE seems to be an underutilized procedure. More information is needed concerning surgeons' practice patterns, the need for localization and the most efficient method. Identification of these variables will also allow for improved cost analysis and implementation protocol recommendations.

ACKNOWLEDGMENTS

The study is sponsored and funded by Medtronic (Minneapolis, MN), which contributed to the study design, data collection and data analysis, and assisted with preparing the methods section and compiling figures and tables. The first and final drafts were written by the lead and senior authors. The lead authors (MRB and CJA) had full access to all study data and final responsibility for the decision to submit for publication. The authors were not paid to write this article by the sponsor or any other agency. Biostatistical analysis was provided by Haiying Lin of Medtronic. Technical and editorial assistance were provided by Kristin L. Hood PhD of Medtronic in accordance with Good Publication Practice (GPP3) guidelines.

DISCLOSURE

Study sponsored and funded by Medtronic. Financial disclosures related to the submitted work: All authors are NAVIGATE study investigators; EEF, SJK, MP, OR, and MRB: consultant fees from Medtronic; OR: research grant support from Medtronic. Financial disclosures outside the submitted work: EEF: consultant fees from Boston Scientific and Olympus; DA: consultant feeds from VisionGate and Nucleix; OA: consultant fees from Pinnacle Biologic.

AUTHOR CONTRIBUTIONS

All authors reviewed and approved the final version to be published.
Designed the overall NAVIGATE study in collaboration with the sponsor: Folch, Khandhar.
Designed the dye marking subset analysis, interpreted the data, and wrote the paper, with sections contributed by Drs. Folch and Khandhar: Bowling, Anciano.
Critical revisions and text edits: Arenberg, Awais, Minnich, Pritchett, Rickman, Sztejman.

ETHICS

This study is being conducted in accordance with the Declaration of Helsinki and all local regulatory requirements. The protocol was approved by the institutional review board of all participating clinical sites. Written informed consent was obtained for all subjects.

DATA AVAILABILITY STATEMENT

Compiled NAVIGATE data will be made publicly available on ClinicalTrials.gov (NCT02410837) after the completion of the 2-year follow-up. The interim data on which this paper is based are available from the corresponding author upon reasonable request.

ORCID

Mark R. Bowling https://orcid.org/0000-0002-3490-5647

REFERENCES

1. Siegel RL, Miller KD, Jemal A. Cancer statistics, 2019. *CA Cancer J Clin*. 2019;69(1):7-34.
2. Church TR, Black WC, Aberle DR, et al. Results of initial low-dose computed tomographic screening for lung cancer. *N Engl J Med*. 2013;368(21):1980-1991.
3. Villamizar NR, Darrabie MD, Burfeind WR, et al. Thoracoscopic lobectomy is associated with lower morbidity compared with thoracotomy. *J Thorac Cardiovasc Surg*. 2009;138(2):419-425.
4. Paul S, Altorki NK, Sheng S, et al. Thoracoscopic lobectomy is associated with lower morbidity than open lobectomy: a propensity-matched analysis from the STS database. *J Thorac Cardiovasc Surg*. 2010;139(2):366-378.
5. McKenna RJ Jr, Houck W, Fuller CB. Video-assisted thoracic surgery lobectomy: experience with 1100 cases. *Ann Thorac Surg*. 2006;81(2):421-426.
6. Mullan BF, Stanford W, Barnhart W, Galvin JR. Lung nodules: improved wire for CT-guided localization. *Radiology*. 1999;211(2):561-565.
7. Sharma A, McDermott S, Mathisen DJ, Shepard JO. Preoperative localization of lung nodules with fiducial markers: feasibility and technical considerations. *Ann Thorac Surg*. 2017;103(4):1114-1120.
8. Bellomi M, Veronesi G, Trifiro G, et al. Computed tomography-guided preoperative radiotracer localization of nonpalpable lung nodules. *Ann Thorac Surg*. 2010;90(6):1759-1764.
9. Shepard JA, Mathisen DJ, Muse VV, Bhalla M, McLoud TC. Needle localization of peripheral lung nodules for video-assisted thoracoscopic surgery. *Chest*. 1994;105(5):1559-1563.
10. Lenglinger FX, Schwarz CD, Artmann W. Localization of pulmonary nodules before thoracoscopic surgery: value of percutaneous staining with methylene blue. *Am J Roentgenol*. 1994;163(2):297-300.
11. Dendo S, Kanazawa S, Ando A, et al. Preoperative localization of small pulmonary lesions with a short hook wire and suture system: experience with 168 procedures. *Radiology*. 2002;225(2):511-518.
12. Speicher JE, Bowling MR, Anciano CJ. Bronchoscopically placed dye marking for minimally invasive thoracic surgery: a surgeon's perspective. *Clin Pulm Med*. 2017;24(6):239-249.
13. Ng CSH, Zhao Z, Long H, Lau RWH. Electromagnetic navigation bronchoscopy triple contrast dye marking for lung nodule localization. *Thorac Cardiovasc Surg*. 2019. https://doi.org/10.1055/s-0038-1676964
14. Bowling MR, Folch EE, Khandhar SJ, et al. Fiducial marker placement with electromagnetic navigation bronchoscopy: a subgroup analysis of the prospective, multicenter NAVIGATE study. *Ther Adv Respir Dis*. 2019;13:1–11.
15. Folch EE, Bowling MR, Gildea TR, et al. Design of a prospective, multicenter, global, cohort study of electromagnetic navigation bronchoscopy. *BMC Pulm Med*. 2016;16(1):60.
16. Khandhar SJ, Bowling MR, Flandes J, et al. Electromagnetic navigation bronchoscopy to access lung lesions in 1000 subjects: first results of the prospective, multicenter NAVIGATE study. *BMC Pulm Med*. 2017;17(1):59.
17. Folch EE, Pritchett MA, Nead MA, et al. Electromagnetic navigation bronchoscopy for peripheral pulmonary lesions: one-year results of the prospective, multicenter NAVIGATE study. *J Thorac Oncol*. 2019;14(3):445-458.
18. Ichinose J, Kohno T, Fujimori S, Harano T, Suzuki S. Efficacy and complications of computed tomography-guided hook wire localization. *Ann Thorac Surg*. 2013;96(4):1203-1208.
19. Christie S. Electromagnetic navigational bronchoscopy and robotic-assisted thoracic surgery. *Aorn J*. 2014;99(6):750-763.
20. Chen S, Zhou J, Zhang J, et al. Video-assisted thoracoscopic solitary pulmonary nodule resection after CT-guided hookwire localization: 43 cases report and literature review. *Surg Endosc*. 2011;25(6):1723-1729.
21. Bolton WD, Cochran T, Ben-Or S, et al. Electromagnetic navigational bronchoscopy reduces the time required for localization and resection of lung nodules. *Innovations*. 2017;12(5):333-337.

22. Pupovac SS, Chaudhry A, Singh VA. Benefits of electromagnetic navigational bronchoscopy for identifying pulmonary nodules for robotic resections. *Innovations*. 2017;12(6):418-420.
23. Cho HJ, Roknuggaman M, Han WS, Kang SK, Kang MW. Electromagnetic navigation bronchoscopy—Chungnam National University Hospital experience. *J Thorac Dis*. 2018;10(suppl. 6): S717-S724.
24. Han KN, Kim HK. The feasibility of electromagnetic navigational bronchoscopic localization with fluorescence and radiocontrast dyes for videoassisted thoracoscopic surgery resection. *J Thorac Dis*. 2018;10(suppl. 6):S739-S748.
25. Ng CSH, Chu CM, Lo CK, Lau RWH. Hybrid operating room Dyna-computed tomography combined image-guided electromagnetic navigation bronchoscopy dye marking and hookwire localization video-assisted thoracic surgery metastasectomy. *Interact Cardiovasc Thorac Surg*. 2018;26(2):338-340.
26. Grogan EL, Jones DR, Kozower BD, Simmons WD, Daniel TM. Identification of small lung nodules: technique of radiotracer-guided thoracoscopic biopsy. *Ann Thorac Surg*. 2008;85(2): S772-S777.
27. Kuo SW, Tseng YF, Dai KY, Chang YC, Chen KC, Lee JM. Electromagnetic navigation bronchoscopy localization versus percutaneous CT-guided localization for lung resection via video-assisted thoracoscopic surgery: a propensity-matched study. *J Clin Med*. 2019;8(3):379.
28. Bolton WD, Howe H 3rd, Stephenson JE. The utility of electromagnetic navigational bronchoscopy as a localization tool for robotic resection of small pulmonary nodules. *Ann Thorac Surg*. 2014;98(2):471-476.
29. Lachkar S, Baste J-M, Thiberville L, et al. Pleural dye marking using radial endobronchial ultrasound and virtual bronchoscopy before sublobar pulmonary resection for small peripheral nodules. *Respiration*. 2018;95(5):354-361.
30. Abbas A, Kadakia S, Ambur V, Muro K, Kaiser L. Intraoperative electromagnetic navigational bronchoscopic localization of small, deep, or subsolid pulmonary nodules. *J Thorac Cardiovasc Surg*. 2017;153(6):1581-1590.
31. Marino KA, Sullivan JL, Weksler B. Electromagnetic navigation bronchoscopy for identifying lung nodules for thoracoscopic resection. *Ann Thorac Surg*. 2016;102(2):454-457.

SUPPORTING INFORMATION

Additional supporting information may be found online in the Supporting Information section at the end of the article.

How to cite this article: Bowling MR, Folch EE, Khandhar SJ, et al. Pleural dye marking of lung nodules by electromagnetic navigation bronchoscopy. *Clin Respir J*. 2019;13:700–707. https://doi.org/10.1111/crj.13077