Journal of the American College of Cardiology
© 2003 by the American College of Cardiology Foundation
Published by Elsevier Science Inc.

Vol. 41, No. 5, 2003
ISSN 0735-1097/03/$30.00
doi:10.1016/S0735-1097(03)00081-0

EXPEDITED REVIEW

Autologous Skeletal Myoblasts Transplanted to Ischemia-Damaged Myocardium in Humans

Histological Analysis of Cell Survival and Differentiation

Francis D. Pagani, MD, PHD, FACC,* Harout DerSimonian, PHD,¶ Agatha Zawadzka, MS,¶ Kristie Wetzel, BS,¶ Albert S. B. Edge, PHD,¶ Douglas B. Jacoby, PHD,¶ Jonathan H. Dinsmore, PHD,¶ Susan Wright, BS, RN,* Tom H. Aretz, MD,‡ Howard J. Eisen, MD,§ Keith D. Aaronson, MD, MPH†

Ann Arbor, Michigan; Boston and Charlestown, Massachusetts; and Philadelphia, Pennsylvania

OBJECTIVES We report histological analysis of hearts from patients with end-stage heart disease who were transplanted with autologous skeletal myoblasts concurrent with left ventricular assist device (LVAD) implantation.

BACKGROUND Autologous skeletal myoblast transplantation is under investigation as a means to repair infarcted myocardium. To date, there is only indirect evidence to suggest survival of skeletal muscle in humans.

METHODS Five patients (all male; median age 60 years) with ischemic cardiomyopathy, refractory heart failure, and listed for heart transplantation underwent muscle biopsy from the quadriceps muscle. The muscle specimen was shipped to a cell isolation facility where myoblasts were isolated and grown. Patients received a transplant of 300 million cells concomitant with LVAD implantation. Four patients underwent LVAD explant after 68, 91, 141, and 191 days of LVAD support (three transplant, one LVAD death), respectively. One patient remains alive on LVAD support awaiting heart transplantation.

RESULTS Skeletal muscle cell survival and differentiation into mature myofibers were directly demonstrated in scarred myocardium from three of the four explanted hearts using an antibody against skeletal muscle-specific myosin heavy chain. An increase in small vessel formation was observed in one of three patients at the site of surviving myotubes, but not in adjacent tissue devoid of engrafted cells.

CONCLUSIONS These findings represent demonstration of autologous myoblast cell survival in human heart. The implanted skeletal myoblasts formed viable grafts in heavily scarred human myocardial tissue. These results establish the feasibility of myoblast transplants for myocardial repair in humans. (J Am Coll Cardiol 2003;41:879–88) © 2003 by the American College of Cardiology Foundation

Cell transplantation represents a novel therapeutic approach for the treatment of end-stage heart disease. Accumulating evidence from a number of studies suggests that myocardial function can improve after cell transplantation (1–8). Experimental studies have explored the use of a number of different cell types that include embryonic stem cells (9), cardiac myocytes (10), fetal or neonatal cardiomyocytes (11–15), skeletal myoblasts (7,16–21), fibroblasts (17), and hematopoietic stem cells (1–3,5,6,22). Skeletal muscle, because of its capacity to regenerate, has become an increasingly used source of cells for cardiac repair. Skeletal myoblasts are readily obtained by routine muscle biopsy, and autografts can be utilized to avoid the risk of graft rejection.

Injection of skeletal myoblasts in animal models of heart failure improves cardiac performance and, in most cases, is accompanied by histologic demonstration of graft survival (7,16–18,23–25). Recently, skeletal muscle cell transplantation has been performed in humans undergoing coronary artery bypass grafting for ischemic heart failure (26). However, to date, evidence for cell survival in humans is based on indirect measures of improvements in global or regional myocardial function (4). Further, because skeletal myoblast implantation studies in humans were performed in conjunction with coronary revascularization, the functional benefits attributed solely to skeletal myoblast implantation and hence, cell survival, become difficult to interpret in this experimental model. No histological evidence of skeletal myoblast survival in human heart, nor efficiency of cellular engraftment, exists for humans. For the appropriate feasibility of cardiac repair by cell transplants to be proven in humans, histologic confirmation of transplant survival and differentiation is essential.

We undertook a phase I clinical study to investigate the feasibility and safety of autologous skeletal muscle cell transplants in human patients with ischemic heart disease undergoing left ventricular assist device (LVAD) implanta-

From the *Section of Cardiac Surgery and †Division of Cardiology, University of Michigan, Ann Arbor, Michigan; ‡Department of Pathology, Massachusetts General Hospital, Boston, Massachusetts; §Temple University, Philadelphia, Pennsylvania; and ¶Diacrin, Inc., Charlestown, Massachusetts. The study was sponsored and funded by Diacrin, Inc., Charlestown, Massachusetts.

Manuscript received October 20, 2002; revised manuscript received January 19, 2003, accepted January 23, 2003.

JACC Vol. 41, No. 5, 2003
March 5, 2003:879–88

Abbreviations and Acronyms

EDTA = ethylenediaminetetraacetic acid
FACS = fluorescence activated cell sorting
LVAD = left ventricular assist device
mAb = monoclonal antibody

tion as a bridge to orthotopic heart transplantation. With this protocol, the viability of cell transplants can be evaluated histologically in recipient hearts after heart transplant.

METHODS

The phase I clinical study was approved by the Institutional Review Board for Human Studies (University of Michigan) and was conducted in accordance with federal guidelines under an approved investigational new drug and informed consent process. A total of 24 patients were screened for the trial. Ten patients were consented and underwent muscle biopsy. Five patients underwent LVAD implantation concurrent with myoblast transplantation. Five of 10 patients required urgent LVAD implantation before culturing sufficient numbers of myoblasts for injection.

Study subjects and protocol. All patients (n = 5) undergoing LVAD implantation concurrent with myoblast transplantation were male, with a median age of 60 years and a history of ischemic cardiomyopathy (Table 1). All were listed for heart transplantation at the time of LVAD implantation. All had a previous sternotomy for coronary artery bypass grafting. Median left ventricular ejection fraction was 15%. All patients were inotrope-dependent at the time of LVAD implantation. Median values for heart rate, systemic blood pressure, cardiac index, pulmonary capillary wedge pressure, and mean pulmonary artery pressure at the time of LVAD implantation were 83 beats/min, 76 mm Hg, 2.8 l/m^2/min, 18 mm Hg, and 33 mm Hg, respectively.

Muscle biopsies were taken from the right quadriceps muscle under sterile conditions using local anesthetics. The muscle specimens were immediately placed in transport medium and sent to a GMP isolation facility. Approximately four weeks after muscle biopsy (n = 4; 1 patient underwent cell transplant at 13 days after biopsy because of urgent need for LVAD implantation), all patients underwent LVAD implantation concurrent with myoblast transplantation. Multiple injections of autologous skeletal myoblasts were made into the anterior wall (n = 4) or lateral wall (n = 1) of the left ventricle using a 0.5- (n = 1) to 3-inch long (n = 4) 25- or 26-gauge needle (Table 1). Injection location was selected based upon echocardiography before surgery, and direct visualization during the surgical procedure. For all patients, 100-μl injections were delivered with a uniform spacing at a constant slow rate of delivery. All of the injections were made into a designated area within a myocardial infarct or border zone of the infarct, approximately 3 × 3 cm^2, and demarcated with

Table 1. Characteristics of the Patient Cohort Undergoing Skeletal Myoblast Transplantation

Patient	Age (yrs)	Year-Post-Infarct (First) and Location	Ejection Fraction	Number and Location (Left Ventricle) of Cells Transplanted	Viability of Transplanted Cells	% Myoblasts	Number of Injections at Operation	Days of LVAD Support
1	43	Unknown	5%–10%	2.2×10^6 Anterior wall	98%	75%	3	68
2	60	26 Anteroapical	20%–25%	300×10^6 Anterior wall	91%	97%	30	91
3	62	≥10 Anteroapical	15%–20%	300×10^6 Anterior wall	94%	62%	17	144
4	49	≥9 Anteroapical	20%	300×10^6 Anterior wall	91%	43%	7	On LVAD support awaiting transplant
5	65	22 Anteroapical	10%–15%	300×10^6 Anterolateral wall	97%	47%	38	191

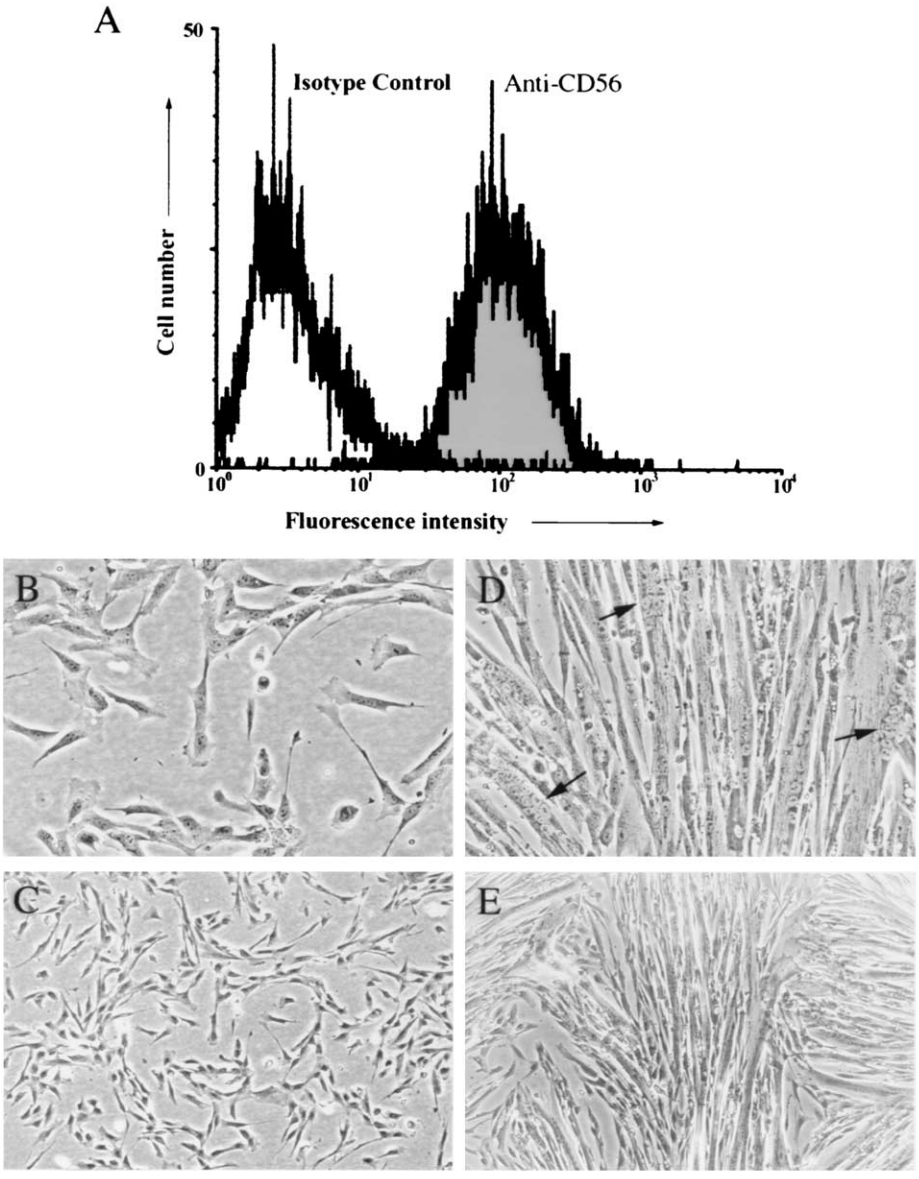

Figure 1. Human skeletal myoblast expansion and purity. **A** shows the anti-CD56 staining profile of the final myoblast product implanted to Patient 2 using flow cytometry. **B** (10×) and **C** (4×) show the myoblast cells in culture during expansion. **D** (10×) and **E** (4×) show the potential of these cells to fuse and form multinucleated myotubes in an in vitro assay. Some of these multinucleated myotubes are highlighted with **arrows in D**.

surgical clips. All injections were made before the initiation of cardiopulmonary bypass. The LVAD implant procedure was completed in the usual fashion.

After 68, 91, 144, and 191 days of LVAD support, four patients underwent LVAD explantation (three heart transplant, one LVAD death). At the time of LVAD explant, the portion of the left ventricle demarcated by the surgical clips was excised and fixed in formalin solution for histological analysis. Currently, one patient remains alive and well on LVAD support awaiting heart transplantation. The three patients surviving to heart transplantation remain alive and well at 1, 6, and 10 months, respectively.

Preparation of the autologous skeletal myoblasts. Approximately 2 g of skeletal muscle were obtained at each biopsy and subsequently stripped of connective tissue, minced into a slurry, and subjected to several cycles of enzymatic digestion at 37°C with trypsin/ethylenediaminetetraacetic acid (EDTA) (0.5 mg/ml trypsin, 0.53 mM EDTA; GibcoBRL) and collagenase (0.5 mg/ml; GibcoBRL) to release satellite cells. Skeletal myoblasts were cultured according to a modified Ham's method (27). Satellite cells were plated and grown in myoblast basal growth medium (SkBM; Clonetics) containing 15% to 20% fetal bovine serum (Hyclone), recombinant human epidermal growth factor

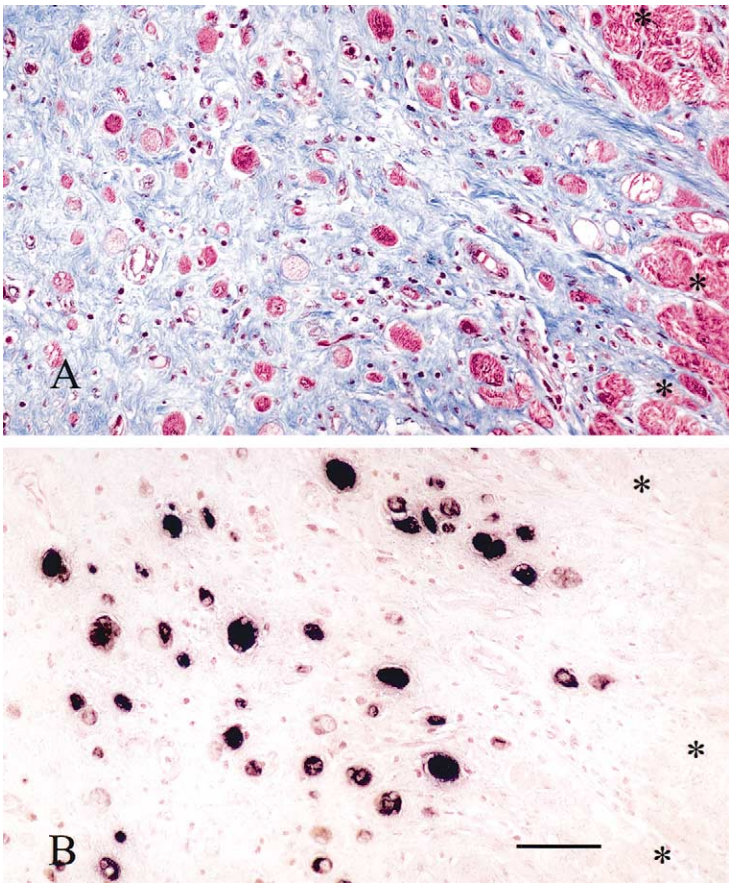

Figure 2. Representative trichrome and MY-32 stain of grafted skeletal myoblasts. **A** shows an area of the graft in a section stained with trichrome. **B** shows an adjacent section that was stained with the skeletal myosin specific MY-32 antibody. The transplant derived myofibers can be identified by the **red** staining in trichrome and the **dark blue** staining in the MY-32 stain. Asterisks (*) mark areas of host myocardial fibers. **Scale bar** = 50 μm.

(10 ng/ml), and dexamethasone (3 μg/ml). To avoid any possibility of myotube formation during the culture process, cell densities were maintained throughout the process so that <75% of the culture surface was occupied by cells. All cells were expanded for 11 to 12 doublings and were cryopreserved before transplant. After thaw, myoblasts (as single-cell suspension) were washed and suspended in transplantation medium at approximately 80 million cells per cc, loaded into five 1-cc tuberculin syringes, chilled to 4°C, and shipped on ice to the clinical center for transplant. At the time of transplant, cells were warmed to room temperature and injected without further manipulation. Viabilities for the cell suspension at the time of transplant were >90% (Table 1).

Myoblast purity was measured by reactivity with anti-CD-56 monoclonal antibody (mAb) (5.1H11, supplied by Dr. Robert Brown) using fluorescence-activated cell sorting (FACS). This antibody selectively stains human myoblasts and not fibroblasts (28). The percent myoblasts ranged from 43% to 97% (Table 1, Fig. 1). The ability of myoblasts to fuse into multinucleated myotubes in vitro was also confirmed by seeding 2×10^5 cells per 24-well tissue culture plate in growth medium. The following day, the culture medium was switched to fusion medium (Dulbecco's minimal essential medium with 0.1% bovine serum albumin and 50 ng/ml insulin-like growth factor), and cultures were observed three days later to assess fusion. Fusion was only used to confirm the presence of myoblasts. Cells were not fused before transplant. Sterility tests were conducted on the final product as well as throughout the digestion and expansion procedures.

Histological analysis and immunohistochemical techniques. Excised myocardium was fixed in formalin, cut into 2×3 cm blocks, and paraffin-embedded; 5 μ thick sections were cut, mounted, and stained with trichrome. For detection of skeletal muscle, deparaffinized sections were incubated with alkaline phosphatase-conjugated MY-32 mAb (Sigma-Aldrich, Inc., St. Louis, Missouri), a skeletal muscle reactive anti-myosin heavy chain antibody that does not stain cardiac muscle (29). Sections were developed with BCIP-NBT (Zymed Lab Inc.) and counterstained with nuclear red. Detection of slow-twitch myosin isoforms was performed with an antibody directed against myosin heavy chain beta (Clone NOQ7.5.4D, Chemicon, Temecula, California). For detection of vascular endothelial cells, sections were stained with anti-CD-31 mAb (Clone JC/70A, DAKO Corp., Carpenteria, California) and T cells with polyclonal rabbit anti-human CD3 reagent (DAKO).

Deparaffinized sections were stained and developed according to the manufacturer's recommendations. Incubation with secondary antibodies was performed according to instructions for Vectastain Mouse Elite or Vectastain Goat Elite Horse Radish Peroxidase conjugates (Vector Laboratories, Burlingame, California). Sections were developed with diaminobenzidine (DAB Substrate Kit; Vector Laboratories) and counterstained with hematoxylin.

For vascular endothelium quantitation, a total of six independent locations within the implanted regions were immunostained with anti-CD-31 mAb. Counts were performed in the region of the grafted cells and in the non-transplanted scar region immediately adjacent to the graft. Each field was photographed using an Olympus microscope with a 20× objective and a Kodak digital camera. The image was then acquired in Photoshop 5.0, and the entire field was counted for individual vascular elements. Counts were analyzed and statistical analysis performed by a Student *t* test for paired data. Statistical significance was defined at $p < 0.05$.

RESULTS

Skeletal myoblasts were expanded 11 to 13 population doublings in culture with an average doubling time of 29 h. Before transplantation, the population of cells contained only single cells and no fused multinucleated myoblasts. The myoblast purity of cell preparations varied between 43% and 97%, based on skeletal muscle-specific anti-CD-56 mAb staining and FACS analysis, with the remainder of the cells being composed of fibroblasts (Table 1, Fig. 1). The final myoblast preparation was characterized further by demonstrating the capacity to fuse and form multinucleated myotubes (Fig. 1).

Approximately 300×10^6 cells were transplanted using multiple injections into the left ventricular wall of each patient. The dose of cells was selected to provide sufficient histological evidence to demonstrate graft survival. We did not investigate for changes in regional function in this protocol. At the time of orthotopic heart transplantation, the explanted heart was fixed and sectioned. Surviving autologous skeletal muscle cells were identified in scarred tissue of the heart by trichrome staining in all patients except Patient 1 (Figs. 2 to 4). Patient 1 underwent injection with a suboptimal number of cells due to the urgent need for LVAD. Myofiber structures were identified within the transplanted region by the red trichrome stain characteristic of cardiac and skeletal muscle as opposed to the blue stain associated with fibroblasts and collagen of the scar (Figs. 2A, 3A, 3B, 4A, and 4B). Myofibers continued throughout several blocks of tissue spanning an area of approximately 1.2 cm in length and 2 cm in width for Patients 2 and 3, whereas in Patient 5, cells were present over the entire 3 × 3 cm target area. The red-stained myofiber tissue was confirmed to be of skeletal origin by staining for skeletal muscle-specific myosin heavy chain (Figs. 2B, 3C, and 4C).

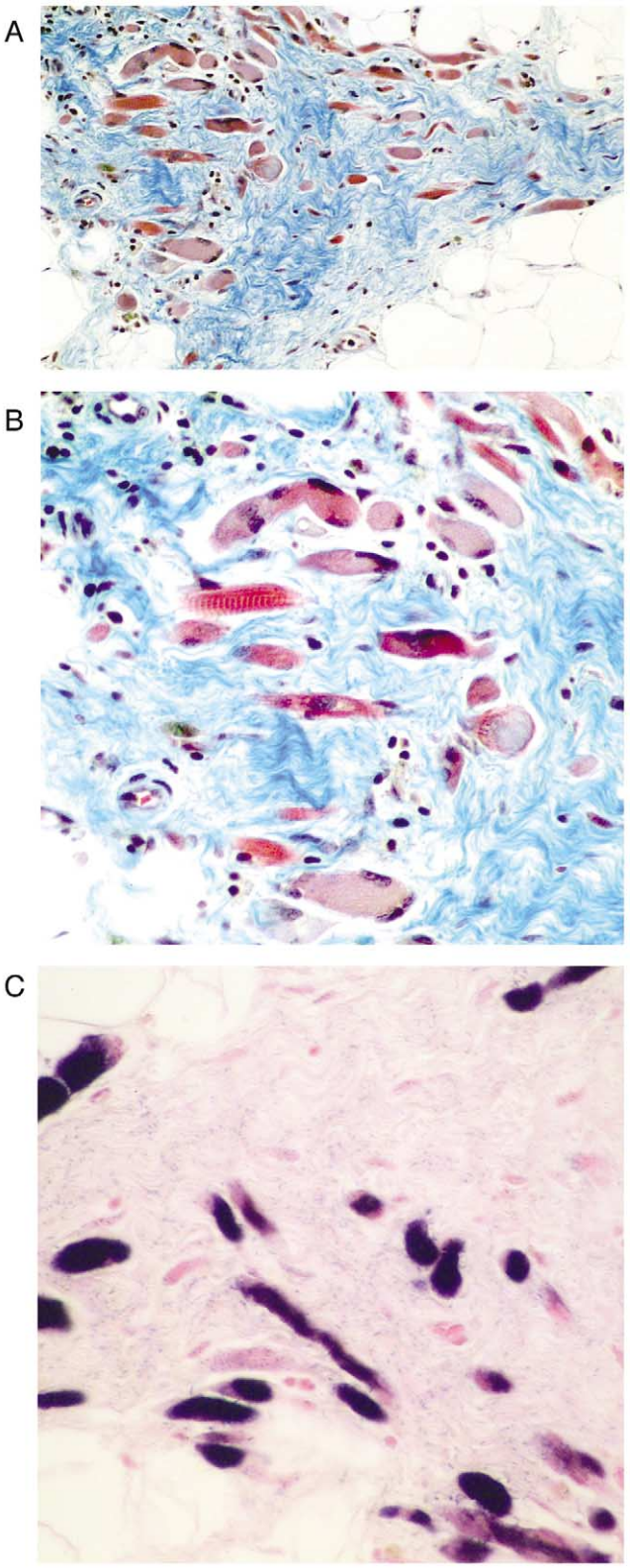

Figure 3. Representative trichrome and MY-32 stain of grafted skeletal myoblasts. **A and B** show an area of the graft in a section stained with trichrome at two magnifications. In **A**, the myotubes can be clearly identified, and in **B** the higher magnification shows the presence of striated myofibers in some myotubes. **C** shows an adjacent section that was stained with the skeletal myosin specific MY-32 antibody.

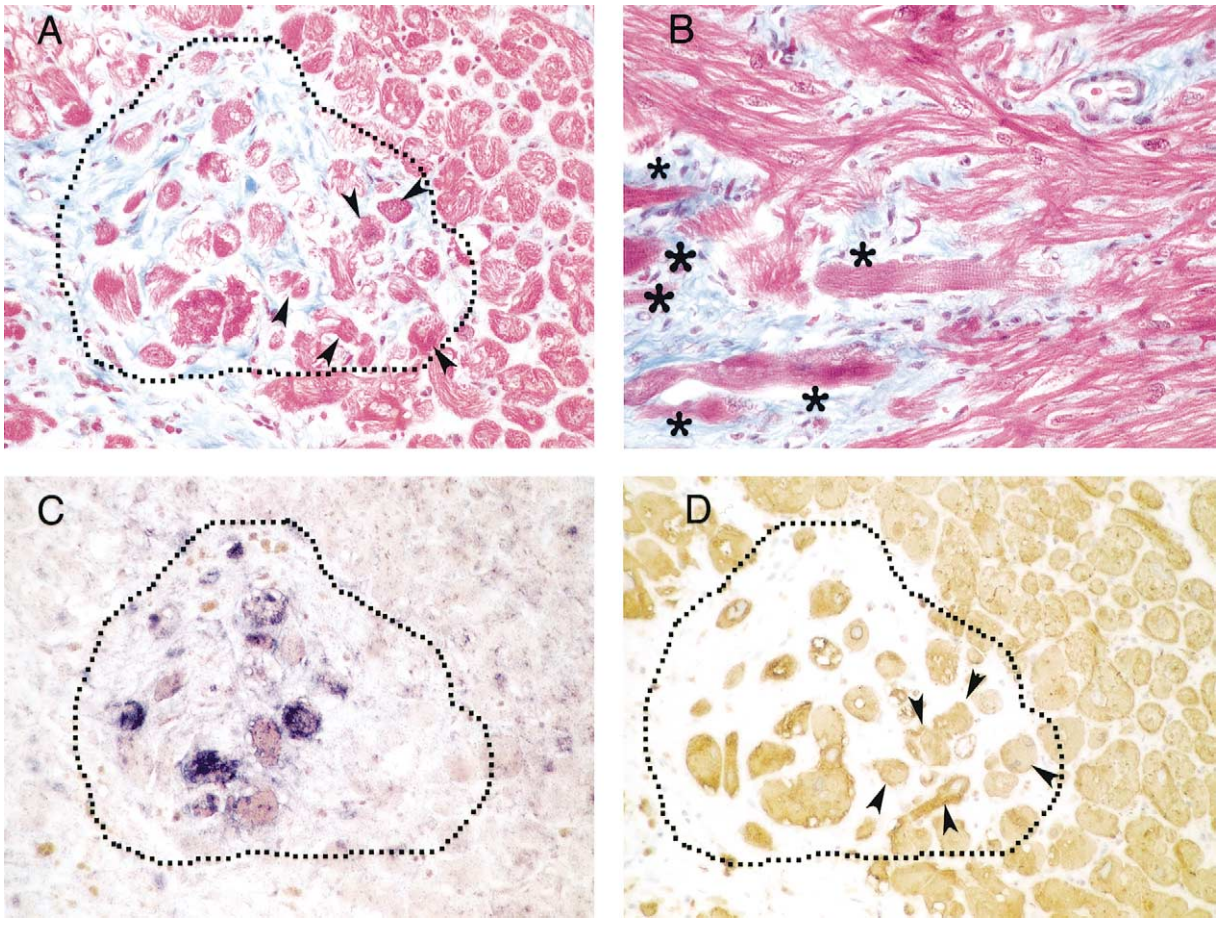

Figure 4. Skeletal fast and slow twitch myosin. Shown are surviving skeletal myofibers in the heart from Patient 5 stained with trichrome **(A and B)**, skeletal-specific fast myosin MY-32 (identification of fast twitch skeletal muscle myosin isoforms only) **(C)** and myosin heavy chain beta slow **(D)**. **A, C, and D** show adjacent sections from the same graft site, and **B** shows a different graft site from the same patient, but where the myofibers can be seen in a longitudinal profile. Grafted skeletal myofibers have a distinct stain by trichrome that are marked by **stars in B,** and the alignment between grafted myofibers and host myofibers is striking. The area of the graft is marked by the **dotted line in A, C, and D** and individual skeletal myofibers that stained with slow myosin and not fast myosin (MY-32, **C**) are marked by **arrowheads**. All images were shot at the same magnification.

Only the transplanted skeletal muscle fibers stain for muscle-specific myosin heavy chain and not the host cardiac muscle fibers. Additionally, most of the transplant-associated myofibers were aligned in parallel with the host myocardial fibers (Figs. 2 and 4). No differences in morphology or survival of transplanted cells were noted between implants within scarred myocardium or adjacent to healthy myocardium (Figs. 2A, 2B, and 4). Additionally, slow-twitch myosin isoforms were identified within surviving skeletal myoblasts using an antibody directed against myosin heavy chain beta (Fig. 4).

Total myoblast cell survival was calculated to be <1% based on a delivered dose of 300 million cells for Patients 2 and 3 (see Discussion) and was not calculated for Patient 5. Cell survival was estimated by assuming 100% delivery of cells, performing cell counts on sequential serial sections throughout the graft, and using the method of Abercrombie to correct for double counting of cells (30).

To assess the presence of inflammatory cells associated with autologous myoblast grafts, H&E staining was also used. There was little or no evidence of lymphocyte infiltration associated with either grafted or non-grafted areas. This conclusion was confirmed with T-cell specific anti-CD3 polyclonal antibody immunohistochemical staining (Fig. 5). There were also examples of multinucleated giant cells detected in and around the grafts, but not in non-grafted myocardium (Fig. 6). The giant cells were seen in association with refractile material likely introduced during injection of cells.

Immunohistochemical staining was also performed to assess the presence of vascular endothelium in grafted and non-grafted myocardium using an anti-CD-31 mAb (Fig. 7). Quantitative measurement from six independent graft areas from a representative patient showed significantly more CD-31 stained vessels at the sites of surviving grafts (Figs. 7A and 7B) as compared with the number of vessels in the corresponding non-grafted scar tissue (228 ± 24 cells per field in grafted area vs. 72 ± 17 cells per field in non-grafted area, respectively; $p < 0.0001$) (Fig. 7B).

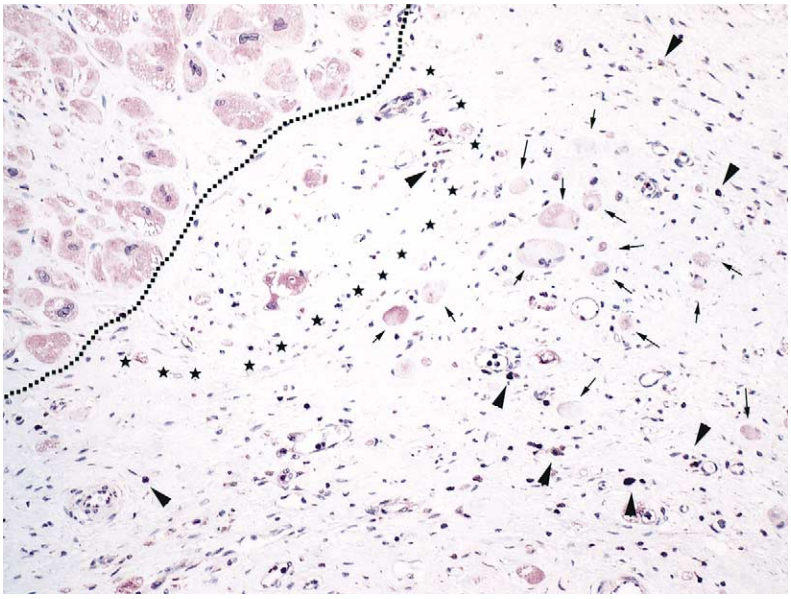

Figure 5. Representative CD-3 staining of a graft site. The micrograph shows a graft site stained with an antibody to CD-3 to stain immune cells. Some scattered macrophages can be identified in and around the graft site. Some of the macrophages can be seen in association with an area of the containing giant cells. There is no collection of infiltrating immune cells at the graft site to indicate any ongoing immune reaction. The **dotted line** demarcates an area of viable myocardium. The **stars** highlight the area with giant cells. **Arrows** mark the surviving transplanted muscle cells, and the **arrowheads** mark the CD-3 positive macrophages.

ADVERSE EVENTS

No minor or major adverse events occurred related to the cell transplant procedures or implant process. Major serious adverse events reported included death secondary to sepsis from a drive line site infection 68 days after LVAD implantation (Patient 1); drive line site infection requiring hospitalization for intravenous antibiotics (Patient 4); and reoperation for bleeding on postoperative day 1 for coagulopathy not related to the cell transplant injection site (Patient 3). Four patients experienced cardiac arrhythmias. Patients 2 and 4 experienced postoperative atrial fibrillation. Patient 2 experienced ventricular tachycardia at the initiation of cardiopulmonary bypass after a period of hypotension that required cardioversion. Patients 3 and 5 both experienced brief episodes of ventricular tachycardia in the immediate postoperative period that resolved with beta-blockers and amiodarone therapy. All but one patient (Patient 5) had a history significant for ventricular arrhythmias. Preoperative history and holter monitoring documented nonsustained ventricular tachycardia (Patients 2, 3, and 4), atrial fibrillation (Patient 4), and intraventricular conduction delay (Patient 2). Patients 3 and 4 underwent implantation of a cardiac defibrillator more than one year before LVAD implantation. No clinically detected cerebrovascular events, strokes, or peripheral embolic events occurred in any patient.

DISCUSSION

This study provides evidence for skeletal myoblast survival and differentiation in human myocardium. Areas of surviving myoblasts were identified in trichrome-stained sections and confirmed by use of the skeletal muscle-specific myosin heavy chain antibody, MY-32. The dose of cells injected was calculated based on animal studies to assess viability and differentiation. This study was not designed to investigate for regional improvements in myocardial function.

Animal models of myocardial infarction have demonstrated the principle that skeletal myoblasts can be expanded and transplanted into the heart (7,16–18,23–25). However, human demonstration of myoblast transplantation has been limited to one study that showed symptomatic improvement with no direct evidence for cell survival (26). In that study, myoblast transplantation was performed in conjunction with coronary revascularization. Survival of transplanted cells was inferred from improvements by positron emission tomography in deoxyglucose metabolism and cardiac pumping efficiency. Because of the revascularization performed, the degree of functional improvement attributable solely to myoblast implantation or estimates of the efficiency of myoblast engraftment and differentiation cannot be determined.

We have previously shown that myosin heavy chain staining is associated with rodent myoblast fusion and myofiber formation (16). In that experimental study, myosin heavy chain was not expressed in myoblasts early after engraftment. However, with time, cells fused into myotubes, differentiated into myofibers, and expressed myosin heavy chain. We have not observed myosin heavy chain staining before myoblast fusion and myofiber formation. Thus, areas staining for myosin heavy chain within the human grafts represent myoblasts that have survived trans-

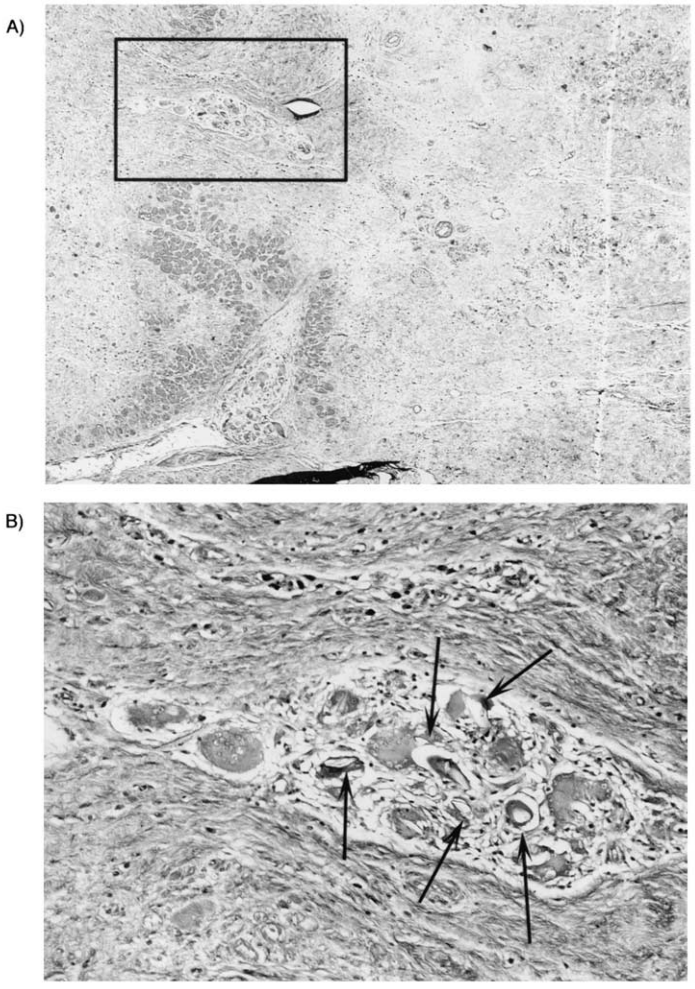

Figure 6. Trichrome staining of a graft site demonstrating the presence of giant cells. **A and B** show an area adjacent to the grafted cells where giant cells have formed. The **boxed area in A** is shown at higher magnification in **B**. Multinucleated giant cells are associated with refractile material **(arrows)**, probably plastic that was introduced with the cells. Note that the area of engrafted cells is free from any giant cells.

plantation and gone on to fuse and form myofibers as they would in situ in skeletal muscle. Additionally, evidence of skeletal myoblast differentiation with expression of slow-twitch myosin isoforms was observed in surviving grafts. It is noteworthy that the majority of myofibers surviving in the human heart have aligned in parallel with the host myocardial fibers. This observation suggests a potential for productive synchronous contraction, or structural enhancement, both of which could contribute to improvements in systolic or diastolic function or ameliorate remodeling. However, the potential for synchronous contraction would need to be confirmed by investigating for gap junction formation with immunostaining with anti-connexin 43 antibodies and through investigation with electron microscopy (20,31). In the absence of these data, statements regarding the proposed mechanism by which skeletal muscle implants may offer improvement in myocardial function are significantly limited.

Areas of myoblast engraftment demonstrated healthy graft morphology even though the cells were located in some cases in a large area containing a mature scar. Further, there was a significant increase in the number of blood vessels associated with the graft sites documented in one patient. New vessels were formed in the area of the grafts, and such vasculogenesis may be necessary for long-term survival of the transplanted cells. Whether this observed increase in vasculogenesis is a consequence of myoblast engraftment or localized trauma from needle site injections is unknown at this time. Alternatively, myoblast survival and differentiation may have occurred only in those areas of infarct that had pre-existing improvements in microvessel formation. Additionally, these data demonstrate that simultaneous revascularization with coronary artery bypass grafting or percutaneous revascularization with stent or angioplasty is not a requirement for successful graft survival.

Equally important to the observed increase in vessel formation was the lack of an ongoing immune reaction to skeletal myoblast transplant. Cells were cultured in the presence of foreign proteins during the expansion of the cells that could act as a stimulus for an immune response.

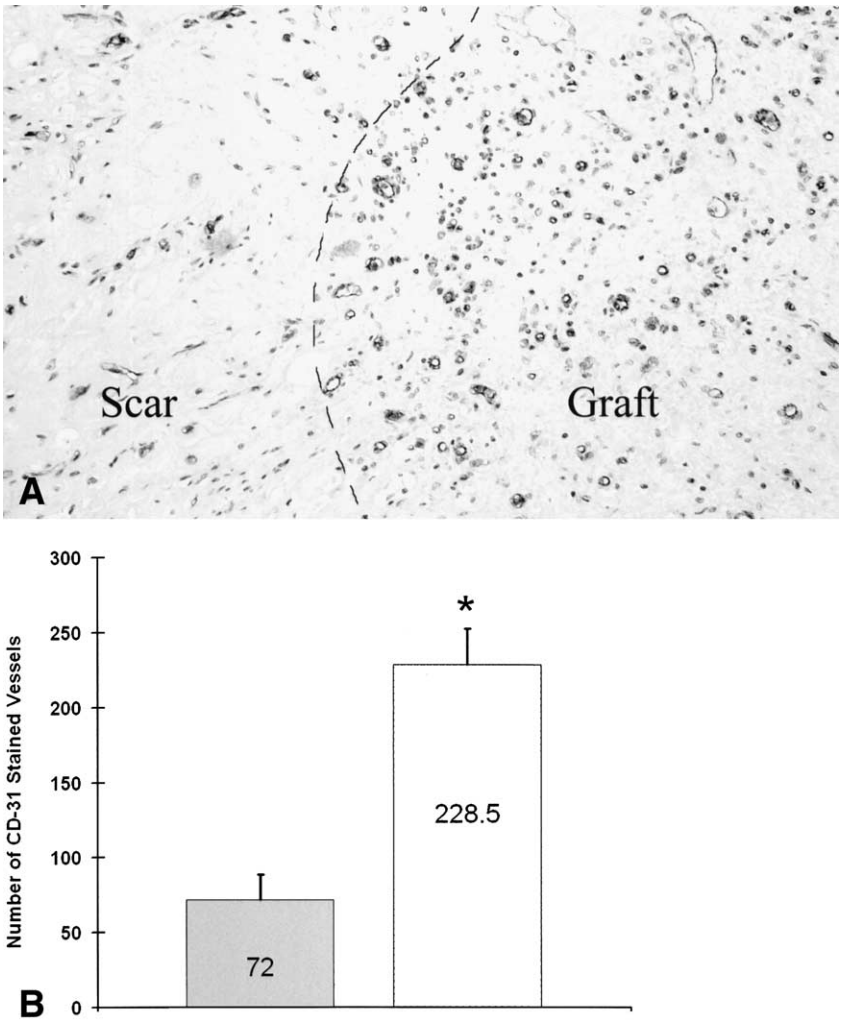

Figure 7. Representative CD-31 staining of a graft site. An antibody to human CD-31 was used to stain graft sections. **A** shows a representative micrograph in the area of the graft. The **dotted line** demarcates the border area between the transplant and the adjacent scar. Note the enhanced area of CD-31 staining within the engrafted section. **B** shows the results from quantitative counts to compare the number of CD-31 vessels at the graft **(white bar)** and in the adjacent scar **(gray bar)**. **Scale bar** = 100 μm.

However, we saw no evidence of an immune response. Multinucleated giant cells within areas of the transplants were present in only a few of the sections examined. These cells were always associated with refractile, non-cellular material that may have been introduced at the time of the cell injection.

Quantitation of the number of total cells surviving transplant is difficult to calculate accurately. We found surviving cells associated with all identified needle tracts. Moreover, not all cells are successfully delivered to the myocardium. We did note leakage of cells from the myocardium after injection of myoblasts into the heart. In particular, in Patient 3 we found large numbers of surviving myotubes associated with epicardial fat, evidence that cells had leaked back from the injection site. Thus, because we cannot determine the actual number of cells successfully injected, our assumptions on cell survival are based on the 100% delivery of cells. Ultimately, the efficiency of engraftment will have to wait for results from continuing patient studies. Further, efforts are under way to determine the most effective method of cell delivery to the myocardium, and likely significant gains in efficiency will be made through those studies.

One of the limitations of this study was the absence of functional data. We specifically designed the experimental protocol not to look for efficacy of cellular transplants. This does not rule out that some degree of improvement from skeletal muscle transplant may have occurred, but rather we did not specifically investigate for it. One of the most accurate methods for determining functional improvement in regional myocardial segments, magnetic resonance imaging, was not feasible in this patient population owing to the presence of the LVAD. Thus, because of this limitation, the relatively low number of cell transplants, and the small area injected (3 cm by 3 cm), we chose not to design our protocol to look for functional improvement using less sensitive indicators of regional myocardial function.

Cell transplants are rapidly advancing as a potential new

therapy. Our data demonstrate the feasibility of myoblast cell transplantation as a potential treatment for cardiac disease. Further studies are warranted in this new area of medical therapy, in particular to correlate cell survival with clinical improvement in cardiac function. This study clearly verifies that survival and differentiation patterns observed in animals can also be obtained in human patients with chronic ischemic cardiac damage.

Acknowledgment

We thank James Udelson, MD, (New England Medical Center, Boston, MA) for his critical comments on the manuscript.

Reprint requests and correspondence: Dr. Francis D. Pagani, Associate Professor of Surgery, Director, Heart Transplant Program, Section of Cardiac Surgery, 2120 Taubman Center, Box 3480, 1500 East Medical Center Drive, Ann Arbor, Michigan 48109. E-mail: fpagani@umich.edu.

REFERENCES

1. Jackson KA, Majka SM, Wang H, et al. Regeneration of ischemic cardiac muscle and vascular endothelium by adult stem cells. J Clin Invest 2001;107:1395–402.
2. Kamihata H, Matsubara H, Nishiue T, et al. Implantation of bone marrow mononuclear cells into ischemic myocardium enhances collateral perfusion and regional function via side supply of angioblasts, angiogenic ligands, and cytokines. Circulation 2001;104:1046–52.
3. Kocher AA, Schuster MD, Szabolcs MJ, et al. Neovascularization of ischemic myocardium by human bone marrow-derived angioblasts prevents cardiomyocyte apoptosis, reduces remodeling and improves cardiac function. Nat Med 2001;7:430–6.
4. Menasche P, Hagege AA, Scorsin M, et al. Myoblast transplantation for heart failure. Lancet 2001;357:279–80.
5. Orlic D, Kajstura J, Chimenti S, et al. Bone marrow cells regenerate infarcted myocardium. Nature 2001;410:701–5.
6. Orlic D, Kajstura J, Chimenti S, et al. Mobilized bone marrow cells repair the infarcted heart, improving function and survival. Proc Natl Acad Sci USA 2001;98:10344–9.
7. Taylor DA, Atkins BZ, Hungspreugs P, et al. Regenerating functional myocardium: improved performance after skeletal myoblast transplantation. Nat Med 1998;4:929–33.
8. Kessler PD, Byrne BJ. Myoblast cell grafting into heart muscle: cellular biology and potential applications. Annu Rev Physiol 1999;61:219–42.
9. Klug MG, Soonpaa MH, Koh GY, Field LJ. Genetically selected cardiomyocytes from differentiating embronic stem cells form stable intracardiac grafts. J Clin Invest 1996;98:216–24.
10. Yoo KJ, Li RK, Weisel RD, et al. Heart cell transplantation improves heart function in dilated cardiomyopathic hamsters. Circulation 2000; 102 Suppl 3:III204–9.
11. Koh GY, Soonpaa MH, Klug MG, et al. Stable fetal cardiomyocyte grafts in the hearts of dystrophic mice and dogs. J Clin Invest 1995;96:2034–42.
12. Li RK, Jia ZQ, Weisel RD, et al. Cardiomyocyte transplantation improves heart function. Ann Thorac Surg 1996;62:654–60, discussion 660–1.
13. Scorsin M, Hagege AA, Marotte F, et al. Does transplantation of cardiomyocytes improve function of infarcted myocardium? Circulation 1997;96 Suppl:II188–93.
14. Scorsin M, Hagege AA, Dolizy I, et al. Can cellular transplantation improve function in doxorubicin-induced heart failure? Circulation 1998;98 Suppl:II151–5, discussion II155–6.
15. Soonpaa MH, Koh GY, Klug MG, Field LJ. Formation of nascent intercalated disks between grafted fetal cardiomyocytes and host myocardium. Science 1994;264:98–101.
16. Jain M, DerSimonian H, Brenner DA, et al. Cell therapy attenuates deleterious ventricular remodeling and improves cardiac performance after myocardial infarction. Circulation 2001;103:1920–7.
17. Hutcheson KA, Atkins BZ, Hueman MT, et al. Comparison of benefits on myocardial performance of cellular cardiomyoplasty with skeletal myoblasts and fibroblasts. Cell Transplant 2000;9:359–68.
18. Atkins BZ, Hueman MT, Meuchel J, et al. Cellular cardiomyoplasty improves diastolic properties of injured heart. J Surg Res 1999;85:234–42.
19. Murry CE, Wiseman RW, Schwartz SM, et al. Skeletal myoblast transplantation for repair of myocardial necrosis. J Clin Invest 1996; 98:2512–23.
20. Reinecke H, MacDonald GH, Hauschka SD, Murry CE. Electromechanical coupling between skeletal and cardiac muscle. Implications for infarct repair. J Cell Biol 2000;149:731–40.
21. Chiu RC, Zibaitis A, Kao RL. Cellular cardiomyoplasty: myocardial regeneration with satellite cell implantation. Ann Thorac Surg 1995; 60:12–8.
22. Tomita S, Li RK, Weisel RD, et al. Autologous transplantation of bone marrow cells improves damaged heart function. Circulation 1999;100 Suppl:II247–56.
23. Pouzet B, Vilquin JT, Hagege AA, et al. Intramyocardial transplantation of autologous myoblasts: can tissue processing be optimized? Circulation 2000;102 Suppl 3:III210–5.
24. Pouzet B, Vilquin JT, Hagege AA, et al. Factors affecting functional outcome after autologous skeletal myoblast transplantation. Ann Thorac Surg 2001;71:844–50, discussion 850–1.
25. Scorsin M, Hagege A, Vilquin JT, et al. Comparison of the effects of fetal cardiomyocyte and skeletal myoblast transplantation on postinfarction left ventricular function. J Thorac Cardiovasc Surg 2000;119: 1169–75.
26. Menesché P, Vilquin JT, Desnos M, et al. Early results of autologous skeletal myoblast transplantation in patients with severe ischemic heart failure. Circulation 2001;104:II598.
27. Ham RG, St Clair JA, Meyer SD. Improved media for rapid clonal growth of normal human skeletal muscle satellite cells. Adv Exp Med Biol 1990;280:193–9.
28. Webster C, Pavlath GK, Parks DR, Walsh FS, Blau HM. Isolation of human myoblasts with the fluorescence-activated cell sorter. Exp Cell Res 1988;174:252–65.
29. Havenith MG, Visser R, Schrijvers-van Schendel JM, Bosman FT. Muscle fiber typing in routinely processed skeletal muscle with monoclonal antibodies. Histochemistry 1990;93:497–9.
30. Abercrombie M. Estimation of nuclear population from microtome sections. Anat Rec 1946;94:239–47.
31. Saffitz JE, Green KG, Kraft WJ, Schechtman KB, Yamada KA. Effects of diminished expression of connexin-43 on gap junction number and size in ventricular myocardium. Am J Physiol Heart Circ Physiol 2000;278:H1662–70.