British Journal of Dermatology 2003; **148 (Suppl. 63):** 3–10.

International Consensus Conference on Atopic Dermatitis II (ICCAD II*): clinical update and current treatment strategies

C.ELLIS* AND T.LUGER† ON BEHALF OF THE ICCAD II FACULTY: D.ABECK, R.ALLEN, R.A.C.GRAHAM-BROWN, Y.DE PROST, L.F.EICHENFIELD, C.FERRANDIZ, A.GIANNETTI, J.HANIFIN, J.Y.M.KOO, D.LEUNG, C.LYNDE, J.RING, R.RUIZ-MALDONADO AND J-H.SAURAT

*Department of of Dermatology, University of Michigan Medical Center, Ann Arbor, Michigan, U.S.A.
†Department of Dermatology, University of Münster, Münster, Germany.

Atopic dermatitis

Atopic dermatitis (AD) is a common chronic relapsing inflammatory skin disease, characterized by intense itching, dry skin, inflammation and exudation. It causes physical and emotional distress for patients and their families. The first symptoms commonly develop in infancy, with around 50% of cases diagnosed by 1 year of age,[1] and AD is typically a long-term condition with at least one-third of patients having persistent disease throughout adulthood. However the vast majority of cases of atopic dermatitis are mild in severity and usually can be managed easily.[2] The disease is often familial and frequently associated with asthma, food allergy, allergic rhinitis and recurrent secondary skin infections. Atopic dermatitis has significant impact on quality of life in both children[3] and adults.[4] The impact is greater than with psoriasis and is equivalent to other serious medical conditions such as early onset of diabetes mellitus.[5] The prevalence of atopic dermatitis has increased steadily in recent decades.[4] In developed countries approximately 10–15% of children under 5 years of age are affected at some stage.[4] The likelihood is that 60% of children with atopic dermatitis may recover free of the disease, the remainder having recurrences for long periods of time.[6] It has also been suggested that the best prognosis for the disease is in those children who developed AD in the first year of life.[7] However, overall the earlier the onset and the more severe the disease, there is a greater chance of persistence, especially with concurrent atopic disorders.

Correspondence: Dr C. Ellis, Department of of Dermatology, University of Michigan Medical Center, Ann Arbor, Michigan, USA
E-mail: cellis@med.umich.edu

*The first ICCAD meeting was held in Rome in 1999, the proceedings of which were published in the *Journal of the American Academy of Dermatology* (2001;45: S1–67).

Recent evidence has indicated a common pathophysiological link between severe atopic dermatitis, asthma and allergic rhinitis[8,9] (for example both asthma and AD are associated with increased IgE and eosinophilia). It has been suggested that atopic dermatitis may increase the subsequent risk or severity of asthma.[10]

Current management of atopic dermatitis

At present there is no 100% life-long cure for atopic dermatitis. Management comprises a disease adapted treatment combining adjuvant basic therapy (skin protection) and, if needed, anti-inflammatory measurements and the identification and avoidance of trigger factors.[11,12] Treatment currently focuses on symptomatic relief (skin hydration and reduction of pruritus).[13–15]

Therapeutic options

Adjuvant basic therapy As the barrier function of the skin in patients with atopic dermatitis is impaired, an adjuvant basic therapy is essential in the management of this disease consisting of the regular application of adequate moisturizers. Different classes of moisturisers are based on their mechanism of action, including occlusives, humectants, emollients and protein rejuvenators. Patients may be prescribed different moisturizers depending on their particular preference, their age and their type of eczema. Emollients keep the skin hydrated and can reduce itching. They should be applied regularly at least twice during the day, even when there are no symptoms of disease and should also be applied after swimming or bathing.

Topical steroids as the current standard for anti-inflammatory therapy Intermittent use of topical corticosteroids to treat the signs and symptoms of atopic dermatitis, in conjunction with emollients, has been the standard

© 2003 British Association of Dermatologists

disease management. Topical corticosteroids are often prescribed intermittently for short-term reactive treatment of acute flares and supplemented by emollients. Reactive treatment with corticosteroids offers rapid and effective symptomatic relief for acute flares. However, there are considerable safety concerns associated with their use, particularly when they are applied continuously. Potential adverse events are primarily cutaneous (principally skin atrophy, but also telangiectasia, hypopigmentation, steroid acne, increased hair growth and rosacea-like eruptions), but there may be systemic effects (suppression of the hypothalamic-pituitary-adrenal (HPA) axis, growth retardation, increased risk of glaucoma cataract and Cushing's syndrome).[16–20] These safety concerns have led to restrictions on the intensity and duration of topical corticosteroid use, especially in children and on delicate skin areas such as the face, neck and skin folds.

Topical corticosteroids may be a challenge to use. Patients or parents may be concerned about side-effects. The numerous products, and where to apply each specifically, may confuse patients. Generic products appear to patients to have different names, even though the active molecule is the same; patients may be guessing which product to use. The generic product may have different potency than the brand product when put into clinical use.

Other treatment options

A range of other treatment options is available for atopic dermatitis, including systemic corticosteroids or other pharmacological interventions such as cyclosporine[21] or azathioprine. These are generally reserved for severe cases that prove refractory to conventional treatment with topical agents. Long-term treatment with mycophenolate mofetil has also been successfully used in severe atopic dermatitis.[22]

Sedating antihistamines may be used for intense pruritus causing sleep disturbance. Physical therapies such as phototherapy and wet wraps are also employed in some instances. Intermittent use of topical and oral antibiotics can be helpful in cases where *S. aureus* overgrowth is prominent.[23] Appropriate counseling may be offered to patients in whom atopic dermatitis is exerting a pronounced psychological impact.

There is considerable dissatisfaction with existing standard pharmacological and physician interventions[14,24,25] and some patients explore 'alternative' therapies, such as Chinese herbal remedies, homeopathy or acupuncture, although there is limited evidence to evaluate their effectiveness.[26]

Avoidance of trigger factors

Atopic dermatitis can be provoked by a number of trigger factors. Among these are irritants (inappropriate clothing, water hardness, etc.), microbes (especially *Staphylococcus aureus*), psychological (especially stress situations) and allergic factors. Atopic dermatitis patients often have raised serum IgE levels and a high degree of sensitization to environmental allergens including foods. Indoor or outdoor pollutants such as tobacco smoke influence IgE production.[9] Up to one-third of children with atopic dermatitis may have a coexisting food allergy.[27] Trigger factors should if possible be identified and avoided. However, further research is needed to more clearly identify triggers as well as avoidance tactics. Allergological investigations rarely have therapeutic consequences in mild to moderate cases of atopic dermatitis.

Limitations of current treatment strategies

In many patients, the atopic dermatitis is poorly controlled. Topical corticosteroids are often reserved for flares that have become fully manifest. Lack of confidence in corticosteroid safety also adversely affects compliance and under-treatment of children with atopic dermatitis is common owing to physicians' and parents' concerns about the side-effects of corticosteroids.[24] Systemic treatment is associated with potentially severe adverse effects and is not recommended except as a last resort.[14] Phototherapy is inconvenient and may carry a risk of future skin cancers and/or photoageing. The immunosuppressants, including cyclosporine and azathioprine, require appropriate monitoring because of their potential effects on organ toxicity, increased risk of infection and possibly lymphoma and may interfere with immunization during childhood. There is also a need for controlled studies with allergen-specific immunotherapy, where some benefit has been shown in atopic dermatitis.

Therapeutic objectives for atopic dermatitis

In the absence of a cure, the therapeutic objectives for atopic dermatitis can be defined as follows:

- reduce signs and symptoms;
- prevent or reduce recurrences;

- provide long-term management by preventing exacerbation;
- modify the course of the disease.

Conventional therapies focus on the reactive treatment of relapses. There is a need for new safe and effective therapies for early control and long-term maintenance.

New developments: the role of new and emerging treatments

New and emerging therapies such as the topical calcineurin inhibitors, tacrolimus and pimecrolimus, not only complement existing treatment options but also overcome some of the drawbacks of topical steroid therapy and fulfil the long-term needs of patients in preventing disease progression. Their primary mechanism of action, which is distinct from topical corticosteroids, is to inhibit inflammatory cytokine transcription in activated T cells and other inflammatory cells through inhibition of calcineurin.[28,29]

Unlike many corticosteroids, these agents may be used on all body locations for extended periods. Their potencies are standard and there are no generic substitutes. Skin atrophy, glaucoma, and other local risks of corticosteroids do not occur, nor do the systemic side-effects such as HPA-axis suppression and growth retardation.

Pimecrolimus

Pimecrolimus exhibits high anti-inflammatory activity in models of skin inflammation,[28–30] but has only low activity in models of systemic immunosuppression.[30,31] Pimecrolimus 1% cream, specifically developed for the treatment of inflammatory skin diseases, has been shown to offer a safe and effective treatment option in a broad spectrum of atopic dermatitis patients, including infants,[32] children[33] and adults[34–36] with mild-to-severe disease even in highly sensitive skin areas.[37,38] More importantly (when used in the early stages) it has also been proven to have significant therapeutic advantages over conventional therapy (emollients plus topical corticosteroids) in the long-term management of atopic dermatitis.[39]

The results from short-term[37,40,41] and long-term[42] controlled clinical trials demonstrate its rapid and sustained effect in controlling pruritus, which is the primary complaint of patients with atopic dermatitis and is often the main indication for use of corticosteroids. In the controlled long-term study in adults[43] a significant effect ($P < 0{\cdot}001$), of pimecrolimus treatment on pruritus relief could be seen as early as Day 3 when compared to a conventional treatment. Relief from pruritus with pimecrolimus cream is also demonstrated across a diverse patient population in terms of age (> 3 months)[40] and severity of disease.[43] Pimecrolimus also provides significantly better long-term control of atopic dermatitis than a conventional treatment by preventing progression of disease to flare.[43–45] In large, controlled studies, significantly more patients in the pimecrolimus groups remained flare-free at 6 and 12 months when compared to a conventional-treatment group. For example, in the pimecrolimus group, 61% of patients remained flare-free during the first 6 months of the study in contrast to only 34% of patients treated conventionally ($P < 0{\cdot}001$).[44] The beneficial effect of pimecrolimus cream is also sustained over time with 51% of pimecrolimus patients vs. 28% in the conventional treatment group remaining flare-free at 12 months ($P < 0{\cdot}001$).[44] The ability of pimecrolimus to prevent flare progression also results in a significant steroid-sparing effect.[43–45] In a large study in infants, 64% of pimecrolimus patients required no steroids throughout the 12 months of the study, compared to 35% of those subjects treated conventionally.[45]

The potential for pimecrolimus to prevent flare progression and improve disease control is confirmed by a clear trend towards a significant reduction in use of pimecrolimus over time, which was seen in both large, long-term paediatric studies.[44,45]

Tacrolimus

Topical tacrolimus, an ointment formulation[46] of the oral systemic immunosuppressive agent used to prevent allotransplant rejection, has shown efficacy and safety for the treatment of atopic dermatitis in both short-term, double-blind[47] and long-term, open-label[48] clinical studies.

Tacrolimus ointment has a rapid and sustained effect on signs and symptoms of atopic dermatitis in adults[49] and children[50] with moderate-to-severe atopic dermatitis. In two long-term, open-label studies[48,49] an improvement was seen in all symptomatic parameters after 1 week of therapy. This improvement was maintained over 12 months.

The ability of tacrolimus ointment to clear atopic dermatitis was investigated in two short-term, vehicle controlled studies. In one study, 41% of patients treated with 0·1% tacrolimus ointment had ≥ 90% clearance

of disease at the end of the 12 weeks compared to only 7% in the vehicle treatment group ($P < 0{\cdot}001$).[49]

Two recent short-term (3-week) studies, in children (2–15 years)[51] and adults[52] with moderate-to-severe AD compared tacrolimus ointment (0·1% and 0·03%) and conventional treatment with a topical corticosteroid. In adults, tacrolimus was compared with a topical corticosteroid of mid-potency, hydrocortisone-17-butyrate ointment 0·1%. In children, the comparator was the low-potency hydrocortisone acetate ointment 0·1%. The results confirmed the efficacy of tacrolimus ointment compared to these topical corticosteroids and showed a quick onset of efficacy. In the study with children, there was a trend for the 0·1% tacrolimus to be more effective than 0·03% tacrolimus and for both formulations to be more effective than hydrocortisone acetate.[51] There were no serious safety concerns in either trial, with the only significant adverse event being transient skin burning and irritation.

This, together with the clinical data from pimecrolimus, reinforces the role of topical calcineurin inhibitors as maintenance therapy for atopic dermatitis with corticosteroids being reserved for acute control of disease progression.

Safety of the new treatments

Pre-clinical and clinical findings

When discussing safety of the new topical calcineurin inhibitors, two aspects have to be considered:

- potential systemic exposure due to percutaneous absorption;
- and local adverse events.

Percutaneous absorption of tacrolimus in healthy volunteers has been shown to be generally low.[53] Although in patients with atopic dermatitis, tacrolimus blood levels have been shown to be dose-dependent,[54] broadly related to the severity of the disease and degree of lichenification the majority had low tacrolimus blood levels and these have shown to decrease over time.[54–56]

Systemic blood levels of pimecrolimus have been shown to be consistently low and independent of duration of therapy (3 weeks to 1 year) and age of patients. There were no significant increases in systemic blood levels with increasing extent of body surface involvement (up to 92% TBSA).[57] As with tacrolimus, no long-term accumulation has been reported with pimecrolimus.[36,57] In the clinical trials both pimecrolimus and tacrolimus have shown no significant systemic toxicity.[43–45,55,56]

Skin atrophy, a local adverse event, long associated with topical corticosteroids, was not seen in any of the clinical trials with pimecrolimus or tacrolimus. In contrast to topical corticosteroids, tacrolimus and pimecrolimus have been shown to be also safe for application to particularly sensitive areas such as the face and neck.[56,57]

The most common important local-site reaction with topical tacrolimus and pimecrolimus is local discomfort associated with the application of the drug. In the tacrolimus clinical trials (with 0·03% ointment) up to 36% of paediatric patients[58–60] and up to 47% of adult patients[47,58] exposed to the study medication experienced a local burning sensation at time of application. Pimecrolimus cream 1% demonstrated a comparable level of application-site burning to conventional treatment with only 7·4% vs. 7·4%, respectively, reporting burning sensation in the long-term paediatric studies.[61] Also, in adult patients 10·4% of the pimecrolimus group experienced application-site burning compared to 3·1% in the conventional treatment group.[43] Application site burning is, however, transient and of short duration.

Given the mechanism of action, the possibility of local immunosuppression with topical tacrolimus and pimecrolimus is a potential concern. However, the risk of local bacterial infections is less in patients treated with topical calcineurin inhibitors than in patients on topical corticosteroids.[62] It is important to note that corticosteroids act on a broad spectrum of immune competent cells, including Langerhans' cells that have a key function in the local immunosurveillance. In clinical studies with pimecrolimus secondary skin infections occurred at similar rates as those patients treated with placebo.[45] With both compounds there is a decreased rate of skin infection over increasing length of use.[45,63]

With tacrolimus ointment in a 52-week photocarcinogenicity study, the median time to onset of skin tumour formation was decreased in hairless mice as compared to vehicle-treated animals, following chronic topical dosing with concurrent exposure to UV radiation (40 weeks of treatment followed by 12 weeks of observation) with tacrolimus ointment.[64] The risk of photocarcinogenicity is still undetermined in humans. In a similar study with pimecrolimus, there was a decrease in median time to onset, with vehicle cream alone, but this was unchanged with the addition of pimecrolimus.[65] It is nevertheless prudent for patients to minimize natural or artificial sunlight exposure whilst using the topical treatments.

In summary, the new topical calcineurin inhibitors seem to be extremely safe without many of the side-effects associated with conventional treatment for atopic dermatitis.

Treatment strategies/treatment guidelines

Algorithm

The treatment of atopic dermatitis must be based on an initial assessment of disease history, extent, and severity, including assessment of psychological distress and impact on the family (Fig. 1). The physician–patient communication is of utmost importance to secure compliance with treatment.

The initial treatment of atopic dermatitis consists of the liberal use of emollients for skin hydration. This should be coupled with education for both patients and caregivers on the avoidance of trigger factors.

Also, when the patient is already in flare, short-term use of topical corticosteroids is indicated to treat the acute disease. Topical calcineurin inhibitors are alternatives for acute control of pruritus and inflammation. Once the condition settles they can then revert to continuous use of emollients.

For maintenance therapy (in the case of persistent disease or frequent recurrences), topical calcineurin inhibitors can be used as well (Fig. 1). Pimecrolimus was used in clinical studies at the first sign or symptom of atopic dermatitis. It has been proven to prevent disease progression[43–45] and reduce the incidence of flares, with corticosteroids being reserved for acute exacerbations. Once the patient is back in remission emollients should be continued. It should be noted that the currently available data demonstrate that pimecrolimus can prevent flare progression. Tacrolimus studies have shown efficacy in long-term atopic eczema therapy,[47,48] but its effect on incidence of flares has not been studied.

Use as described above is possible because of the safety profile established in long-term trials of topical calcineurin inhibitors together with the proven ability of pimecrolimus to prevent progression of disease and improve disease control compared to conventional treatment (topical corticosteroids and emollients).[43–45] It also optimizes the role of corticosteroids, which are highly efficacious in treating acute exacerbations, whilst minimizing the risks by decreasing the time for which they are used.

Additional benefits of the treatment recommendations:

- it is easily communicated to patients;
- different areas of the skin can be treated in different ways depending on the activity of the condition;
- development of a clearly understood and effective treatment strategy should minimize the likelihood of patients seeking alternative and unproven therapies;
- this approach should help to standardize or harmonize the evaluation and treatment of the patient across clinical specialties;
- the treatment algorithm complements but extends current practice by allowing more individualization of treatment according to patient need.

Adjunctive therapy

In conjunction with drug treatment, adjunctive measures may also be necessary to maximize the outcome for individual patients. This may range from education on the avoidance of trigger factors to providing psychological support.

Infections can alter the course of the disease. In the event of patients developing either a bacterial, fungal or viral skin infection, the infection needs to be fully evaluated and appropriate antibiotic, antifungal or antiviral therapy should be initiated as soon as possible. Before commencing treatment with anti-inflammatory agents, clinical infections at treatment sites should be cleared.

Special emphasis should be put on treating reservoirs of the disease, i.e. nose and the groin, to prevent recurrence.

If the symptoms of atopic dermatitis are refractory and the condition cannot be brought under control by treatment with topical calcineurin inhibitors and intermittent use of corticosteroids, a range of options could be considered depending on the status of the individual patient. These include phototherapy, drug therapy with more potent topical or oral steroids, immunosuppressants such as cyclosporin, methotrexate or azathioprine alone or in combination with psychotherapeutic and psychopharmacological options.

In conclusion, there is a need for an effective and safe therapy for early control and long-term maintenance of atopic dermatitis, irrespective of the age of the patient. Topical corticosteroids have been the standard of therapy for many years and while their efficacy is not in question there are continuing concerns about their safety. The new class of topical calcineurin inhibitors may fulfil this unmet need by providing a safe and effective option for the long-term control of atopic dermatitis.

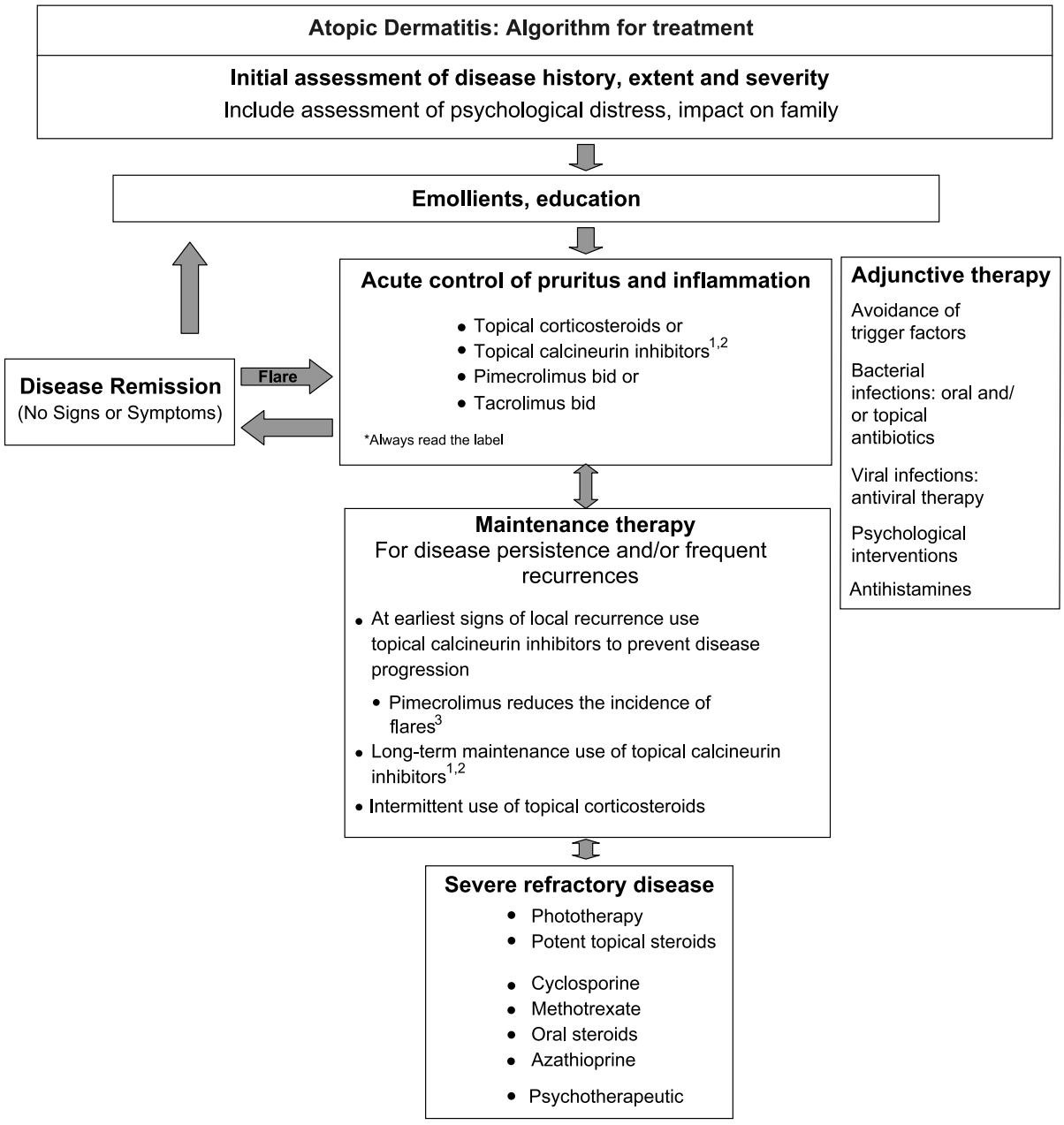

1. The evidence of the safety and efficacy of pimecrolimus was derived from studies primarily in patients with mild-to-moderate atopic dermatitis; tacrolimus data was derived from moderate-to-severe patients
2. Pimecrolimus has been studied in clinical trials in infants as young as 3 months, as compared with tacrolimus from 2 years
3. Clinical trial data[43–45] have proven that pimecrolimus reduces incidence of flares, these trials have not been performed for tacrolimus

Figure 1. Algorithm for treatment of atopic dermatitis.

These new treatments for atopic dermatitis are welcomed by patients, parents of patients, and physicians including dermatologists and paediatricians, as another treatment option for this demoralizing disease, and the first major advance in its management in half a century.

Faculty

Professor Charles Ellis, *Department of Dermatology, University of Michigan Medical Center, Ann Arbor, Michigan, U.S.A.*

Professor Thomas Luger, *Department of Dermatology, University of Münster, Münster, Germany*

Professor Dietrich Abeck, *Hospital and Health Centre for Dermatology and Allergology, Technical University of Munich, Munich, Germany*

Dr Roger Allen, *Queens Medical Centre, Department of Dermatology, Nottingham, U.K.*

Dr Robin Graham-Brown, *Department of Dermatology, Leicester Royal Infirmary, Leicester, U.K.*

Professor Yves de Prost, *Hospital Necker Enfants Malades, Service de Dermatologie, Paris, France*

Professor Lawrence F Eichenfield, *Chief of Pediatric & Adolescent Dermatology, University of California, San Diego School of Medicine, San Diego, U.S.A.*

Dr Carlos Ferrandiz, *Department of Dermatology, Hospital Universitario Germans Trias I Pujol, Barcelona, Spain*

Professor Alberto Giannetti, *Department of Dermatology, University of Dermatology, Modena, Italy*

Professor Jon M Hanifin, *Department of Dermatology, Oregon Health and Science University, Portland, U.S.A.*

Dr John Koo, *Department of Dermatology, Psoriasis Treatment Center, San Francisco, U.S.A.*

Dr Donald Leung, *Department of Pediatrics, National Jewish Medical and Research Center, Denver, U.S.A.*

Dr Charles Lynde, *Department of Dermatology, University of Toronto, Ontario, Canada*

Professor Johannes Ring, *Department of Dermatology and Allergology, Technical University of Munich, Munich, Germany*

Dr Ramon Ruiz-Maldonado, *Department of Pediatric Dermatology, National Institute of Pediatrics, Mexico*

Professor Jean-Hilaire Saurat, *Department of Dermatology, Hospital University of Geneva, Geneva, Switzerland*

References

1 Leung DYM. Atopic dermatitis: immunology and treatment with immune modulators. *Clin Exp Immunol* 1997; **107** (Suppl. 1): 25–30.
2 Emerson RM, Williams HC, Allen BR. Severity distribution of atopic dermatitis in the community and its relationship to secondary referral. *Br J Dermatol* 1998; **139**: 73–6.
3 Lewis-Jones MS, Finlay AY, Dykes PJ. The Infants' Dermatitis Quality of Life Index. *Br J Dermatol* 2001; **144**: 104–10.
4 Hanifin JM. Epidemiology of Atopic Dermatitis. *Immunol Allergy Clin NA* 2002; **22**: 1–24.
5 Su JC, Kemp AS, Varigos GA *et al.* Atopic eczema: its impact on the family and financial cost. *Arch Dis Child* 1997; **76**: 159–62.
6 Graham-Brown RAC. Atopic dermatitis: Predictions, expectations and outcomes. *J Am Acad Dermatol* 2001; **45**: 561–3.
7 Vickers CFH. The natural history of atopic eczema. *Acta Derm Venereol* (Suppl.)*(Stockh)* 1980; **92**: 13–5.
8 Bergmann RL, Edenharter G, Bergmann KE *et al.* Atopic Dermatitis in early infancy predicts allergic airway disease at 5 years. *Clin Exp Allergy* 1998; **28**: 965–70.
9 Leung DY, Soter NA. Cellular and immunologic mechanisms in atopic dermatitis. *J Am Acad Dermatol* 2001; **44** (Suppl. 1): S1–S12.
10 Brinkman L, Raaijmakers JA, Bruijnzeel-Koomen CA *et al.* Bronchial and skin reactivity in asthmatic patients with and without atopic dermatitis. *Eur Respir J* 1997; **10**: 1033–40.
11 Ring J, Brockow K, Abeck D. The therapeutic concept of 'patient management' in atopic eczema. *Allergy* 1995; **51**: 206–15.
12 Abeck D, Strom K. Optimal management of atopic dermatitis. *Am Clin Dermatol* 2000; **1**: 41–6.
13 Sidbury R, Hanifin JM. Old, new and emerging therapies for atopic dermatitis. *Dermatol Clinics* 2000; **18**: 1–11.
14 Sidbury R, Hanifin JM. Systemic therapy of atopic dermatitis. *Clin Exp Derm* 2000; **25**: 559–60.
15 Tofte SJ, Hanifin JM. Current management and therapy of atopic dermatitis. *J Am Acad Dermatol* 2001; **44**: S28–38.
16 Hill CJ, Rosenberg A Jr. Adverse effects from topical steroids. *Cutis* 1978; **21**: 624–8.
17 Ruiz-Maldonado R, Zapata G, Lourdes T, Robles C. Cushing's syndrome after topical application of corticosteroids. *Am J Dis Child* 1982; **136**: 274–5.
18 McLean CJ, Lobo RF, Brazier DJ. Cataracts glaucoma, and femoral avascular necrosis caused by topical corticosteroid ointment. *Lancet* 1995; **345**: 330.
19 Bode HH. Dwarfism following long-term topical corticosteroid therapy. *JAMA* 1980; **244**: 813–4.
20 Queille C, Pommarede R, Saurat JH. Efficacy versus systemic effects of six topical steroids in the treatment of atopic dermatitis of childhood. *Pediatr Dermatol* 1984; **1**: 246–53.
21 Granlund H, Erkko P, Sinisalo M *et al.* Cyclosporin in atopic dermatitis: time to relapse and effect of intermittent therapy. *Br J Dermatol* 1995; **132**: 106–12.
22 Benez A, Fierlbeck G. Successful long-term treatment of severe atopic dermatitis with mycophenolate mofetil. *Br J Dermatol* 2001; **144**: 638–9.
23 Abeck D, Mempel M. Staphylococcus aureus colonization in atopic dermatitis and its therapeutic implications. *Br J Dermatol* 1998; **139** (Suppl. 53): 13–6.
24 Charman C, Morris AD, Williams HC. Topical corticosteroid phobia in patients with atopic dermatitis. *Br J Dermatol* 2000; **142**: 931–6.
25 Hoare C. Li Wan Po A, Williams H. Systematic review of treatments for atopic dermatitis. *Health Technol Assess* 2000; **4**: 1–191.
26 Sheehan MP, Stevens H, Ostlere LS, Atherton DJ, Brostoff J, Rustin MH. Follow-up of adult patients with atopic eczema treated with Chinese herbal therapy for 1 year. *Clin Exp Dermatol* 1995; **20**: 136–40.
27 Eigenmann PA, Sicherer SH, Borkowski TA *et al.* Prevalence of IgE-mediated food allergy among children with atopic dermatitis. *Pediatrics* 1998; **101**: E8.
28 Grassberger M, Baumruker T, Enz A *et al.* A novel anti-inflammatory drug, SDZ ASM 981, for the treatment of skin diseases: *in vitro* pharmacology. *Br J Dermatol* 1999; **141**: 264–73.
29 Zuberbier T, Chong S. The ascomycin macrolactam pimecrolimus (Elidel, SDZ ASM 981) is a potent inhibitor of mediator release

from human dermal mast cells and peripheral blood basophils. *J Allergy Clin Immunol* 2001; **108**: 275–80.
30 Stuetz A, Grassberger M, Meingassner JG *et al.* Pimecrolimus (Elidel, SDZ ASM 981) preclinical pharmacologic profile and skin selectivity. *Sem Cutan Med Surg* 2001; **20**: 233–41.
31 Billich A, Aschauer H, Stuetz A. Pimecrolimus permeates less through the skin than corticosteroids and tacrolimus. *J Invest Dermatol* 2002; **119**: 346 (Abstract 831).
32 Kapp A, Bingham A, Fölster-Holst R *et al.* Pimecrolimus (Elidel®, SDZ ASM 981) cream 1%: a new approach to long-term management of atopic dermatitis in infants 3–23 months of age. *J Eur Acad Dermatol Venereol* 2001; **15** (Suppl. 2).
33 Harper J, Green A, Scott G *et al.* First experience of topical SDZ ASM 981 in children with atopic dermatitis. *Br J Dermatol* 2001; **143**: 1–8.
34 Van Leent EJM, Graeber M, Thurston M *et al.* Effectiveness of the ascomycin macrolactam SDZ ASM 981 in the topical treatment of atopic dermatitis. *Arch Dermatol* 1998; **134**: 805–9.
35 European Study Group Graeber M, Hedgecock S *et al.* SDZ ASM 981 cream: an emerging new drug for the treatment of atopic dermatitis. *J Eur Acad Dermatol Venereol* 1998; **11** (Suppl. 2): S198.
36 Van Leent EJM, Ebelin ME, Burtin P *et al.* Low systemic concentrations of SDZ ASM 981 after topical treatment of extensive atopic dermatitis lesions. *J Eur Acad Dermatol Venereol* 1998; **11** (Suppl. 2): 133–4.
37 Pariser D, Paller A, Langley R, Paul C. Efficacy and local tolerability of pimecrolimus cream 1% in the treatment of atopic dermatitis in the face/neck region of pediatric subjects. *J Invest Dermatol* 2002; **119**: 348 (Abstract 845).
38 Boguniewicz M, Eichenfield L, Honig P *et al.* Pimecrolimus (SDZ ASM 981) cream 1% is safe in the long-term management of atopic dermatitis. *J Eur Acad Dermatol Venereol* 2001; **15** (Suppl. 2): 110.
39 Kapp A, Bingham A, De Moor A *et al.* Pimecrolimus (Elidel, SDZ ASM 981) Cream 1%: a new approach to long-term management of atopic dermatitis in infants. *J Eur Acad Dermatol Venereol* 2001; **15** (Suppl. 2): 111.
40 Ho V, Halbert A, Takaoka R *et al.* Pimecrolimus (Elidel, SDZ ASM 981) Cream 1% is effective and safe in infants aged 3–23 months with atropic dermatitis. *J Pediat* 2003; **142**: 155–62.
41 Eichenfield LF, Lucky AW, Boguniewicz M *et al.* Safety and efficacy of pimecrolimus (ASM 981) cream 1% in the treatment of mild and moderate atopic dermatitis in children and adolescents. *J Am Acad Dermatol* 2002; **46**: 495–504.
42 Meurer M, Folster-Holst R, Wozel G *et al.* Pimecrolimus cream 1% (Elidel) provides significant and rapid relief of pruritus and improves disease control and quality of life in atopic dermatitis in adults. *J Invest Dermatol* 2002; **119**: 350 (Abstract 855).
43 Meurer M, Folster Holst R, Wozel G *et al.* Efficacy and safety of pimecrolimus cream in the long-term management of atopic dermatitis in adults: a six-month study. *Dermatology* 2002; **205**: 271–7.
44 Wahn U, Bos JD, Goodfield M *et al.* Efficacy and Safety of Pimecrolimus Cream in the Long-Term Management of Atopic Dermatitis in Children. *Pediatrics* 2002; **110**: e1.
45 Kapp A, Papp K, Bingham A *et al.* Long-term management of atopic dermatitis in infants with topical pimecrolimus, a nonsteroid anti-inflammatory drug. *J Allergy Clin Immunol* 2002; **110**: 277–84.
46 Nakagawa H, Etoh T, Ishibashi Y *et al.* Tacrolimus ointment for atopic dermatitis. *Lancet* 1994; **344** (8926): 883.
47 Ruzicka T, Bieber T, Schöpf E *et al.* A short-term trial of tacrolimus ointment for atopic dermatitis. *N Engl J Med* 1997; **337**: 816–21.
48 Kang S, Lucky AW, Pariser D *et al.* Long-term safety and efficacy of tacrolimus ointment for the treatment of atopic dermatitis in children. *J Am Acad Dermatol* 2001; **44** (Suppl. 1): S58–64.
49 Reitamo S, Wollenberg A, Schöpf E *et al.* Safety and efficacy of 1 year of tacrolimus ointment monotherapy in adults with atopic dermatitis. *Arch Dermatol* 2000; **136**: 999–1006.
50 Paller AS. Use of nonsteroidal topical immunomodulators for the treatment of atopic eczema in the pediatric population. *J Pediatr* 2001; **138**: 163–8.
51 Reitamo S, Van Leent EJ, Ho V *et al.* Efficacy and safety of tacrolimus ointment compared with that of hydrocortisone acetate ointment in children with atopic dermatitis. *J Allergy Clin Immunol* 2002, March; **109**: 539–46.
52 Reitamo S, Rustin M, Ruzicka T *et al.* Efficacy and safety of tacrolimus ointment compared with that of hydrocortisone butyrate ointment in adult patients with atopic dermatitis. *J Allergy Clin Immunol* 2002; **109**: 547–55.
53 Alaiti S, Kang S, Fiedler VC *et al.* Tacrolimus (FK506) ointment for atopic dermatitis: a phase I study in adults and children. *J Am Acad Dermatol* 1998; **38**: 69–76.
54 Kawashima M, Nakagawa H, Ohtsuki M, Tamaki K, Ishibashi Y. Tacrolimus concentrations in blood during topical treatment of atopic dermatitis. *Lancet* 1996; **348** (9036): 1240–1.
55 Hanifin JM, Ling MR, Langley R *et al.* A 12–week study of tacrolimus ointment for the treatment of atopic dermatitis in adult patients. *J Am Acad Dermatol* 2001; **44** (Suppl.): S28–S38.
56 Soter NA, Fleischer AB, Webster GF *et al.* Tacrolimus ointment for the treatment of atopic dermatitis in adult patients: Part II safety. *J Am Acad Dermatol* 2001; **44** (Suppl. 1): S39–S46.
57 Harper J, Lakhanpaul M, Wahn U *et al.* Pimecrolimus (Elidel®, SDZ ASM 981) cream 1% blood levels are consistently low in children with extensive atopic eczema. *J Dermatol Venereol* 2001; **15** (Suppl. 2): S109.
58 Reitamo S, Rissanen J, Remitz A *et al.* Tacrolimus ointment does not affect collagen synthesis: results of a single-center randomized trial. *J Invest Dermatol* 1998; **111**: 396–8.
59 Boguniewicz M, Fiedler VC, Raimer S *et al.* A randomised, vehicle-controlled trial of tacrolimus ointment for treatment of atopic dermatitis in children. *J Allergy Clin Immunol* 1998; **102**: 637–44.
60 Paller A, Eichenfield LF, Leung D *et al.* A 12 week study of tacrolimus ointment for the treatment of atopic dermatitis in pediatric patients. *J Am Acad Dermatol* 2001; **44** (Suppl. 1): S47–S57.
61 Hanifin J, Ho V, Kaufmann R *et al.* Pimecrolimus (SDZ ASM 981) cream: Good tolerability in paediatric patients. *Ann Dermatol Venereol* 2002; **129**: 1S411.
62 Robinson N, Singri P, Gordon KB. Safety of the new macrolide immunomodulators. *Semin Cutan Med Surg* 2001; **20**: 242–9.
63 Fleischer AB Jr, Ling M, Eichenfield L *et al.* Tacrolimus ointment for the treatment of atopic dermatitis is not associated with an increase in cutaneous infections. *J Am Acad Dermatol* 2002; **47**: 562–70.
64 Protopic PI. Fujisawa Pharmaceuticals Corp, December, 2000.
65 Elidel PI. Novartis Pharmaceuticals Inc, December, 2001.