P06.039

Two Cases of Early Onset Sporadic Creutzfeldt-Jakob Disease in Michigan

Amanda C. Peltier, *Manuela Pastore, Patience Reading, Karen Kluin, Sharin Sakurai, Ahmad Beydoun, Jonathan Edwards, *Pierluigi Gambetti and Norman L. Foster
University of Michigan, Ann Arbor, MI USA and *Case Western Reserve University, Cleveland, OH, USA

BACKGROUND

◗ Sporadic CJD typically occurs in men and women from 50-70 years of age; the incidence under age 30 is unknown

◗ CJD before age 30 is usually familial, new variant (associated with bovine spongiform encephalopathy), or a result of exposure to contaminated human growth factor or dural grafts

◗ MRI is typically abnormal, with increased signal in the basal ganglia and cerebral cortex on FLAIR, T2 and diffusion-weighted images, in a distribution that correlates with symptoms

◗ Molecular variants of sporadic CJD are based upon electophoretic mobility of the prion protein and methionine / valine polymorphism at codon 129 of the prion protein gene

◗ The MM2 variant is further divided into those with a cortical (C) or thalamic (T) clinical phenotype

FEATURES IN MOLECULAR VARIANTS OF SPORADIC CJD

(n=300)

	MM1	MV1	VV1	MM2-C	MM2-T	MV2	VV2
Prevalence (%)	67	3	1	2	2	9	16
Average age at onset (yrs)	65.5	62.1	39.3	64.3	52.3	59.4	61.3
Age range (yrs)	42-91	51-72	24-49	49-77	36-71	40-81	41-80
Average disease duration (mos)	3.9	4.9	15.3	15.7	15.6	17.1	6.5
Symptoms during course of illness							
Cognitive (%)	94	75	100	100	100	100	100
Aphasia (%)	36	25	100	83	0	26	0
Seizures (%)	19	12	0	33	0	11	2
Parkinsonism (%)	7	0	33	33	17	22	6
Psychiatric symptoms (%)	34	0	0	0	67	15	15

(From Parchi et. al. Ann Neurol 1999; 46:224 233)

METHODS

◗ We reviewed the medical and family history, examination, brain imaging and clinical course in two men concurrently hospitalized at our institution with rapidly progressive dementia.

◗ Brain biopsy tissue was examined by light microscopy with standard histological stains.

◗ The presence and type of abnormal prion protein was evaluated by immunoblot analysis on frozen brain biopsy tissue.

◗ The prion protein genotype was established in Case 2 sequencing the coding frame of the prion protein gene.

MRI

Case 1

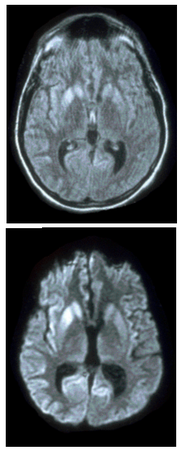

Case 2

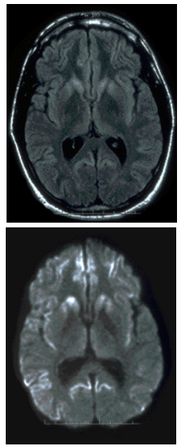

MR images from Case 1 (left) and Case 2 (right).

On the top row are transaxial FLAIR images at the level of the basal ganglia. There is increased signal in the caudate and putamen, with asymmetry in Case 1, where signal intensity is greater on the left than the right. On the lower row are diffusion-weighted images at the same level, where signal abnormalities are more striking. Localized areas of increased signal in the cerebral cortex are also apparent, involving almost the entire left hemisphere in Case 1 and affects circumscribed regions of both hemispheres in Case 2.

HISTOPATHOLOGY & WESTERN BLOTS

Case 1

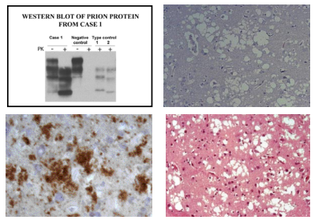

Case 2

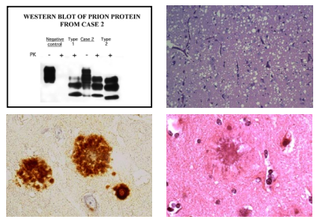

Western blots and histopathology from biopsy and autopsy are shown. On the top left are Western blots with samples from each case, negative control, type 1 and type 2 controls. On the top right are low power H&E stained sections of right frontal cortex from biopsy. On the lower row are immunostains for prion protein (bottom left) and high power H&E stains of the same section of autopsy tissue.

Case 1 immunoblot demonstrates presence of abnormal type 2 scrapie prion protein. Histopathology from right frontal biopsy demonstrates exuberant, confluent vacuolar changes. High power H&E stain of temporal cortex from case 1 demonstrates the coarse type of vacuolar changes with prominent gliosis in the cerebral cortex, typical of sporadic Creutzfeldt-Jakob disease 129 M/M, prion protein type 2. Immunostaining of this section confirms the presence of prion protein.

Case 2 immunoblot demonstrates presence of abnormal type 1 scrapie prion protein. Histopathology from the right frontal biopsy shows typical vacuolar changes. High power H&E stain section of hippocampus from case 2 show plaques in the hippocampal formation with no neurofibrillary tangles which is not present on the biopsy section. Immunostaining of this section for prion protein confirms the widespread presence of prion plaques and plaque-like formations and demonstrates extensive "synaptic" prion immunostaining of the cerebral cortex.

RESULTS

◗ Two young men concurrently hospitalized at our institution

◗ Both had a 3-6 month history of rapidly progressive dementia at the time of evaluation

◗ They were unrelated, both lived in Michigan, and had no known risk factors for CJD

◗ Neither had a family history of neurological disease, visited Great Britain or eaten elk or venison

Case 1

Progressive Aphasia and Nonconvulsive Status

◗ Onset at age 26 of progressive non-fluent aphasia, social withdrawal and memory difficulties

◗ Normal strength, tone and gait, no myoclonus

◗ Nonconvulsive status progressing to convulsive status, refractory to anticonvulsants

◗ The patient was started empirically on chloroquine and thorazine with no improvement

◗ EEG: Diffuse, waxing and waning rhythmic spike and wave discharges predominantly over the left hemisphere and evolving to continuous bihemispheric epileptiform discharges

◗ CSF protein 14-3-3: not done

◗ Disease duration 6 months

◗ Prion protein genotype: codon 129 M/M; no mutations found

Case 2

Behavior changes and Rigidity

◗ Onset at age 28 of uncharacteristic mood swings and progressive irritability

◗ Progressive catatonia and rigidity, stooped and shuffling gait

◗ Myoclonus late in disease course

◗ EEG: nonspecific, moderate generalized slowing

◗ CSF protein 14-3-3: negative

◗ Disease duration 14 months

◗ Prion protein genotype: not done

CONCLUSIONS

◗ CJD always should be considered in rapidly progressive neurological decline of unknown etiology, even in persons under age 30.

◗ Both brain biopsy and autopsy with genetic and prion analysis should be performed in all such cases.

◗ Young patients with CJD often may have unexpected presentations.

◗ EEG and CSF protein 14-3-3-3 results are not to exclude CJD in younger patients.

◗ MRI may help suggest the diagnosis of CJD in suspicious cases.

◗ The concurrent development of CJD in two unrelated young men in a single state suggests that sporadic CJD may be more prevalent than previously realized.

ACKNOWLEDGEMENTS

This study was supported by NIH grant AG14359 and CDC grant CCU 515004 to the National Prion Disease Surveillance Center, and the Michigan Alzheimers Disease Research Center (NIH grant P50-AG0871).