Preliminary Experience in Transducer Preparation for Intraoral Periodontal Imaging

Oliver D. Kripfgans, PhD[1,2], and Hsun-Liang Chan, DDS, MS[3]

1. Department of Radiology, University of Michigan School of Medicine, Ann Arbor, MI, USA
2. Department of Biomedical Engineering, University of Michigan, Ann Arbor, MI, USA
3. Department of Periodontics and Oral Medicine, University of Michigan School of Dentistry, Ann Arbor, MI, USA.

Corresponding author:

Oliver Kripfgans, PhD

Department of Radiology

University of Michigan, Medical School, Ann Arbor, MI, USA

1301 Catherine St., Ann Arbor, MI 48109-2026

TEL: (734) 647-0852

E-mail address: oliver.kripfgans@umich.edu

Word count: 3673

Tables and figures: 5 tables and 5 figures

Running title: US Probe Preparation Protocol

Disclosure: The authors do not have any financial interests, either directly or indirectly, in the products or information listed in the paper.

Author Manuscript

This is the author manuscript accepted for publication and has undergone full peer review but has not been through the copyediting, typesetting, pagination and proofreading process, which may lead to differences between this version and the Version of Record. Please cite this article as doi: 10.1002/jum.16224

This article is protected by copyright. All rights reserved.

Summary

Intraoral scanning must meet a stringent infection control standard because of contact with the oral mucosa. A preparation protocol is thus presented for increased inquiries about intraoral scanning requirements. Materials required for such a preparation include: a single-use bubble-free gel packet, a gel standoff pad, and a transducer probe cover. Post-scan reprocessing of the ultrasound transducer requires high-level disinfection. Examples for proper and improper use are provided as well as limitations of this preparation protocol and recommendations for future development. This guidance meets the current infection control standard and may guide the user to obtain consistent ultrasound image quality.

Key Words: Ultrasonography, Instrumentation, Standard Operating Procedure

Author Manuscript

Introduction

Ultrasonic diagnostic imaging in the oral cavity dates back to the 1960s.[1] Technological limitations in the past, e.g., probe size and image resolution, limited the use of this useful imaging modality for routine patient care. This is about to change. Recent technology advances, e.g., miniaturization of the ultrasound probe and increased ultrasound image quality for small parts and superficial structure imaging shed light on its routine use in the dental field.[2] At least one current ultrasound system on the market can already allow for intraoral imaging of facial and palatal/lingual sites even at the molar sites (ZS3, Zonare/Mindray, San Jose, CA, USA). The same system has a high-frequency probe (30 MHz, L30-8), contributing to 25.4-μm image pixel resolution. These advances have made it a viable method to provide static as well as functional information that could assist dentists to make critical decisions. Static information that can be acquired includes but not limited to periodontal[2-4] and peri-implant[5, 6] soft tissue and hard tissue surface visualization and quantification, and spatial relationships of important anatomical structures.[3, 7-9] Functional information indeed sets apart ultrasound from radiographs, such as blood flow changes after periodontal plastic surgeries[4] and blood infusion in peri-implantitis classification and diagnosis.[5, 6]

Acquiring oral tissue images with ultrasound can be performed through the intraoral or extraoral means. The placement of the ultrasonic probe directly within the mouth is advantageous, compared to extraoral imaging for the following reasons. Imaging signals can be maximally preserved, i.e., non-attenuated, by directly going into periodontal tissues, reflecting after encountering hard tissue structures back to the probe. In cases of extraoral scanning, sound waves deteriorate when going through the buccal tissues twice, i.e., on transmit and on receive. This intraoral approach also adds flexibility and accuracy to spatial placement of the probe. The clinician can place the probe at specific sites, e.g., the mid-facial, mesial, or distal sites of a given tooth or implant. Intraoral scans can further acquire palatal/lingual tissues images, which can't be obtained by extraoral scans. By placing the probe immediately next to the object of interest, the clinicians can know and record the site where the image is acquired with ease. On the contrary, remote scanning introduces ambiguity in knowing where the scan was performed for the obvious reason.

Author Manuscript

Although intraoral scans are favored, more sophisticated preparatory steps are required first to comply with infection control requirements and second to ensure the acquisition of high-quality images. According to the American Institute of Ultrasound in Medicine (AIUM) guideline, scanning directly in the oral cavity, i.e. on mucosal tissue, requires the use of a mechanical barrier to be applied between the ultrasound transducer and biological tissues.[10] Post-scan reprocessing of the ultrasound transducer requires high-level disinfection, whereas transcutaneous scanning only requires low-level disinfection.[10] To meet the increased inquiries about intraoral ultrasound scanning for research and patient-care purposes, there is an imminent need to publish a probe preparation protocol that can be readily accessible for protecting the general public from potential cross-infections and to produce consistent images with diagnostic values. The readers of this preparation protocol should have basic knowledge of ultrasonic imaging to understand the rationale behind the provided methods and their implications for imaging. Interested readers may refer to[11-20] for such information. To full disclosure, the products shown in this document are not exclusively recommended nor endorsed by the authors. They are merely examples for the purpose of illustrating particular steps in preparing an in-situ ultrasound imaging probe for use in the oral cavity. Other products exist and may be considered. The following transducer preparation example is a result of our preliminary first experience with using ultrasound intra orally and may be found useful to those that have a dentistry background but are new to the use of ultrasound.

Author Manuscript

Materials and Methods

Scanning gel

Ultrasonic scanning requires utmost attention to the use of scanning gel. Sound propagation relies on a physical path from the transducer to inside the human body without any presence of air pockets. Even microscopic layers of air in the sound path greatly impede such propagation. Placing a transducer onto dry skin almost certainly leaves a layer of air. The purpose of scanning gel is to wet the transducer surface, the aperture, as well as the skin and provide a continuous aqueous path. Improper application of scanning gel may result in inclusion of air pockets that will interfere with sound propagation. Traditional transcutaneous scanning techniques allow for removal of such air pockets by gently applying pressure to the transducer and thus the skin surface, by which trapped air is squeezed out. This method, however, requires a continuous surface to push against, such as intact skin. In dental applications one cannot rely on a continuous surface since oral cavity hard and soft tissue surfaces exhibit significant curvatures and crevices. Scanning gel must therefore be applied between the transducer and the mucosa, without any entrapped air pockets. A bubble-free scanning gel is therefore recommended. Commonly scanning gels may contain bubbles due to the production and distribution process on the manufacturing side. While traditional contact scanning, as mentioned above, allows for removal of these bubbles/air pockets, dental scanning requires the use of bubble-free gel. A web search using the terms "single-use ultrasound gel sterile" yielded several products, listed in Table 1. Clinical scanning of mucosal tissues requires single use gel containers (7), whereas pre-clinical scans may allow for multi-use dispensers. For oral mucosal scans we recommend sterile gel. Single-use non-sterile gels may be bacterio-static, and thus contain a bacteriostatic agent. Users should contact the manufacturer to check if oral use is permitted with any given gel.

Transducer probe covers

General transcutaneous, intact-skin scanning does not require the use of probe covers.[10] Contact with mucosal tissues, however, does require a mechanical barrier to prevent cross-contamination between patients. Probe covers consist of a thin latex or latex-free material that is engineered to allow for low-interference sound propagation. Probe covers are available as sterile and non-sterile, and their use should be according to the

Author Manuscript

sterility level of the procedure at hand (Table 2). Intact mucosal skin should in general be a non-sterile procedure, whereas a surgical incision or other situations with a non-intact mucosal skin should lead to use of a sterile probe cover. They act as viral barriers and exhibit pore sizes as low as 27 μm. Probe covers are for single use. When using a probe cover, scanning gel needs to be applied twice. Once inside the cover, to allow for an aqueous path from the transducer into the probe cover material, and also on the outside of the probe cover, for an aqueous path from the probe cover material into the subject tissue. For that matter, pre-gelled products are available as well as gel-free solutions.

Gel standoff pad

Ultrasound transducers facilitate a lens for beam focusing, similar to optical systems. Medical ultrasound transducers are designed for specific applications and their lenses accommodate the specific need at hand. For example, an abdominal ultrasound transducer is designed to focus beams at a larger distance than a peripheral vascular ultrasound transducer. Dental soft tissue imaging applications would require focusing to very superficial regions of interest, similar to dermatological and inter-operative applications.[13, 15, 19] The latter two often benefit from the use of a standoff gel pad (Table 3). The rationale is that available transducers might be able to focus their beams to a distance of 2 cm from the transducer aperture, but the soft tissue in a region of interest is much closer to the skin surface. In such cases a solid gel pad is used as a stand-off, which increases the distance between the transducer and the skin. Typically, 2 cm thick pads are available (such as Parker Laboratories, Aquaflex® Ultrasound Gel Pad, or Civco Ultrasound Gel Acoustic Standoff Pads).

Transducer re-processing

The re-processing starts with transducer cleaning[10] to remove any visible contaminants, including ultrasound gel, any adhesives (see below), or other surface bound remnants, followed by high-level disinfection. Cleaning can be performed using room temperature water in conjunction with mild hand dishwashing soap. However, any additives that might be present in medical soaps should not be used. Low level disinfecting wipes (such as CaviWipes, Metrex Research, Orange, CA 92867 USA, or Sani-Cloth, Professional Disposables International, Woodcliff Lake, NJ 07677, USA) are also suitable for performing cleaning, but only use those approved by the

Author Manuscript

manufacturer (Table 4). In addition, the user must inspect the transducer regarding any visible damage. Housing cracks and surface crevices do not only provide pointers to damage that might impact transducer performance, but also allow for bacteria or viruses to survive cleaning and disinfection efforts.

Use of ultrasound on non-intact skin, such as mucosa and gingiva, requires high-level disinfection, according to the guidelines of the American Institute of Ultrasound in Medicine.[10] Several solutions are currently available (Table 5). Some systems may require laboratory ventilation environments, while others can operate in office-type environments. Examples include ASTRA VR (Civco, Coralville, Iowa 52241, USA), as well as Trophon (HQ Nanosonics Limited, Lane Cove NSW 2066, Australia). If the manufacturer provides guidelines for cleaning and disinfection, they should be followed. Contact the manufacturer or representative about any deviations regarding cleaning and disinfection, as these could damage the transducer or present harm to the patient.

After re-processing the transducer needs to be stored in a single use bag before next use. Examples include General Purpose Probe Transport & Storage Bag, Civco, or Ultrasound Probe Storage Bags, Cone Instruments, Caledonia, MI 49316, USA). Storage bag sterility should follow the sterility level of the next procedure. If no sterile storage bags are available, use a sterile probe cover, and replace it immediately prior to the procedure.

Results

Step by step preparation

Probe preparation is illustrated in Figure 1 in a step-by-step fashion, using the materials outlined in the Materials and Methods section. It should be noted that this probe preparation protocol is the current practice performed in our laboratory that complies with the guidelines. This may be modified for more efficient preparation, better imaging results or other reasons.

The procedure starts with a bare probe as shown in panel (1). Using the above-mentioned standoff gel pad needs to be customized for scanning *in situ* in the mouth. For this purpose, we cut a larger gel pad (Table 3) into a rectangular block with a size that is slightly larger than the dimension of the probe and approximately 5

Author Manuscript

mm thick. It is to fit onto the aperture of our linear array transducer as shown in (2) (model L30-8, Mindray North America, Mahwah, NJ 07430, USA). To secure the gel pad, a bracket is created from medical adhesive tape (for example HyTape ½", Hy-Tape® International, Patterson, NY 12563-0540, USA), by folding it ⅓ onto itself and wrapping the remaining ⅓ with exposed adhesive around the aperture (3). The prepared tape is then wrapped around the transducer housing such that the exposed adhesive only touches the housing but not the aperture (4).

The gel block can now be placed within the bracket and will not slide off the aperture during probe placement *in situ* (5). However, the bracket needs to be pre-filled with a small amount of scanning gel (Table 1) to replace any air pockets within the bracket (6). It is also possible to 3D print a bracket to hold the gel block. An example is also shown in panel (6). Medical adhesive tape can also be used to fasten the shown bracket to the transducer housing. Another layer of a small amount of gel is applied on the surface of the gel pad. Then the probe cover can be set in place and secured (7). At first the cover will be secured immediately next to the aperture; tight enough to prevent the gel block to dislodge, but without too much tension, as to not pull on the gel block (8). Visually looking through the cover into the gel block, one should see no air pockets (9). Two more cover fasteners are placed, one immediately distal to the probe, where the cable is exposed (10) and at the end of the probe cover (11).

Standoff – Elevational focusing

Ultrasound transducers are manufactured for specific clinical applications and exhibit therefore a specific range for the axial, lateral and elevational field of view. The elevational focus of a 1D linear array is given by its corresponding lens and thus fixed. Therefore, the operator needs to hold the probe such that the tissue region of interest is located at the elevational focus. Figure 2 illustrates the effect of elevational focusing on the B-mode echogenicity, for a range of distances between the aperture and a gingiva mimicking tissue phantom. Each B-mode image is cropped and translated to offset the indicated distances from the aperture. Three aspects are of interest. First, the maximum echogenicity of the outermost epithelium, i.e., the hyperechoic part of the epithelium. Second, the minimum echogenicity of the innermost epithelium, i.e., the hypoechoic part of the epithelium. Third, the subsequent connective tissue mimicking part of the gingiva. All three parts become less

Author Manuscript

echoic as the transducer aperture is approaching the phantom. A significant drop occurs at approximately 6 to 7 mm. For less than 6 mm the connective tissue echogenicity fades to being anechoic. Above 6 mm all three regions, the outer most epithelium, the inner most epithelium, and the connective tissue, are constant within approximately 10 dB, 15 dB, and 10 dB, respectively. It is therefore important to position the transducer, for given specifications, at sufficient distance from the region of interest. The operator should consult the manual for each transducer's intended scanning distances.

Clutter artifacts

Improper probe preparation can lead to a variety of artifacts.[6, 21] Image cutter is an artifact that appears as false image content. Panel (a) in Figure 3 shows the B-mode image from a prepared transducer with only the gel pad and probe cover in place. In panel (b) an image clutter artifact can be seen. In the left image half, the probe cover echo is preceded by an echo that might arise from an air pocket within the gel pad bracket. Such an air pocket would be visible in Figure 1 panel (9). The right side also exhibits an echo earlier than that of the probe cover and it may arise from an air inclusion as well. Alternatively, the elevational or lateral edge of the gel pad bracket might be invading the field of view of the transducer and thereby generating the shown artifacts. Panel (c) also shows an early echo. The left-hand side shows a hyperechoic spot approximately 2 mm from the aperture. In addition, the entire left-hand edge of the field of view is impacted, suggesting a strong acoustic reflector, such as an air inclusion, or potentially the aforementioned hyperechoic spot.

Free gel and trapped air artifacts

Scanning oral mucosa or gingiva requires the operator to avoid exerting any pressure of the aperture onto the soft tissue during the scan. This is facilitated by carrying free ultrasound scanning gel between the ultrasound probe and the soft tissue as illustrated in panel (a) of Figure 4. Both the solid and free gel appear hypo-echoic in B-mode images. Ideally one would place free gel between the solid gel pad and all tissues. For scans reaching to the far apical sites that might be difficult to impossible. However, it is necessary to have free gel towards the site of interest. In panel (a) that would be the coronal gingiva. The necessary layer thickness of the free gel is debatable, but to avoid speculation one should err on the side of a thicker layer. This is especially

Author Manuscript

true given the variable tissue surface curvature in the mouth. It is possible that the image shows a free gel layer, while the probe (i.e., the gel pad of the probe) touches adjacent tissues. The probability of that decreases as the free gel layer thickness increases.

Free gel is convenient as it can accommodate the nooks and crevices at and around the teeth. Moreover, it also minimizes the before mentioned force from the probe onto the soft tissue. While these abilities seem to make it superior to a solid gel, free gel comes with the disadvantage of allowing for air bubbles to be trapped in it. These bubbles can be introduced during its production as mentioned above, or they can be introduced when placing the gel onto the transducer or onto the oral tissue. One needs therefore to recognize any trapped air and remove it. Panels (b) and (c) show additional examples of trapped air bubbles between the regions of interest and the transducer. Several bubbles are trapped between the gel pad and the gingiva. No visible tissue shadowing can be observed. In panel (c), however, an apically trapped bubble casts a significant shadow onto the mucosal tissue. The major limitation of trapped air is the change in the acoustic field. Even small inclusions alter the field as they strongly reflect the transmit field and also hinder the return from the distal tissue. While in some cases the effects of shadowing are obvious, in others they might not be, but could influence a subsequent quantitative soft tissue analysis. The user should therefore remove any trapped bubbles.

Worn stand-off gel block

The gel stand-off block may degrade throughout the scanning session and may require replacement. Figure 5 provides examples of overall and lateral damage. Degradation may correlate with scanning of difficult to reach oral locations such as molars as well as tight cheek soft tissue, both of which can result in at least temporary mechanical pressure on the block. It is therefore advisable to monitor the condition of the gel block to avoid the scenarios shown.

Discussion

Ultrasound is facilitated in a wide range of applications. Abdominal, peripheral vascular and musculoskeletal scan may not require any specific preparation such as a probe cover, single use gel, removal of trapped bubbles or, post scan, high-level disinfection. On the contrary, percutaneous procedures such as needle guidance, or

Author Manuscript

endocavitary scans do require a single use sheath. In addition, mucosal tissue or intraoperative scans require high-level disinfection. The latter also requires sterility for gel and probe cover. Intraoral scans are no exception, scans of the intact mucosa allow for single use gel and sheath. Sterility is not required. Scans after surgical alteration of the mucosa require sterile gel and a sterile sheath. Additional preparation consumes extra resources. The following discussion points are some key points to consider in intraoral scanning and for future development.

Probe preparation

Current probe preparation is cumbersome and should be simplified while retaining the associated benefits, such as a solid gel standoff and a mechanical barrier/sheath. Possible solutions include pregelled probe covers, but with a finite solid gel standoff, that is currently not available. The gel pad should be mechanically secured to the transducer to prevent it from slipping off the aperture.

Pressure on soft tissue

One of the indications for intraoral scanning is to evaluate soft tissue quality and thickness. Therefore, imaging soft tissue surfaces becomes very important, which requires a thin layer of gel in between the probe cover and the soft tissue. Without this separation between the probe cover and the mucosal surfaces, on B-mode images the hyperechoic lines indicative of the probe cover and mucosal surfaces coincide, making interpretation of the mucosal surfaces very difficult, if not possible. In addition, when evaluating blood perfusion, pressure on soft tissue will collapse superficial and small blood vessels, reducing the velocity as well as the power flow readings.

Free gel

Free gel serves multiple purposes in the application of intraoral scanning applications. It reduces the mechanical pressure exerted from the ultrasound transducer onto the soft tissue. In addition, it allows the user to remove air from the scanning path, especially from the uneven surface morphology of the interdental space as well as the transitions between soft and hard tissues. For such the gel viscosity must be low enough to accommodate surface undulations and high enough to stay on the transducer while placing it onto the site of

Author Manuscript

interest. The gel must of course also be bubble free. For surface scanning where the transducer can be firmly placed onto the skin, contained bubbles can be pushed away from the scan path. In intraoral applications it may be difficult to impossible to remove bubbles in situ. Any observed bubbles may only be removed by removing the transducer, wiping it as well as the imaging site and replacing it with freshly dispensed gel.

Current limitations

The currently used methodology was presented and found to be adequate for obtaining quality ultrasound images. However, it is still a cumbersome and time-consuming preparation process (approximately 5 min for each probe preparation) that will benefit from innovation. Manufacturers are called-upon to provide ultrasound supplies that are specifically tailored to dental applications, to save resources and improve workflow. Pre-gelled sheaths suitable for dental applications would be such an innovation and should be explored.

High-level disinfection is currently also a slow process and studies are necessary to determine if alternatives are available and warranted. They should target the evaluation of high-level versus low-level disinfection as well as faster disinfection, regardless of the level of disinfection. Ultrasound on mucous tissues currently requires high-level disinfection. This requirement is contradicted by the use of standard exam gloves and low-level handwashing of dental care providers. Thus, a uniform agreement of disinfection is needed.

To the best of the author's knowledge, only one manufacturer provides a 510(k) ultrasound array-based imaging system with color flow capabilities at 20-30 MHz, specifically addressing dental applications. A recent market analysis, however, has found numerous manufacturers that have the potential to also provide similar devices.[22] It is expected that increasing use of high-frequency ultrasound will draw the attention of the manufacturers and provide incentives for making ultrasound transducers available with appropriate physical geometries and spatial resolution tailored to dental use.

Author Manuscript

Conclusions

Proper ultrasound probe preparation and scanning techniques are crucial for intraoral scanning. Standardized practice guidelines and specialized training will be very beneficial for novice users to become accustomed to this new imaging technology in periodontal and potentially other specializations of dentistry.

Acknowledgements

The study was supported by grants from the National Institute of Dental and Craniofacial Research (NIDCR) (1-R21DE027765-01A1, 1-R21DE029005-01A1, 1-R56DE030872-01, and 3-R21DE029005-02S1), National Center for Advancing Translational Sciences of the National Institutes of Health Award (UL1TR000433), Delta Dental Foundation (AWD010089 and AWD004687), American Academy of Periodontology Sunstar Innovation Award (AWD007224). Clinical images shown were approved under HUM00170906 and HUM00203875.

Author Manuscript

Tables

Table 1. Overview table of sterile, single-use ultrasound gel packs, alphabetically sorted by brand name. No products are endorsed nor recommended. A web search was conducted for "single-use ultrasound gel sterile". This listing is not meant to be representative nor exhaustive. The listed products might or not include the products the authors use.

Brand name: EcoVue Ultrasound Gel

Manufacturer: EcoVue

URL: https://ecovue.com/products/ultrasound-gel/single-use/



Brand name: Sterile Ultrasound Gel

Manufacturer: HR Pharmaceutical

URL: https://hrpharma.com



Brand name: Krystal Sterile Ultrasound Gel

Manufacturer: EDM medical solutions

URL: https://us.edm-imaging.com/product/krystal-sterile-ultrasound-gel/



Brand name: Clear Image Singles® Gel Packets (sterile)

Manufacturer: NEXT Medical Products

URL: https://nextmedicalproducts.com/clear-image-singles-gel/#sterile



Brand name: Vue ultrasound gel

Manufacturer: Optimum medical

URL: https://nextmedicalproducts.com/clear-image-singles-gel/#sterile



Brand name: Aquasonic 100 – Sterile

Manufacturer: Parker Laboratories

URL: https://aquasonicgel.com/aquasonic-100-sterile-overwrapped-foil-pouches-48-per-box



Author Manuscript

Table 2. Overview table of transducer probe covers for ultrasonic imaging on non-intact skin such as in the mouth. No products are endorsed nor recommended. A web search was conducted for "single-use ultrasound gel sterile". This listing is not meant to be representative nor exhaustive. Always ask your ultrasound transducer representative for probe cover guidelines and consult your manufacturer instructions for use. The listed products might or not include the products the authors use.

Brand name: Transducer Probe Covers (latex) Manufacturer: DynaRex URL: https://dynarex.com/transducer-probe-covers.html	
Brand name: Endocavity Latex-free Ultrasound Cover Manufacturer: EDM medical solutions URL: https://us.edm-imaging.com/product/endocavity-latex-free-ultrasound-cover-flat-fold/	
Brand name: Sterile Ultrasound Probe Covers Manufacturer: Sheathing Technologies Inc URL: https://www.medline.com/jump/product/x/Z05-PF43628	
Brand name: Endocavity Probe Cover, Non-Sterile Manufacturer: Cone Instruments URL: https://www.coneinstruments.com/catalog/Ultrasound-Probe-Covers/Sterile-Ultrasound-Probe-Covers/Endocavity-Probe-Covers-914614	
Brand name: Intuit Ultrasound Probe Covers Manufacturer: CIVCO Medical Solutions URL: https://www.civco.com/catalog/ultrasound-probe-covers/intuit-ultrasound-probe-covers/	
Brand name: Ultrasound Probe Covers Manufacturer: Mckesson URL: https://mms.mckesson.com/product/1001865/McKesson-Brand-16-1004	

Author Manuscript

Table 3. Overview table of transducer probe covers for ultrasonic imaging on non-intact skin such as in the mouth. No products are endorsed nor recommended. A web search was conducted for "single-use ultrasound gel sterile". This listing is not meant to be representative nor exhaustive. The listed products might or not include the products the authors use.

Brand name: Aquaflex® Ultrasound Gel Pad Manufacturer: Parker Laboratories URL: https://www.parkerlabs.com/products/aquaflex-ultrasound-gel-pad	
Brand name: Envision™ Ultrasound Probe Covers & Scanning Pads Manufacturer: CIVCO Medical Solutions URL: https://www.civco.com/catalog/ultrasound-probe-covers/envision	
Brand name: Reusable Acoustic Standoff Pads Manufacturer: AliMed, Inc. URL: https://www.alimed.com/reusable-acoustic-standoff-pad.html	

Author Manuscript

Table 4. Overview table of transducer probe low-level disinfection methods. No products are endorsed nor recommended. A web search was conducted for "low-level disinfection ultrasound probes". This listing is not meant to be representative nor exhaustive. Always ask your ultrasound transducer representative for cleaning and disinfection guidelines and consult your manufacturer instructions for use. The listed products might or not include the products the authors use.

Brand name: CaviWipes Manufacturer: Metrex Research, LLC URL: https://www.metrex.com/en-eu/caviwipes	
Brand name: Sani-Cloth AF3 Manufacturer: PDI Healthcare URL: https://pdihc.com/products/environment-of-care/sani-cloth-af3-germicidal-disposable-wipe	
Brand name: Protex Disinfectant Wipe Manufacturer: Parker Laboratories URL: https://www.parkerlabs.com/products/protex-ultra-disinfectant-wipes	

Author Manuscript

Table 5. Overview table of transducer probe high-level disinfection methods. No products are endorsed nor recommended. A web search was conducted for "high-level disinfection ultrasound probes". This listing is not meant to be representative nor exhaustive. Always ask your ultrasound transducer representative for cleaning and disinfection guidelines and consult your manufacturer instructions for use. The listed products might or not include the products the authors use.

Brand name: MetriCide 28 Manufacturer: Metrex Research, LLC URL: https://www.metrex.com/en-us/metricide-28	
Brand name: Astra VR Manufacturer: CIVCO Medical Solutions URL: https://www.civco.com/products/probe-cleaning-disinfection/automated-probe-disinfection/	
Brand name: Rapicide OPA/28 Manufacturer: Crosstex International, Inc. URL: https://www.crosstex.com/rapicidetm-opa28-high-level-disinfectant-47	
Brand name: Trophon EPR Manufacturer: Nanosonics URL: https://www.nanosonics.us/products/trophon-epr	

Author Manuscript

Figures



Figure 1. Step-by-step process of ultrasound imaging probe (panel 1) preparation, including the placement and securing of a gel standoff block to allow for superficial imaging (panels 2 to 6), single use probe cover placement and securing to reduce infection risk (panels 7 to 11). A description is provided in the main text.

Author Manuscript

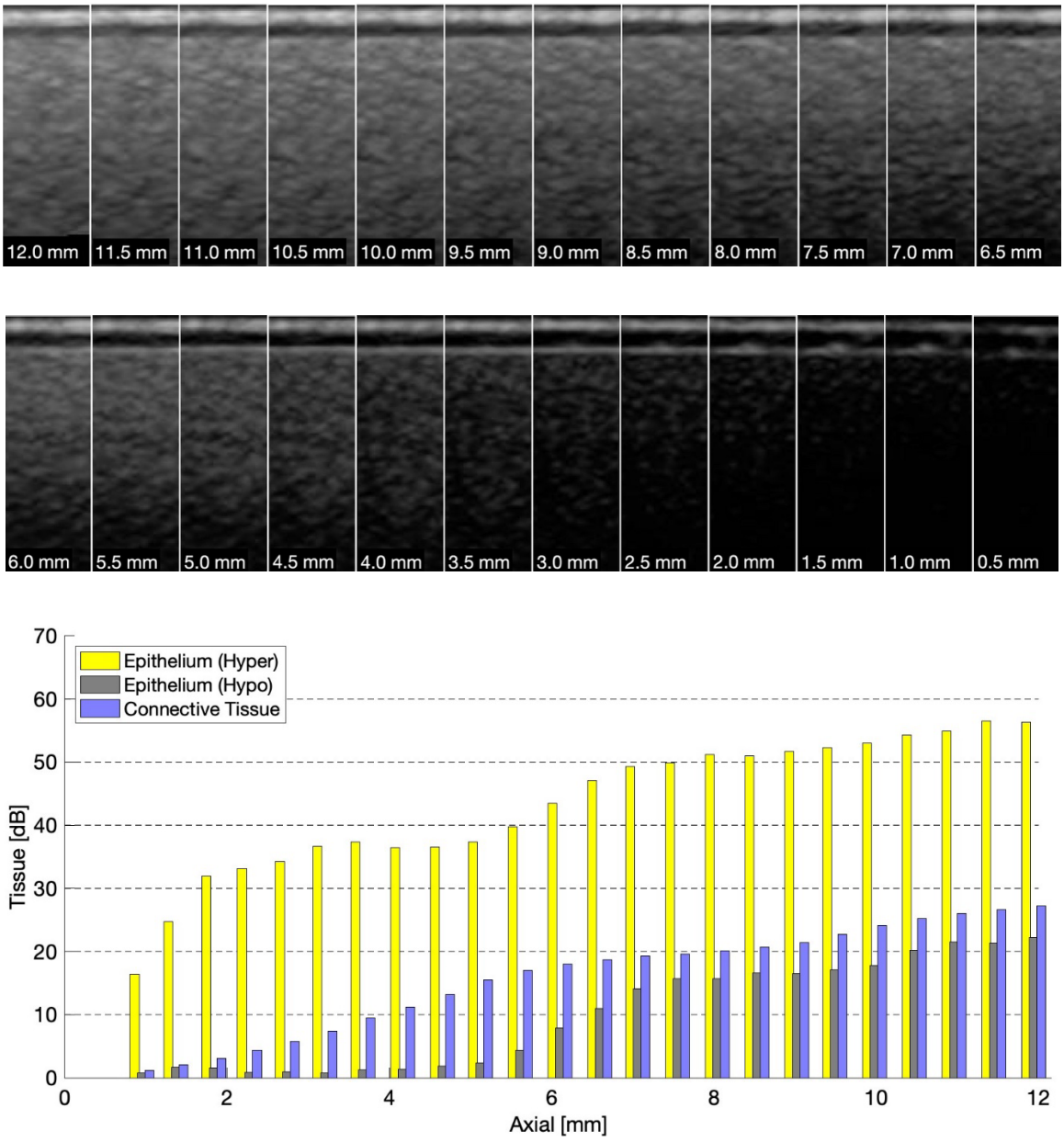

Figure 2. Top: B-mode image at varying distance from a gingiva mimicking tissue phantom. The elevational transducer focus is at nominally 8 mm. In each image the epithelium (0.2 mm thick) is seen hyperechoic, followed by a hypoechoic gap (~0.2 mm wide) before the connective tissue starts. Bottom: Average tissue echogenicity showing a linear drop of the connective tissue closer than 6 mm. Note: Each B-mode image segment is 1.2 mm wide and 3.7 mm tall.

Author Manuscript

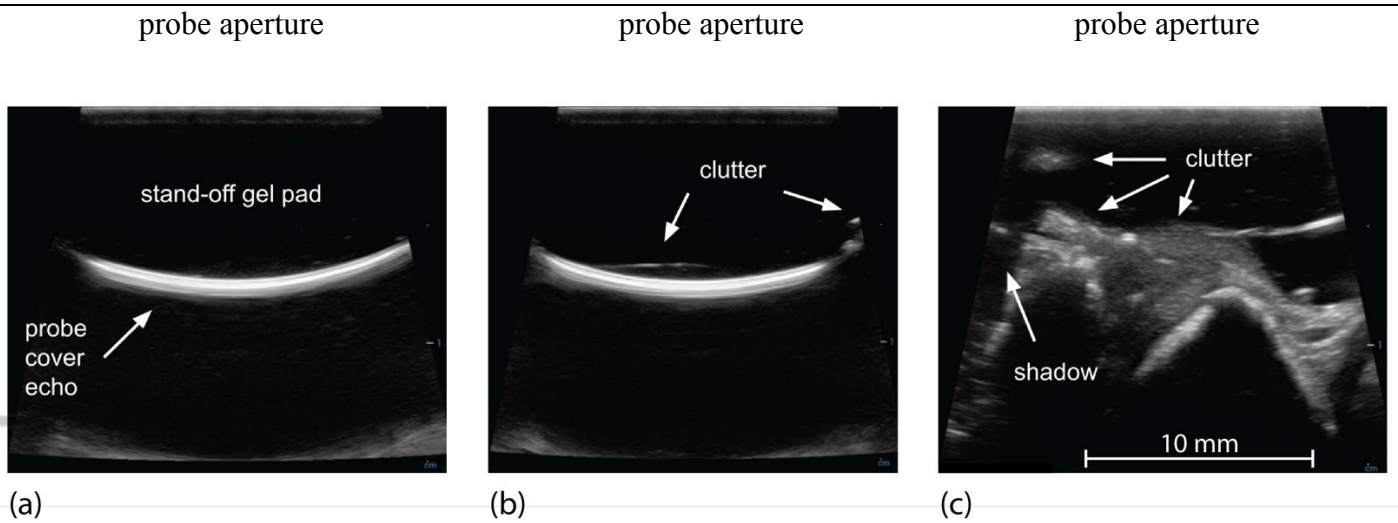

Figure 3. (a) Transducer probe with no clutter artifacts. (b) Transducer probe with slight elevational clutter artifacts. (c) Transducer probe with clutter and shadowing artifacts.

Author Manuscript

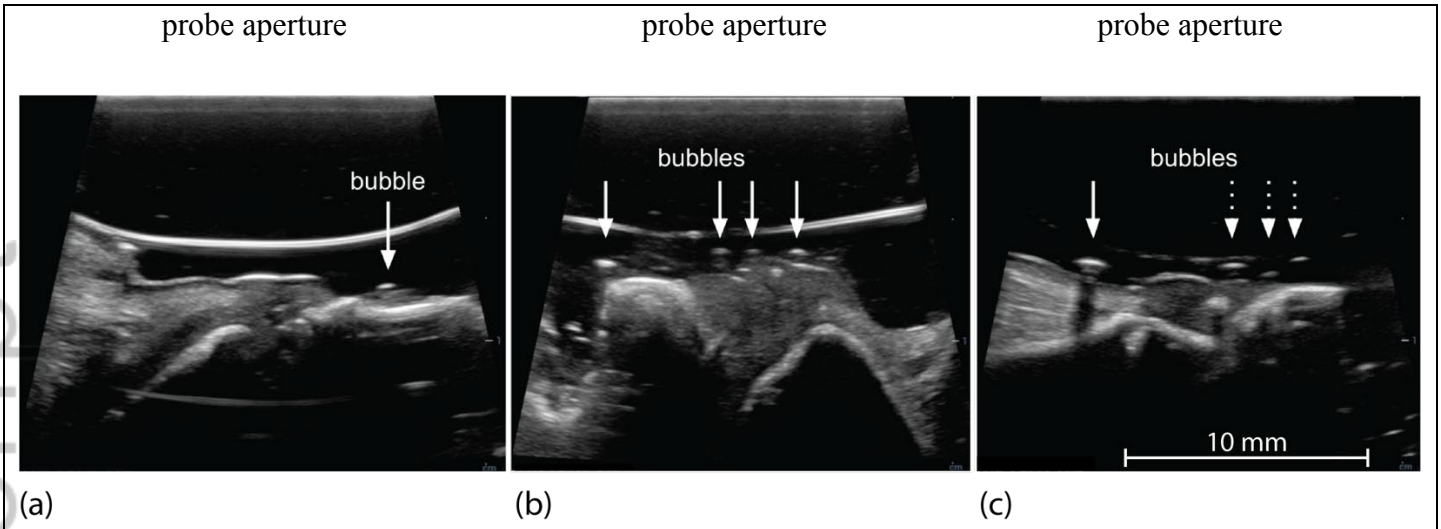

Figure 4. (a) Single air bubble on top of the crown but no bubbles in path of gingiva. (b) Several bubbles in the acoustic path to the gingiva, but no visible shadowing. (c) Significant shadowing of mucosal (apical) tissue caused by a trapped bubble (solid arrow). Less significant bubbles are indicated by the dotted arrows.

Author Manuscript

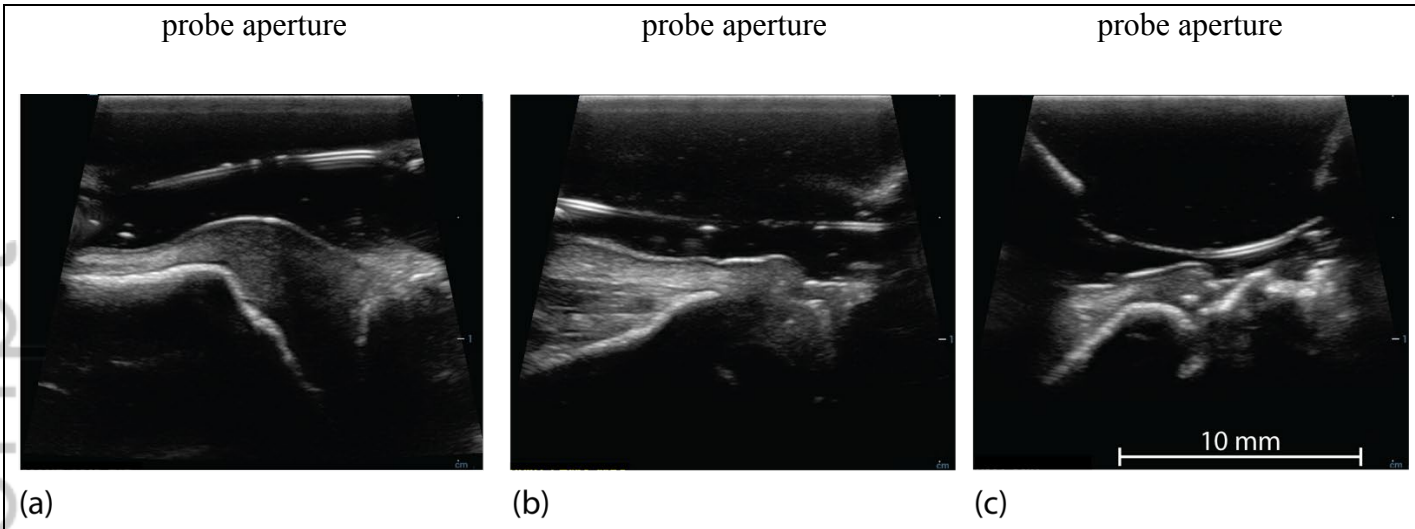

Figure 5. Repeated scanning using the same gel block may result in a visible degrade. (a) The gel block is significantly worn, thinned and uneven. In addition, the lateral edges are penetrating the field of view. (b) The gel block is moderately uneven and the right lateral side shows signs of degradation. (c) While the central part of the gel block is seemingly intact, both lateral edges are strongly compromised.

Author Manuscript

References

1. Ghorayeb, SR, CA Bertoncini, and MK Hinders, *Ultrasonography in dentistry.* IEEE transactions on ultrasonics, ferroelectrics, and frequency control, 2008. 55(6): p. 1256-1266.
2. Chan, HL, K Sinjab, J Li, Z Chen, HL Wang, and OD Kripfgans, *Ultrasonography for noninvasive and real-time evaluation of peri-implant tissue dimensions.* J Clin Periodontol, 2018. 45(8): p. 986-995.
3. Tattan, M, K Sinjab, E Lee, M Arnett, TJ Oh, HL Wang, HL Chan, and OD Kripfgans, *Ultrasonography for chairside evaluation of periodontal structures: A pilot study.* J Periodontol, 2020. 91(7): p. 890-899.
4. Tavelli, L, S Barootchi, J Majzoub, HL Chan, WV Giannobile, HL Wang, and OD Kripfgans, *Ultrasonographic tissue perfusion analysis at implant and palatal donor sites following soft tissue augmentation: A clinical pilot study.* J Clin Periodontol, 2021. 48(4): p. 602-614.
5. Barootchi, S, L Tavelli, J Majzoub, HL Chan, HL Wang, and OD Kripfgans, *Ultrasonographic Tissue Perfusion in Peri-implant Health and Disease.* J Dent Res, 2021: p. 220345211035684.
6. Chan, HL and OD Kripfgans, *Ultrasonography for diagnosis of peri-implant diseases and conditions: a detailed scanning protocol and case demonstration.* Dentomaxillofac Radiol, 2020. 49(7): p. 20190445.
7. Chan, HL, HL Wang, JB Fowlkes, WV Giannobile, and OD Kripfgans, *Non-ionizing real-time ultrasonography in implant and oral surgery: A feasibility study.* Clin Oral Implants Res, 2017. 28(3): p. 341-347.
8. Barootchi, S, HL Chan, SS Namazi, HL Wang, and OD Kripfgans, *Ultrasonographic characterization of lingual structures pertinent to oral, periodontal, and implant surgery.* Clin Oral Implants Res, 2020. 31(4): p. 352-359.
9. Sinjab, K, OD Kripfgans, A Ou, and HL Chan, *Ultrasonographic evaluation of edentulous crestal bone topography: A proof-of-principle retrospective study.* Oral Surg Oral Med Oral Pathol Oral Radiol, 2021.

Author Manuscript

10. AIUM. Guidelines for Cleaning and Preparing External- and Internal-Use Ultrasound Transducers and Equipment Between Patients as well as Safe Handling and Use of Ultrasound Coupling Gel 2020 [cited 2020. Available from: https://www.aium.org/officialStatements/57.

11. Kripfgans, OD and H-LA Chan, *Ultrasonic Imaging: Physics and Mechanism*, in *Dental Ultrasound in Periodontology and Implantology*. 2021, Springer. p. 1-38.

12. Azhari, H, *Basics of biomedical ultrasound for engineers*. 2010: John Wiley & Sons.

13. Kinsler, LE, AR Frey, AB Coppens, and JV Sanders, *Fundamentals of acoustics*. 2000: John wiley & sons.

14. Cobbold, RS, *Foundations of biomedical ultrasound*. 2006: Oxford university press.

15. Morse, PM and KU Ingard, *Theoretical acoustics*. 1986: Princeton university press.

16. Barnett, SB, GR Ter Haar, MC Ziskin, H-D Rott, FA Duck, and K Maeda, *International recommendations and guidelines for the safe use of diagnostic ultrasound in medicine.* Ultrasound in medicine & biology, 2000. 26(3): p. 355-366.

17. Barnett, S and D Maulik, *Guidelines and recommendations for safe use of Doppler ultrasound in perinatal applications.* Journal of Maternal-Fetal Medicine, 2001. 10(2): p. 75-84.

18. McGahan, JP and BB Goldberg, *Diagnostic ultrasound*. Vol. 1. 2008: Informa Health Care.

19. Szabo, TL, *Diagnostic ultrasound imaging: inside out*. 2004: Academic press.

20. Hoskins, PR, K Martin, and A Thrush, *Diagnostic ultrasound: physics and equipment*. 2019: CRC Press.

21. Saha, A and M Mathur, *Ultrasound Physics & Overview.* Ultrasound Fundamentals, 2021: p. 3-16.

22. Kripfgans, OD, *Dental Ultrasound in Periodontology and Implantology: Examination, Diagnosis and Treatment Outcome Evaluation*. 2020: Springer Nature.

Author Manuscript

Author Manuscript

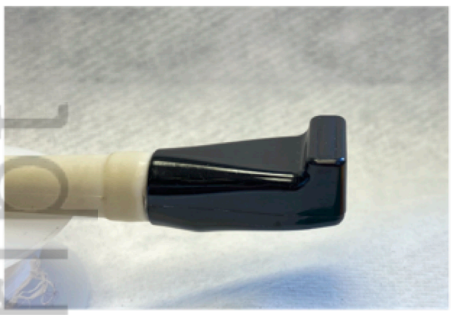

(1)



(2)



(3)



(4)



(5)



(6a) (6b)

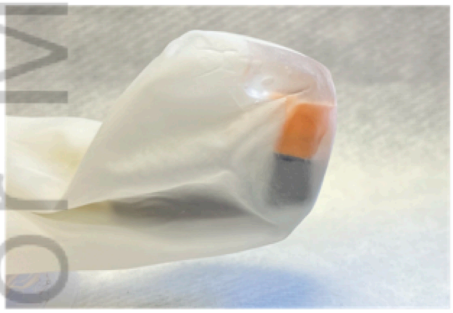

(7)



(8)



(9)



(10)



(11)

JUM_16224_Figure1.png

Author Manuscript

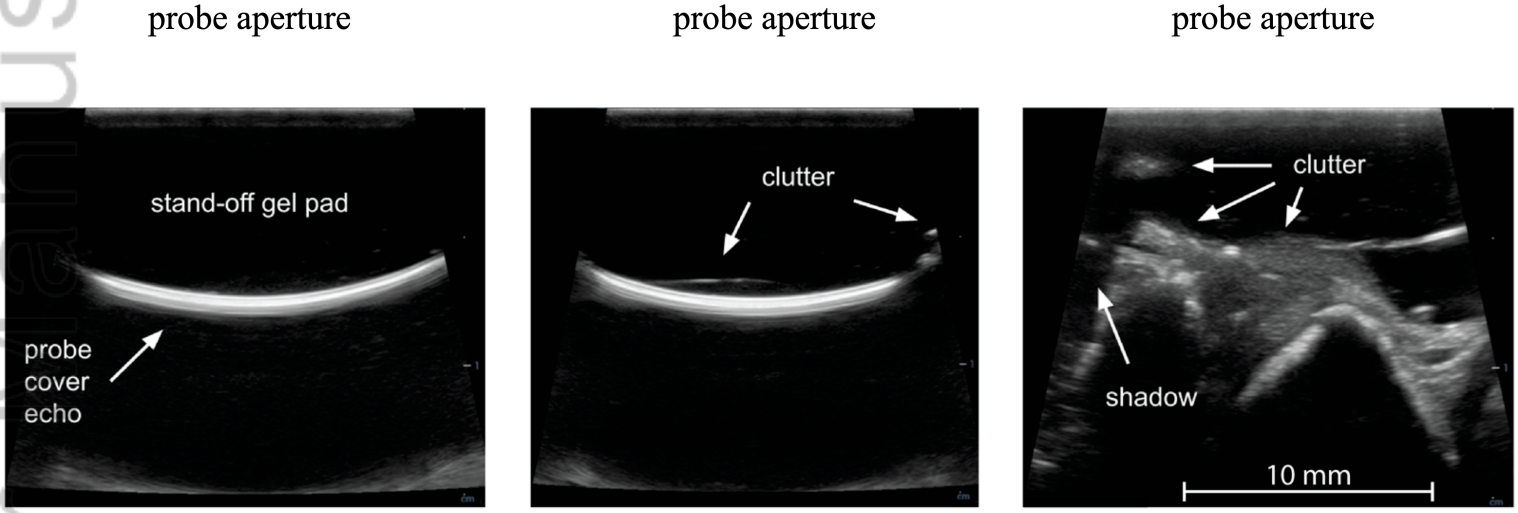

JUM_16224_Figure3.png

Author Manuscript

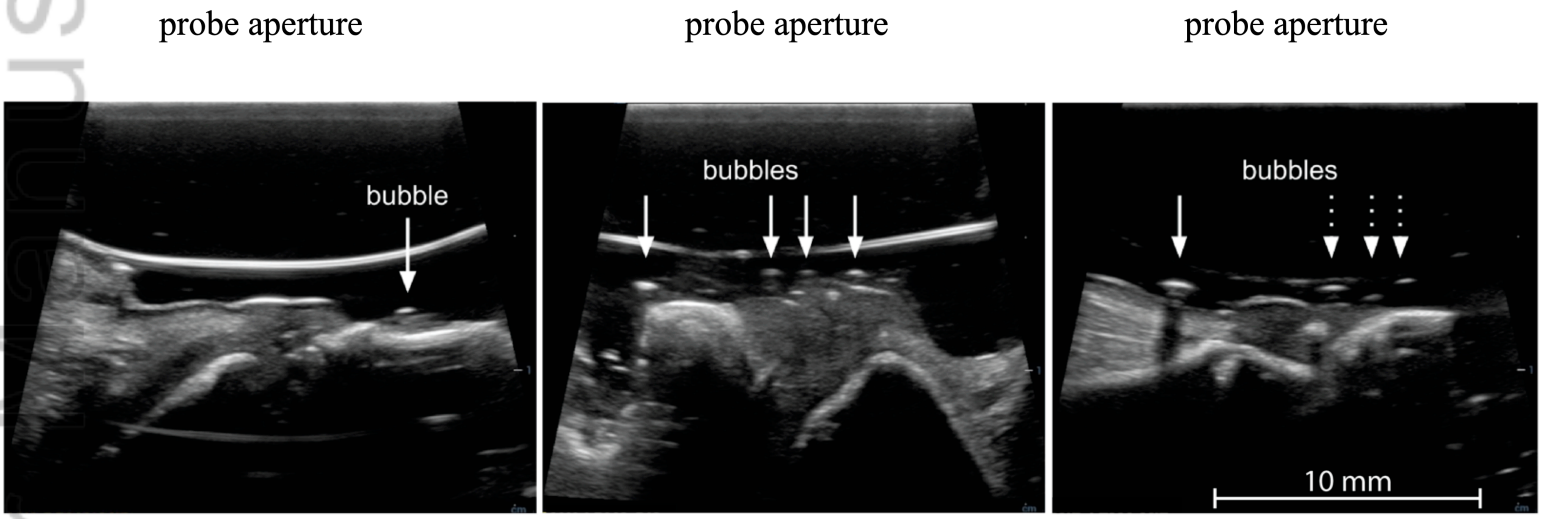

JUM_16224_Figure4.png

Author Manuscript

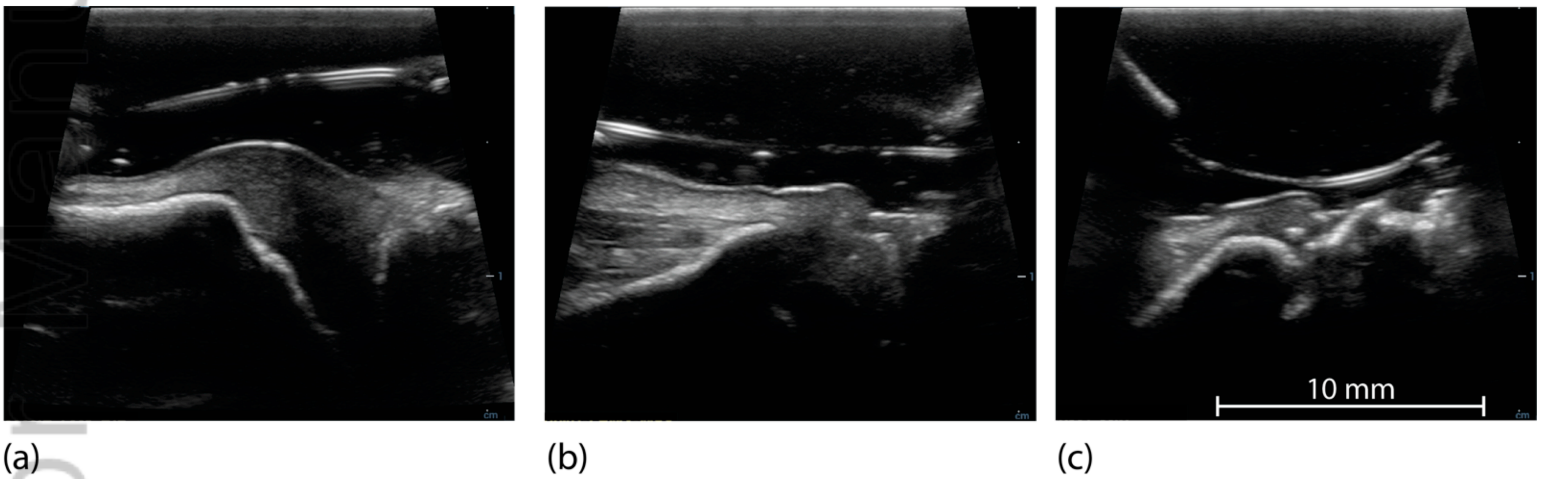

JUM_16224_Figure5.png

Author Manuscript

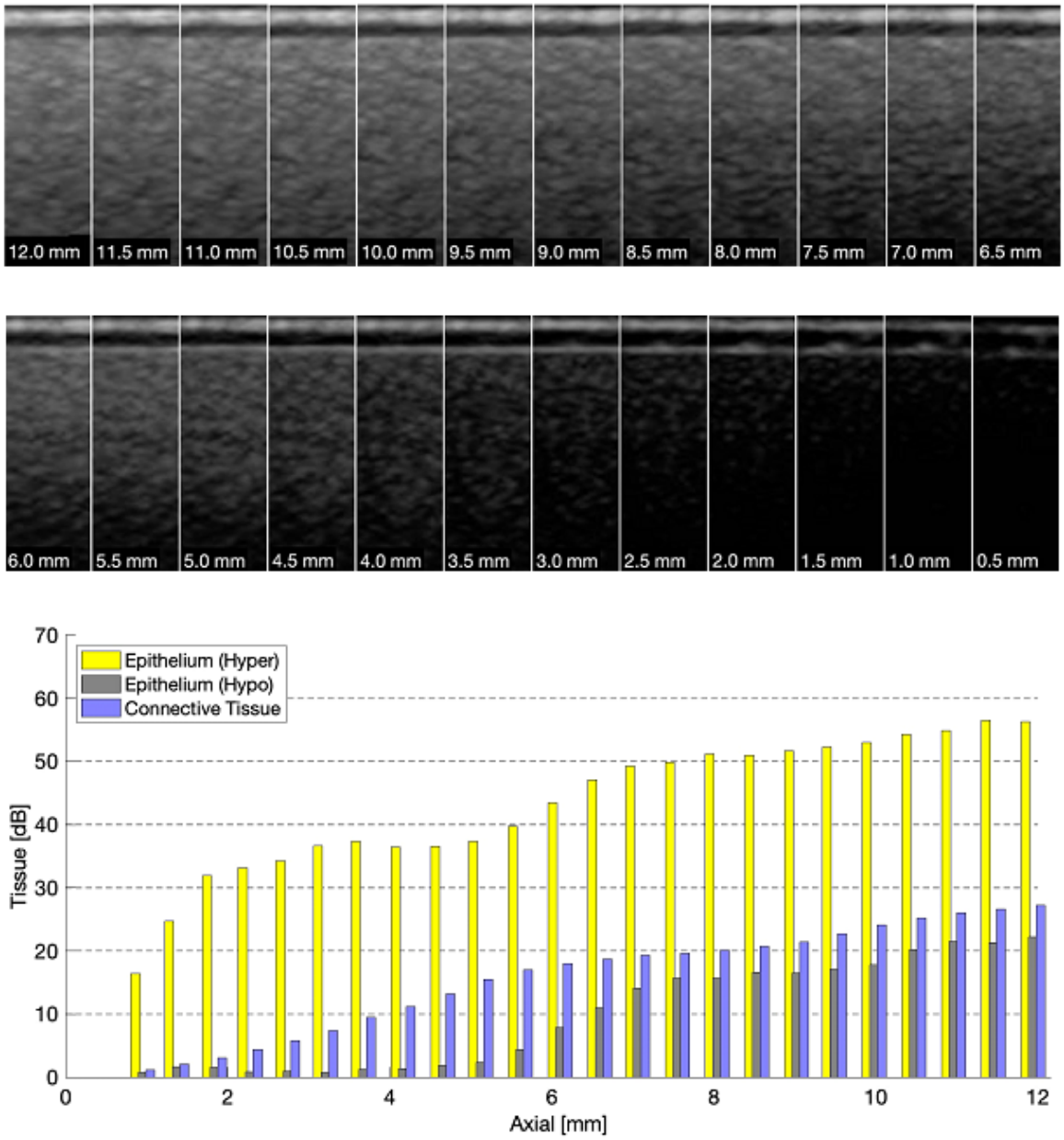

Figure 2. Top: B-mode image at varying distance from a gingiva mimicking tissue phantom. The elevational transducer focus is at nominally 8 mm. In each image the epithelium (0.2 mm thick) is seen hyperechoic, followed by a hypoechoic gap (~0.2 mm wide) before the connective tissue starts. Bottom: Average tissue echogenicity showing a linear drop of the connective tissue closer than 6 mm. Note: Each B-mode image segment is 1.2 mm wide and 3.7 mm tall.

JUM_16224_figure 2.png