DOCTORAL DISSERTATION SERIES

TITLE DIOCTOPHYMA RENALE (GOEZE, 1782)
A STUDY OF THE MIGRATION ROUTES TO THE KIDNEYS OF MAMMALS AND RESULTANT PATHOLOGY

AUTHOR CARL W. HALLBERG

UNIVERSITY OF MICH. DATE 1951

DEGREE Ph.D. PUBLICATION NO. 3507



UNIVERSITY MICROFILMS
ANN ARBOR · MICHIGAN

DIOCTOPHYMA RENALE (GOEZE, 1782)

A STUDY OF THE MIGRATION ROUTES TO THE KIDNEYS OF MAMMALS AND RESULTANT PATHOLOGY

by

Carl W. Hallberg

A dissertation submitted in partial fulfillment
of the requirements for the degree of
Doctor of Philosophy in the
University of Michigan
1951

Committee in Charge:

Associate Professor Arthur E. Woodhead, Chairman
Professor William H. Burt
Assistant Professor Norman E. Kemp
Associate Professor Karl F. Lagler
Professor Carl D. LaRue
Associate Professor Earl C. O'Roke
Dr. Frederick E. Smith
Dr. Erich E. Steiner

To Jane

Acknowledgements

To Dr. A. E. Woodhead, I wish to extend my heart-felt gratitude for his aid, inspiration and constructive criticism during the course of this investigation.

Acknowledgements are also extended to the other members of the committee and the many others who have aided my work in many ways and to my wife whose many self-sacrifices and encouragements have aided materially in the completion of this work.

Table of Contents

	Page
Acknowledgements	iii
Statement of the Problem	viii
Introduction	1
Historical Review	5
Methods and Procedures	12
Part I. Experimental Feedings of Infective Larvae of *D. renale* to Mammals	22
Case I. Ferret Number Two	22
Case II. Ferret Number One	23
Case III. Cat Number One	27
Case IV. Cat Number Two	28
Case V. Cat Number Three	30
Case VI. Cat Number Four	31
Part II. Studies of the Migration Route to the Right Kidneys by *D. renale* in Experimentally Infected Mammals	33
Case II. Ferret Number One	33
Plates I through V	38
Woodhead's Case I: The 30-mm Young Adult	51
Part III. Studies of the Migration Route to the Right Kidney in Natural Infections of Wild Mink Followed by the Pre-adult Larvae of *D. renale*	54
Part IV. Summary of Infections by *D. renale* in Animals Studied at the University of Michigan	67

Page

Discussion ---------- 70

Fish as the Second Intermediate Hosts of the Larvae of D. renale ---------- 71

Migration of Pre-adult Larvae of D. renale Through the Uro-genital System to the Right Kidney of Mammalian Hosts ---------- 74

Migration of Pre-adult Larvae of D. renale Through the Liver and Body Cavity to the Right Kidneys of the Mammalian Hosts --------- 75

Migration of Pre-adult Larvae of D. renale to the Right Kidneys of the Mammalian Hosts via the Blood Stream ---------- 80

Migration of the Infective Larvae of D. renale to the Right Kidneys of the Mammalian Hosts Directly from the Duodenum ---------- 80

Plate VI ---------- 86

D. renale Migrations in Dogs Versus Mink ----- 87

An Unusual Kidney Worm Migration in a Ferret - 88

Cytolysis in Migration ---------- 89

Immunity to D. renale ---------- 90

Why D. renale Migrate to the Kidney ---------- 90

Summary ---------- 91

Bibliography ---------- 93

Photographic Appendix ---------- 99

List of Tables

		Page
Table I.	Numbers of bullheads collected and number of *D. renale* larvae obtained from 1949 to 1951 ----------	16
Table II.	A list of the mink carcasses which were studied for *D. renale* infections and pathology ----------	56
Table III.	Summary of *D. renale* infections studied at the University of Michigan Department of Zoology ----------	69

List of Plates

		Page
Plate I.	Figures 1 through 6 ----------	40
Plate II.	Figures 1 through 10 ----------	42
Plate III.	Figures 11 through 20 ----------	44
Plate IV.	Figures 21 through 30 ----------	46
Plate V.	Figures 31 through 38 ----------	48
Plate VI.	Diagramatic sketch of the visceral anatomy of the Mustelidae showing the topographical relationships of the organs and the steps in the migration route of pre-adult larvae of *D. renale* to the right kidney ----------	86
Photographic Appendix Plates		
Plate Ia.	Autopsy Ferret No. I ----------	102
Plate IIa.	Autopsy Ferret No. I ----------	104
Plate IIIa.	Penetration of a wild mink kidney -----	106
Plate IVa.	Penetration of kidney and duodenum ----	108
Plate Va.	Escape path from duodenum ----------	110
Plate VIa.	Papilliferous metaplasia ----------	112
Plate VIIa.	Pathology of infected kidney ----------	114
Plate VIIIa.	Glomeruli ----------	116
Plate IXa.	Pathology of hypertrophied kidneys ----	118
Plate Xa.	Invasion of kidney ----------	120
Plate XIa.	Typical right kidney infection -------	122
Plate XIIa.	Adult kidney worm ----------	124

Statement of the Problem

The problem selected for investigation was a study of the migration route to the right kidney and other organs of the viscera of mammalian hosts followed by the pre-adult or infective larva of the nematode parasite, *Dioctophyma renale* (Goeze, 1782), the Giant Kidney Worm, and the pathology of invasion and localization in the tissues.

Introduction

The largest and by far the most spectacular of the parasitic nematodes is the "Giant Kidney Worm" of man and many other mammals, Dioctophyma renale. Many records of the occurrence of this parasite are reported from the Canadian provinces of Quebec, Manitoba, and Ontario and in the United States from the states of Arkansas, Illinois, Kentucky, Maine, Maryland, Michigan, Minnesota, New York, New Hampshire, North Carolina, South Carolina, Ohio, Pennsylvania, Virginia, and Wisconsin with some doubtful records from the states of Colorado and Iowa. There are also many records from the middle European countries.

The kidney worm has been found in the abdominal cavity, in many of the visceral organs, including the liver, ovary, mesenteries and, most frequently, in the right kidney, although there are three instances reported in the literature of infection of the left kidney. The parasite has been found on rare occasions in the pericardium, the thoracic cavity, and, in one instance, in a mammary gland.

It is commonly found in the Mustelidae, Canidae, and related forms. Man has been reported as the final host in several instances.

Dr. A. E. Woodhead of the Department of Zoology at the University of Michigan has long been interested in the life history of the kidney worm, D. renale. His investigations have resulted in the discovery of the complete life cycle

and have brought up several questions, as yet unanswered, among which is the question of the means by which the infective larva reached its final localization in the mammalian host and the route of migration through the body of the host to reach its ultimate destination. I was introduced to this problem early in the summer of 1948 and the investigations reported herein continued from that time to August, 1951.

The method of reaching and penetrating the kidney of the mammalian host has long been a matter of doubt with many speculations and postulations being advanced. It had been generally accepted that the larva after having been ingested, left the digestive tract via the blood stream and was carried to the kidney. This idea did not account for the incidence of the adult worm in the body cavity of the host. Stratton (1843) postulated the opinion that the method of entry into the final host was through the uro-genital system. Sonsino (1897) suggested that the pre-adult worm entered its final host through the uro-genital aperture, gaining access to the peritoneal cavity by passing through the funnel of the fallopian tube. Wislocki (1919) found twelve infections in the body cavity; in only two cases could it be ascertained that the portal of entry was through a partially destroyed kidney. Lukasiak (1930) reported that in all of his research, he had never been able to find larvae nor relatively young forms in the kidneys. He stated that he did find young adults in the body cavity with the greatest number of them being found

between the lobes of the liver. Ejsmont (1936) believed that the migration of the larva through the liver was the cause of the usual location of the worm in the right kidney and that all other sites of residence in the final host were to be considered as abnormal. Stefanski and Strankowski (1936) reported a case in which a kidney worm in the body cavity of a dog was evidently in the process of entering the right kidney without any evidence of lytic action upon the tissue. Using this and similar cases, they concluded that the infective larva, after excystment in the digestive tract of the mammalian host, entered the blood stream and was filtered out at the first stop in the liver where it spent part of its life. The larva was then believed to have burrowed out of the liver into the body cavity where it spent another period of its life, penetrating the kidney only after the final molt. The worm spent the remainder of its life within the kidney in a cavity which was formed by the lytic action of the enzymes produced by the parasite.

No experimental investigations were conducted in attempts to prove or disprove the speculations. Thus, in an attempt to discover actually what does occur, I have undertaken to investigate the problem. A solution seemed more likely to succeed when this problem was begun, partially, because so much excellent work had been accomplished by some of the past and contemporary workers and the mystery of the life cycle of the kidney worm had been solved. I had an advantage over previous workers in that the infective

larvae were known to me whereas they were not recognized by the earlier investigators. This is in no way intended to discredit the splendid ground work done by early students which provided the basis for subsequent investigations.

During the course of this investigation, much of the pathology was correlated with the work done by McNeil (1948) and Woodhead (1950).

Historical Review

The parasitic nematode, Dioctophyma renale, has been known since the sixteenth century, and until recently, 1950, the postulations as to the life history had been largely speculations. The first written evidence of Dioctophyma renale (Goeze, 1782) appeared in the anatomical work of Caesalpinus (1519-1603). Jean de Clamorgan (1583) sketched a nematode which he called an Eustrongylus snake.

Barthalinus, Kerking, and Rayger (1670) were of the opinion that people became infected with Dioctophyma renale by means of bites by mad dogs. Because the parasite was present, the dog foamed at the mouth and appeared to be rabid. In the works of Redi (1684), Vallisneri and Hartmann (1685), and Klein (1755) were found a few precise, and several fantastic, sketches of the nematode. Redi stated that when the worm was discovered in the sixteenth century, it was believed to be a snake. Goeze (1782) first classified the nematode parasite in a helminthological system. Collet-Meygret (1802) made some reasonably precise descriptions of the worm. Rudolphi (1802) studied the worm, publishing some fairly accurate descriptions of it. During the seventeenth, eighteenth, and early part of the nineteenth centuries, much interest was aroused among the members of the medical profession since the parasite was found in man.

Bremser (1819) described the external structure and appearance of the kidney worm in some detail. He considered

the medical importance of the parasite on the basis of the many cases reported in man.

Riley and Chandler (1916) reported the case of a dog which succumbed to an infection by D. renale.

Lukasiak (1930) produced the most outstanding and extensive work on D. renale to the date of his publication. He studied 2338 dogs from Warsaw, Poland, and surrounding regions. He found 88 cases of infections by D. renale which was 3.76 percent of the dogs autopsied. There was a total of 138 worms, 80 females and 58 males. These totals represented 58 percent females and 42 percent males. Location of the parasites in the hosts was also recorded. There were 102 worms located in the right kidneys of 63 dogs, 74 percent. Among the lobes of the liver were 25 worms, 18 percent. In all other organs, 11 worms were found, 8 percent. The other organs to which he referred were the mesenteries in which he found 6 worms; between the right kidney and the peritoneum, there were 4 worms and 1 in the right ovary. He described the morphology and anatomy as well as some of the embryology and pathology. He included a review of the taxonomic literature to 1926.

Underwood and Wright (1934) summarized the North American records of infections by D. renale in addition to reporting a new infection from a German shepherd dog.

Patterson (1936) reported removing an adult D. renale from the mammary gland of a dog which had come to Michigan from the Pacific coast. This worm was a female measuring

75 cm long. The source of the dog and how long it had been in Michigan were not revealed in the report.

Chitwood and Chitwood (1937) described in detail the layers composing the cuticle of D. renale.

Graves (1937) reported removing two kidney worms from the right kidney of a year-old mink from Wisconsin. One of these was a female measuring 44.5 cm long and the other a male, 48 cm long.

Moore and Schooley (1939) reported an infection in a dog in North Carolina. The liver was ruptured and the resultant hemorrhage passed through a perforation in the diaphragm into the thoracic cavity causing the death of the host.

Woodhead and McNeil (1939) reported that 8.6 percent of all mink examined from southern Michigan during the trapping season of 1938-39 were infected by D. renale.

Cameron, Parnell, and Lyster (1940) reported D. renale in a dog from Berens, Manitoba. In this instance, both kidneys were infected, which is a rarity. Both of the worms were females measuring 75 cm long.

Brown, Sheldon, and Taylor (1940) found that 37 percent of the dogs examined from a limited area in North Carolina were infected. This is the highest incidence reported in the literature to this date from any one area. They reported no previous cases of infection by the parasite for that state.

Dunne (1940) reported finding two specimens of D. renale

in a dog which had been brought to Iowa from Minnesota. A male worm, 32 cm in length, was free in the body cavity, and a female kidney worm, 82 cm in length, was found coiled in the right kidney.

Woodhead (1941) reported the first description of the hatching of D. renale eggs. The eggs were reported to have been ingested by certain branchiobdellid (Oligochaeta) worms and subsequent to ingestion, they were observed to hatch within the gut of the host worm. The larvae were seen boring through the intestinal wall and migrating into the body spaces where they formed tightly coiled cysts. A relationship between the larvae of Paragordius and the larvae of D. renale was suggested.

Sealander (1943), during a study of the parasites of the mink of southern Michigan in the season of 1940-41, reported four infections by D. renale among 158 mink.

Erickson (1944) reported an incidence of 5.5 percent of infection by D. renale in the timber wolf, Canis lupus, of Minnesota.

Randall (1944) encountered two kidney worms in the right kidney of a dog in Colorado. The worms were 81 cm and 56 cm in length, respectively. The dog had been fed a fish diet and had come to Colorado three months prior to its death.

Morse (1945) reported a worm from the abdominal cavity of a dog in Virginia. The worm was 58.5 cm long. The kidneys exhibited no lesions or exit portals.

Erickson (1946) found 5 of 72 ranch-raised mink infected by D. renale. They were discovered during a survey of the parasites of the Minnesota Mustelidae.

McNeil (1948) studied the pathological changes in the kidney resulting from infections by D. renale.

Graham and Mark (1949) reported a case of D. renale in an English bulldog in Pennsylvania. A nephrectomy of the right kidney was performed. The dog made a complete and uneventful recovery. There was a female kidney worm, 86 cm long, in the right kidney.

Meyer and Witter (1950) reported a case of infection by D. renale in a ranch-raised mink from Maine. The rancher reported that the mink became ill in March and died eight months later. A second case was reported at a later date, but little else is known regarding the latter case. It was reported that the mink had been fed frostfish and pollock; these being colloquial names, it is difficult to ascertain from the report the actual fish which had been fed to the mink. They reported another case of infection by the kidney worm in the right kidney of a dog from Lexington, Kentucky. Although the cases had been reported from surrounding regions, these reports constituted the first records for the states of Maine and Kentucky.

Woodhead (1950) published the life cycle of D. renale. He found that the life cycle begins with the shedding of the eggs by the adult worm within the kidney of the mammalian host. The eggs are carried from the body of the host by

the urine and ultimately reach the water where they undergo a long embryonation period, 8 to 10 months, before embryos are completed within the shells. The eggs are ingested by a few species of branchiobdellid worms wherein the eggs are carried to the intestine. The larvae emerge from the shells and penetrate the intestinal wall, migrating into the body spaces where they form tightly coiled cysts. During this encystment period, one of an unknown number of molts in the life history takes place. The branchiobdellid lives as an ectoparasite on the crayfish. This provides an excellent method of gaining entry into the second intermediate host, a fish. The crayfish carrying the infected branchiobdellids is swallowed by the fish as a part of its normal diet. The fish in question were found to be the bullheads, Ameiurus melas and Ameiurus natalis. The larvae are excysted by the digestive action of the gastric juice enzymes in the the stomach of the bullhead and migrate through the wall of the stomach only to be trapped in the mesenteries which surround the stomach. A series of morphological changes and molts were observed to take place in the mesenteries. Some larvae were found encysted upon the surface of the liver. During the molts and encystment, the larvae develop to the pre-adult or infective stage. The infective larvae were found to be approximately 10 mm in length. They have no visible head differentiation. They are not unlike the adult. The last stage in the life cycle begins with ingestion of the infective stage larvae by a suitable mammalian

host. Once ingested, the larvae emerge from their cysts in the stomach and migrate to the site of final localization in the body of the final mammalian host. When fertilized eggs are shed by the adult female, the cycle is completed.

The historical review of the literature includes some items which have been cited in the thesis by C. W. McNeil (1942), but have a definite bearing upon the subject being considered in this investigation. The most outstanding work to the present date was the publication of the life history of the kidney worm by Woodhead (1950).

Methods and Procedures

Since it was my aim to discover additional evidence concerning the route followed by the pre-adult or infective larva in its migration to the right kidney or other visceral organs of the mammalian host, it was decided that the investigation should begin with the entry of the infective larva into the digestive tract of the final host. In order to secure infective larvae, an area for collections in Livingston County in southern Michigan was selected. Mink which were known to be infected by D. renale were present in the area. Mink are the most common hosts for kidney worms in nature and are considered the definitive hosts. Previous work on the kidney worm had been done with material collected from this area by Woodhead from 1938 to 1950.

The area was typical of most mink range country. It was marshy, bordered by sparsely wooded areas and farm lands covered with a heavy growth of tall weeds and marsh grass and a few scattered trees and bushes. Coursing its way through this area, was a small stream, Woodruff Creek. It connected with the Huron River, five miles distant. The creek was a series of rapid currents alternating with sluggish pools and eddies. There were several small tributaries which emptied into the main stream. Originally, a wooden dam impounded a small artificial lake that was interposed in a drainage ditch that emptied into the stream. In another part of the main stream, a still

larger natural lake occurred. The stream bottom ranged from a gravel and boulder type in the rapid stretches to a muddy, organic detritis type in the sluggish pools.

All of the forms necessary to fit into the life history scheme of D. renale were inhabitants of the stream or neighboring land areas; the crayfish, the vector which carries the branchiobdellid worms, Cambarinicola chirocephala and Cambarinicola vitrea; the bullheads, Ameiurus natalis and Ameiurus melas; the mink, Mustela vison. In the order named, these represent the first and second intermediate hosts and the final host in the life cycle of D. renale as was found by Woodhead (1950).

Fish traps were made by stretching hardware cloth with a mesh having one-half inch squares over a wooden box frame measuring 19 x 24 x 28 inches. A cone of hardware cloth with the inner opening, 3 inches in diameter, extended into the center of the trap.

Fish traps were placed in Woodruff Creek at Skeman's Bridge in water varying from 2 to 3 feet deep. The traps were situated in the shadows under the bridge where bullheads were known to frequent. Beginning in early April, and continuing throughout the summer until late November, the traps were emptied once or twice each week. In addition to this source of bullheads, seinings were made through a culvert which ran under a road bridge and drained the overflow from a small dam belonging to Mr. Henry Klekot. This dam impounded a drainage ditch to form a small artificial lake.

The drainage ditch connected with Woodruff Creek at a point approximately one-half mile upstream from Skeman's Bridge.

Klecot's dam which impounded the small artificial lake burst early in the year of 1949, permitting a heavy flood of water to sweep downstream. It resulted in a wash out of all of the fish population. The remainder of the year was of no value for collecting infected bullheads. The stream was impounded by a larger concrete dam as a replacement for the old one. A secondary barrier was made further upstream from the dam in the form of a roadbed across the lake with a very small pipe through it to permit the flow of water into the lake from the drainage ditch. It is suspected that some of the infected bullheads had been swept over the top of the dam during their nocturnal feedings or in high water and had been captured in the lower portions of the stream. At the new dam, the overflow of fish was prevented by a barred grating. No infected bullheads were collected during the summer of 1951. It is suspected that the new impoundment of water and fish had prevented their escape to places where they were available for study. Another contributing factor to the absence of infected bullheads in the stream could be that during the period when Woodhead collected in this area, Mr. Klekot raised mink beside the stream. This resulted in the attraction of wild mink during the breeding season and for available food. He has since discontinued his mink ranch, therefore, it is supposed that the wild mink were no longer attracted to the

area and the chances of there being a continuance of the numerous infected bullheads was eliminated.

Table I records a summary of the numbers of the bullheads taken from Woodruff Creek during the years of this investigation, including the larval D. renale found in the mesenteries of the fish. A comparatively low percentage may be noted.

There were several other parasitic forms encountered in the mesenteries of the bullheads taken from this creek. Spiroxys contortus was the form most frequently found. There were some other parasites which encyst in much the same way as do the larvae of D. renale. The most prominent were the Eustrongylids. Larval proteocephalids and some Acanthocephala were encountered.

The cysts of the infective larvae of D. renale are found in the mesenteries which surround the stomach of the bullhead. These are made up of a few host tissue cells and much connective tissue which may have been formed by the body of the host to seal off the parasite. It is not known whether cystogenous glands exist in the kidney worm. The cyst wall is opaque and the larva within is often difficult to discern other than by vague outline. The larva is usually coiled in an irregular and awkward position. The cysts are poorly supplied with blood vessels. They are nearly uniform in size and shape, 1 to 2 mm in diameter, usually round and tough. They are milky-white in color, but may vary with age. If there are more than the usual

Table I. Numbers of bullhead collected and number of D. renale larvae obtained from 1949 to 1951.

Month	Total No. Bullheads	No. Ameiurus natalis	Larvae	No. Ameiurus melas	Larvae	Total larvae
Season 1949						
April	28	13	-	15	-	-
May	53	29	5	24	-	5
June	209	36	1	163	-	1
July	46	17	1	29	1	2
August	117	52	4	65	1	5
September	20	6	-	14	-	-
October	70	43	-	27	-	-
November	9	6	-	3	-	-
Totals	542	202	11	340	2	13
Season 1950						
April	3	-	-	3	-	-
May	65	22	-	43	-	-
June	141	73	8	68	-	8
July	26	-	-	26	1	1
August	77	12	-	65	-	-
September	30	8	-	22	-	-
October	36	31	-	5	-	-
November	14	10	-	4	-	-
Totals	392	156	8	236	1	9
Season 1951						
May	10	-	-	10	-	-
June	98	22	-	76	-	-
July	52	17	-	35	-	-
August	11	8	-	3	-	-
Totals	171	47	-	124	-	-
Grand Totals	1105	405	19	700	3	22

number of blood vessels in the cyst wall, the cyst may appear red. The characters listed were used to identify the cysts of D. renale.

There were some instances in which the larvae were free in the mesenteries and not encysted in typical cysts. No accurate explanation of this occurrence can be made other than to suggest that the larval forms had completed their development and having reached this stage in their life history, emerged from the cyst to continue a partial development toward the adult form. Some cysts were found in the mesenteries which contained the remains of the cuticle with no evidence of a living larva. The probable explanation for this occurrence is that the larva had developed normally within the cyst, but since the intermediate host had not been captured by the mink, the larva eventually died.

Woodhead (1945) described clear cysts containing the larvae of D. renale located on the surface of the liver lobes. They contained 10 mm infective larvae.

Cysts were obtained at autopsy during which the mesenteries were removed by cutting them at a point near the spleen and allowing the stomach to slip out. The mesentery was then severed at the liver. Cysts were placed in 0.9 percent saline solution and examined microscopically. If nothing of significance was revealed, the mesenteries were placed in an artificial gastric juice and warmed slightly by the heat from a small electric bulb. They

were allowed to remain in the solution until the gastric juice enzymes through digestive action had weakened the tissue enough to permit the larval worms to escape from their cysts. The positive identification of the larval kidney worms then proved to be a simple matter.

The larvae, if any were present, were either fed to experimental animals or fixed in a special mixture of Travasso's fixative. The mixture included the following ingredients: 92 percent 0.9 percent saline solution, 5 percent of 5 percent formalin, and 3 percent of glacial acetic acid. The solution was found to be more effective if used at 60 degrees Centigrade.

The infective larvae were fed to the experimental animals in a commercial brand of canned dog food. The larvae which had been excysted in the gastric juice were fed to the experimental animals by placing them within No. 5 gelatin capsules. The animals quickly regurgitated the capsules, but retained larvae which had been fed in dog food or pork liver.

The projected plan for the study of the pre-adult larvae in their migration through the final host suffered a set-back when laboratory-reared kittens were used as the experimental final hosts. It was believed that the cat would serve well as an experimental final host since Janicki (1934) reported a kidney worm in the thoracic cavity of a cat. Stefanski, Strankowski, and Nagorski (1936) reported another infection by D. renale in a cat

where the adult worm was located in the thoracic cavity. The cats proved to be resistant to infection even though they had been fed what were believed to be infective larvae. All of the kidney worm larvae that were obtained during the summer of 1950 were lost in cats. It is my opinion that the cat is not suitable for experimentation with infections by larval D. renale. There is a possibility, however, that the larvae which had been fed to the kittens had not yet attained the infective stage, since no experimental feedings of larval kidney worms to laboratory animals were successful in so far as recovery of adult worms is concerned when the larvae were fed earlier than the month of July.

The German fitch, Mustela putorius, or ferret as it is more often called has been used with success in the past as an experimental final host for feeding experiments with the infective larvae of D. renale.

I made the first experimental feedings to a pair of ferrets during the summer of 1949. One of the feedings resulted in a multiple infection; the other was unsuccessful. These feedings are discussed in detail later in this paper in the section concerning experimental feedings.

The proposed method of study of the migration was one including progressive feedings to experimental mammalian hosts and observing the development and the paths of migration of the parasite at autopsy in definite intervals. Observations were to be made of the growth and development during the course of the migration. The organs were to be

fixed and sectioned for microscopical examination. The sections of the various organs were to be checked for traces of the migration paths. The intervals between feeding of the infective larvae and the killing of the experimental host and autopsy were set up to be from 72 hours to 60 days. The difficulty with a plan of this kind is the fact that the infective larvae of the kidney worm are scarce in nature and difficult to obtain in sufficient numbers to make all the feedings that are necessary. Some of the evidence, therefore, was taken from examinations of natural infections.

A gross examination was made at autopsy and a determination made as to the presence or absence of an infection by D. renale. Subsequent to the gross examination of the visceral organs concerned, including the stomach, duodenum, lobes of the liver, the kidneys, and the surrounding tissues, they were placed in fixative solutions. The fixative most often employed was Bouin's fluid.

Many difficulties were experienced in sectioning the tissues. Most of the tissues, including the liver and kidneys, became very brittle in the fixation and dehydration. They fractured badly when sectioned. The hardness possibly resulted from the fact that included in these tissues was clotted blood which in itself becomes extremely hard; in addition, these tissues contained salts which tend to add brittleness. A double infiltration technique was tried, using celloidon and paraffin together. This technique

was not successful, because the tissues were too large for good infiltration to be achieved. The blocks of tissue had to be intact in order that proper relationships could be maintained and an accurate interpretation of the results achieved.

The staining methods which proved to be most satisfactory were Mallory's Triple Connective Tissue Stain and Harris' Acid Haematoxylin followed by phyloxine as a counterstain. The scar tissue and connective tissues stained well in these preparations and were easy to trace when present in the sections. The stains were adequate for pathological studies.

Further studies were made upon preserved mink carcasses which had been trapped by professional fur trappers in southern Michigan in 1939-40. Additional material was obtained from New Hampshire, Illinois, and southern Michigan in 1950.

Part I

Experimental Feedings of Infective Larvae of D. renale to Mammals

Case I: Ferret Number Two.

A shreddy-appearing cyst containing the infective larva of D. renale was found in the mesentery surrounding the stomach of a 10-inch gravid female Ameiurus natalis on May 18, 1949. Two additional cysts were discovered in the same mesentery on the following day and they were identified as cysts containing the infective larvae of D. renale. The pre-adult larvae in these cysts measured 10 mm in length. The cysts were primarily composed of a fibrous connective tissue and were supplied with a few minute blood vessels. The cysts were fed to an experimental ferret in a small piece of pork liver at 4:30 PM., just prior to the regular evening feeding time. The only other food ever fed to this animal was a commercial brand of canned dog food and canned salmon. A fourth cyst was found in the mesenteries of a 9-inch gravid female Ameiurus natalis. It was fed to the ferret at 4:15 PM., on June 8, 1949.

The ferret was killed and autopsied on October 3, 1949, 140 days subsequent to the first feedings of infective larvae and 117 days after the introduction of the last of the four cysts. Upon opening the abdominal cavity, the visceral organs appeared to be normal. There was one exception in the form of a small, clear, blister-like

spot on the left lobe of the liver. It was dissected and a pathological study of the tissue made. The nature of the lesion was not determined, but it was decided that it bore no relationship to a D. renale infection. The lungs contained some scar tissue and there was an enlarged lymph nodule near the first loop of the duodenum. It was examined and nothing of significance was discovered.

This was considered to be a negative case in so far as an infection by D. renale was concerned.

Case II: Ferret Number One.

A cyst which was identified as one containing the pre-adult larva of D. renale was discovered during and autopsy of an 11.75-inch male Ameiurus melas. The fish had been taken from Woodruff Creek 10 to 30 months previous to autopsy and had been isolated in an aquarium in the Zoology Department at the University of Michigan. A commercial brand of a canned dog food was the only food which had been fed to the fish in captivity. There was no possible source of reinfection. The cyst was located in the mesenteries surrounding the stomach and was of a hard and fibrous nature with opaque walls. It measured 1.5 mm. in diameter. A pre-adult larva of D. renale was barely visible through the translucent wall and measured approximately 20 mm in length. The worm appeared to be still viable since clearly perceptible movement was observed. This 10-30-month-old cyst was fed to Ferret Number One at 9:00 PM. on August 8, 1949, four hours

after the regular evening feeding time. It was fed in a small piece of its regular food.

Bullheads were taken from the trap in Woodruff Creek on August 10, 1949, and were killed and autopsied on the same day. In a 10-inch gravid female Ameiurus natalis, a tough fibrous cyst was found in the mesenteries. The larval kidney worm could scarcely be seen through the opaque cyst wall which is typical of all D. renale cysts found in bullheads. A second cyst was found in the mesenteries of a 9.5-inch male A. natalis. The cyst was oval shaped and measured 1.5 mm in diameter and 2 mm in length. It had a tough, fibrous cyst wall. Both of the above mentioned cysts were fed to Ferret Number One at 9:00 PM., August 10, 1949, four hours after the regular evening feeding time.

During the course of the presumed infection, the animal was observed daily for any external signs or symptoms which might be indicative of an infection by D. renale. There seemed to be a great deal of thirst associated with the infection. The animal was subject to violent shudders and convulsive fit-like reactions.

Ferret Number One was killed on October 3, 1949, 57 days subsequent to the introduction of the first cyst and 55 days following the feeding of the last two cysts. A total of three cysts had been fed and all contained what were believed to be viable larvae.

The autopsy revealed the great omentum lacking in

fat and in very poor condition. Lying immediately beneath and over the intestine, extending anteriorly and penetrating through the right lobe of the liver, was a 7-inch female D. renale. A smaller worm, a 4-inch male, was found in the median lobe of the liver, literally laced throughout the liver tissue. The head and posterior ends were exposed. It had to be dissected out of the liver to avoid puncture or breakage. Both of the worms were a vivid, brilliant scarlet and very turgid. The pathway or tunnel throughout the liver tissue was lined by a very thin scar tissue indicating a lytic action upon the tissue by the enzymes apparently secreted by the glands in the head region of the kidney worm. There was no evidence of mechanical damage such as chewing or tearing caused by the worm.

Photographs were taken of various stages of the autopsy and some of them appear in the Photographic Appendix.

The worms were removed and placed in a 0.9 percent saline solution and refrigerated at 5 degrees Centigrade. They remained alive and relaxed for several days after which they were fixed in Pick's Solution No. I for two days. The solution consists of the following: 4 liters of water, 200 cc of formalin, 2.5 gm potassium sulphite, 23.3 gm sodium chloride, 48 gm sodium bicarbonate, and 133.3 gm sodium sulphate. After being washed in water, the worms were transferred to Kaiserling's Solution No. III which is composed of the following: 1875 cc of water, 187.5 gm

potassium acetate, 500 cc glycerine, 6.25 cc of 86.4 percent phenol. These solutions do an excellent job of fixation and color preservation. To insure good results, all traces of alcohol should be avoided in the washing solutions between fixation and preserving fluid.

Prior to the fixation the female worm was examined for the presence of eggs. None were found in spite of the fact that both sexes were present in the host. It is believed that the worms had not attained sexual maturity.

The right kidney was distended into a large blister-like deformity occupying the latero-posterior third of the kidney. It was very turgid and, when opened, released a watery red fluid which is similar to that found in an infection of a kidney containing adult worms. There was no immediate evidence to indicate that the worms had been in the kidney or had been the cause of the deformity.

One of the lymph nodes in the mesentery was enlarged, but there was no evidence to account for this condition other than the presence of the worms in the body cavity. There was some fibrosus of the mesentery, apparently caused by the presence of the worms which may have been among them at some time during the course of the infection.

A section of the duodenum adjacent to the spigelian, lobe of the liver, the spigelian lobe of the liver which normally covers the anterior portion of the kidney, the damaged right kidney, and the somewhat hypertrophied left kidney were removed intact and fixed in Bouin's fixative

for sectioning and study at a later date. Portions of the liver in which the kidney worms were found were fixed in the same manner.

The results of microscopical examination and pathological studies of the tissues are described later in this paper. Photographic plates of these tissues appear in the Photographic Appendix of this paper.

Case III: Cat Number One.

Bullheads were taken from the traps in Woodruff Creek at Skeman's Bridge on August 15, 1949. Autopsies were performed on the same day and two cysts were found in the mesenteries. One was found in a 7-inch male A. natalis and the other in a 6-inch male A. natalis. They were the typical tough, fibrous, opaque-walled cysts of D. renale with the larvae hardly visible through the cyst walls. The larvae were identified as the pre-adult infective stage larvae by the nature of the esophageal-intestinal junction.

The cysts were refrigerated in a 0.9 percent saline solution at 5 degrees Centigrade until such time as an experimental animal would be available for a feeding experiment. On August 18, 1949, a small house-born kitten was obtained. It was two months old and had just been weaned. The two cysts containing the infective larvae were fed to the kitten in a No. 5 gelatin capsule on August 19, 1949, at 9:30 AM., but at 10:00 AM., the whole of the stomach contents was regurgitated. All of the material was

recovered since the bottom of the cage in which the kitten was housed had been covered with a heavy paper in anticipation of such an occurrence. The stomach contents were placed in a 0.9 percent saline solution and examined microscopically. Most of the material was a milk curd, since following the feeding of the cyst, the kitten had drunk some milk. Both of the cysts were recovered, the gelatin capsules having been dissolved. The cyst walls were still intact and the larvae within appeared to be still alive in as much as perceptible movement within the cysts was observed. The cysts were fed to this animal again, this time, in a small piece of a commercial brand of canned dog food. The feeding was accomplished at 8.30 PM.

The kitten was killed and autopsied on October 3, 1949, 46 days subsequent to the feeding of the infective larvae. Upon opening the body cavity, it was revealed that all visceral organs were intact and in good condition. There was no evidence of any scars or lesions in the thorough exploration of all of the organs in the thoracic and abdominal cavities. It was determined that no invasion of the tissues by the infective larvae of D. renale had occurred. The results of this experiment were negative.

Case IV: Cat Number Two.

During the collecting season of 1950, bullheads were collected and saved in an aquarium until June 19, 1950. It was hoped that by the change in technique, from the immediate autopsy of the fish after capture, more cysts containing infective larvae could be secured simultaneously.

If several larvae could be obtained at once, multiple feedings could be accomplished and multiple infections achieved. During a gross examination of the mesenteries removed from the bullheads on June 19, 1950, no cysts or kidney worm larvae were noticed. The mesenteries were stored in artificial gastric juice at 5 degrees Centigrade for 48 hours. Four cysts were discovered at the next microscopical examination. Three of them were identified as the cysts of the kidney worm and the fourth was identified as the cyst of a Eustrongylid worm, a cyst which resembles the kidney worm cyst in many ways. The method of distinguishing the two cysts was accomplished by making a comparison of the lengths of the esophagi of the larvae. That of the kidney worm is very long, occupying nearly one-half of the body length with a relatively straight connection with the intestine. The esophagus of the Eustrongylid larva is comparatively short and makes a bulbous connection with the gut. The cyst wall of the Eustrongylid is transparent and the larva clearly visible, contrasting sharply with the opaque wall of the kidney worm cyst. The cyst of D. renale is usually smaller than that of the Eustrongylid and round instead of oval. The kidney worm is usually coiled in an awkward fashion within the cyst while the Eustrongylid worm is usually in graceful coils.

All four cysts were fed to a laboratory-reared kitten in a small piece of commercially canned dog food at 11:00 AM.

on June 22, 1950. The feeding was made after the kitten had appeared to have eaten all of the canned dog food and milk which had been placed in its cage at 8:00 AM. of that day.

The kitten was killed and autopsied on July 21, 1950, 30 days following the introduction of the infective larvae. No abnormality, lesions, or scars were observed during the exploration of the various organs of the visceral and thoracic cavities. All organs were in a healthy condition and there was no evidence to indicate an infection by D. renale. This experiment was considered negative.

Case V: Cat Number Three.

Some bullheads were autopsied on June 19, 1950, and the mesenteries were placed in artificial gastric juice and refrigerated at 5 degrees Centigrade until June 22, 1950. There were three cysts with viable D. renale larvae within them and four larvae free in the solution. These had apparently been released from their respective cysts by the action of the digestive enzymes in the gastric juice. The larvae, still within their cysts, were fed to Cat Number Three in a small piece of dog food at 9:00 AM. on June 23, 1950.

The kitten was killed and autopsied on July 21, 1950, 28 days subsequent to the feeding of the infective larvae within their cysts. Upon opening the body cavity, all organs appeared to be in perfect condition with no evidence of lesions of any kind or any damage which may have resulted from the presence of the larvae of D. renale. This case was considered to be negative.

Case VI: Cat Number Four.

The bullheads which had been collected during the spring of 1950 were autopsied on June 23, 1950. Two typical kidney worm cysts were found in a 9-inch gravid female A. natalis. Found on the stomach, they were tough and opaque and possesed all of the identifying characteristics which distinguish the cysts of D. renale. A third cyst with the larval kidney worm one-half emerged from the cyst was found in the mesenteries, the cyst wall partially digested by the gastric juice enzymes. It was found in the stomach mesentery of an 8.25-inch male A. natalis. A fourth D. renale larva was found among the mesenteries, the cyst wall completely digested away. When the mesenteries are placed in artificial gastric juice, the cysts are digested without any apparent injury to the larval worm. This enables the worker to make a positive identification and avoid any mechanical injury to the larvae. All of the above mentioned larvae were fed to a kitten in a small piece of a commercial brand of canned dog food at 9:00 AM on June 23, 1950. The kitten was one of the litter of three which included the kittens used in the previous reported cases.

The kitten was killed and autopsied in the laboratories on July 21, 1950, 28 days following the introduction of the infective larvae of D. renale. The autopsy revealed all of the visceral organs to be in perfect condition in gross aspects. There was nothing indicative of an infection by the kidney worm.

An unusual growth in the form of an extra papilla on the median lobe of the liver was observed. It was removed and fixed in Bouin's fixative; sections were stained in Mallory's Triple Connective Tissue Stain. There was no indication of an infection in the papilla and the cause for this superfluous growth could not be explained.

The results of this experiment were negative.

Part II

Studies of the Migration Route to the Right Kidneys by D. renale in Experimentally Infected Mammals

Case II: Ferret Number One.

The details of the experimental infection of this animal and the records of the gross aspects of the infection as they were observed at autopsy appear in the section of this paper concerning experimental feedings.

Sectioning of the block of tissue containing the infected right kidney and the spigelian lobe of the liver had to be abandoned because of the brittleness of the tissue. The paraffin was removed and the tissue softened in aniline and methyl salicylate. The tissue was re-embedded in paraffin and soaked in water prior to sectioning.

During the period that the tissue was soaking in the aniline and methyl salicylate, the cut surface of the tissue was examined. Evidence of migration paths through the liver and the kidney was observed. The block was sketched in all views, Plate I. The paths appeared to penetrate the spigelian lobe of the liver which was in close proximity to the anterior portion of the infected kidney. The worms were not present in the spigelian lobe of the liver at autopsy. The migration path in the liver lobe ran from the anterior tip directly toward the kidney, making a turn into the hilus of the kidney. The path was obliterated in that region, because the observations were being made from a block of tissue and paths other than those which

appeared on the surface, could not be seen. There was a large cyst-like cavity in the posterior portion of the kidney on the distal side. It occupied most of the cortical layer and extended deeply into the pelvis. There was evidence of an opening which had been sealed off by connective tissue at the posterior apex of the kidney. The direction of the path could not be determined at this time. An invasion tunnel probed deeply into the liver tissue and ended blindly.

A microscopical examination of the supposed migration path further substantiated the idea that these represented a migration route and invasion of the kidney and liver. An examination of the tissue in gross aspects gave the impression that the tunnels which were being interpreted as migration paths might actually be blood vessels or the ureter. The epithelium was not of the transitional type discounting any chance of the path being the ureter. No muscle tissue was present in the path, and, therefore, it could not be a blood vessel. There was some blood in the tunnels, but this could easily be attributed to the seepage of blood during autopsy.

The path measured 2.0 mm in diameter and passed through 1.2 cm of liver tissue. The resemblance to actual tunnels or pathways became quite obscure after leaving the liver, although the area between the kidney and the liver was filled with fibrous connective tissue. There was some evidence to indicate that the worms had actually passed

through the region of the hilus of the kidney. There was some resemblance to a path which continued downward into the pelvis of the kidney. It led to the cyst-like cavity in the parenchyma, opening into the cavity of the cyst at the posterior end of the kidney. The paths were lined by a scar tissue. The cyst-like cavity was lined by a thick scar tissue and had evidence of some tunneling into the cortical tissue. The glomeruli appeared to be little affected by the presence of the parasite in the kidney, but there were no glomeruli in the immediate region of the cavity. There were two openings through the cavity wall and paths through the cortex of the kidney to the capsule and the abdominal cavity. The first of these openings is shown in Fig. 25. The second pathway is shown in Figs. 32 and 33. The latter path led from a break in the kidney capsule at the anterior pole of the kidney to the cyst-like cavity. These paths measured only 1.2 mm in diameter. Photographs of these tunnels and the cyst-like cavity appear in the Photographic Appendix and line drawings of the migration through the tissues appear in the following pages.

The difference in the diameters of the paths through the kidney to the cavity in the cortex and those through the liver give rise to speculation regarding the direction of the migration of the worms through these paths. In the experimental case which is being discussed, the larval kidney worms were only 10 mm long at the time they were fed to the experimental animal, but at the end of 55 days,

young adults were recovered measuring 4 inches and 7 inches for the male and female, respectively. It is evident that considerable growth had been taking place during the interim period, part of which time may have been spent in the kidney. This change in size would account for the difference in the diameters of the respective paths. If this rapid growth factor is taken into consideration, it must be presumed that the worms entered the right kidney from the body cavity and, after having spent some time there, left the kidney by migrating through the hilus of the kidney and through the liver. The lining of the cavity in the kidney did not present the same histological picture as appears in the cases where the kidney worm has used the pelvis of the kidney as its place of localization. In the pelvic residence type of infection there is an extreme papilliferous metaplasia and a thickened pseudo-stratified transitional epithelium lining the cavity. In this case, the lining of the cavity was a thickened adventitious scar tissue. In this respect, this case can not be considered as typical of the infections of the right kidney. Plates I through V show diagramatically a series of line drawings of the sections of the right kidney and the spigelian lobe of the liver as they appear in this case. There were approximately 400 sections cut at 10 micra. Approximately every tenth section was selected for drawing in order to give an adequate illustration of the tunnels which are discussed above. The paths through the

liver are cross-hatched for identification. The smaller paths were not cross-hatched, because this seemed to obscure rather than accentuate.

Plate I shows the paths through the spigelian lobe of the liver with the exploratory path extending deeply into the liver lobe and ending in a blind pocket. The other end of this path extends into the hilus of the kidney. These drawings are made two times actual size. In Fig. 8 and the following drawings, the path may be seen coursing its way through the medullary region of the kidney. The path in Fig. 16 is shown arriving at the cyst wall. The lines extending from the cyst wall toward the medullary region represent an area of extreme compactness of the constituent cells of the kidney tissue, a character which was not found in any other portion of the kidney nor is it typical of the uninfected kidney. Figs. 21 through 24 show the turning of the tunnel to reach the cavity wall and shows a portion of the opening into the cavity. The remaining Figures on Plate IV show the opening of the cavity wall and the path which extends from that point through the cortex of the kidney to finally emerge through the kidney capsule into the body cavity. Plate V shows the other path entering the cyst and leading away from the anterior pole of the kidney where there was an opening into the body cavity. The remains of the posterior entry point are still in evidence.

The open portions of the cavity and the flattened portion on the bottom of each of the drawings represent

Turn to page 49.

Key to Plates

The following drawings were made from the right kidney of Ferret Number I and from stained sections of the tissue. They were drawn to a magnification of two times. The drawings represent approximately every tenth section in the series of sections which were cut 10 micra thick. All of the drawings were made free hand with the aid of a microscope.

The first plate shows the right kidney and the spigelian lobe of the liver as they appeared prior to sectioning.

The following is a key to the labels as they appear on the plates and identify the tissues.

BV. - Blood vessel
C. - Cyst-like cavity in kidney
CT. - Connective tissue
K. - Kidney
L. - Liver
LN. - Lymph node
MR. - Migration route
U. - Ureter

Plate I

Fig. 1. Preliminary cut surface of kidney of Ferret No. One which had been experimentally infected by two D. renale larvae. The anterior portion of the kidney is toward the right of the drawing. The face shown is the dorsal surface of the right kidney. Note the migration path in the spigelian lobe of the liver and the proximity of the liver to the kidney.

Fig. 2. Ventral view of the same kidney. Anterior portion to the left.

Fig. 3. Left lateral view of the same kidney with the anterior toward the left.

Fig. 4. Right lateral view with the anterior toward the left.

Fig. 5. Anterior view with ventral side up.

Fig. 6. Posterior view with the ventral side up.

Plate I

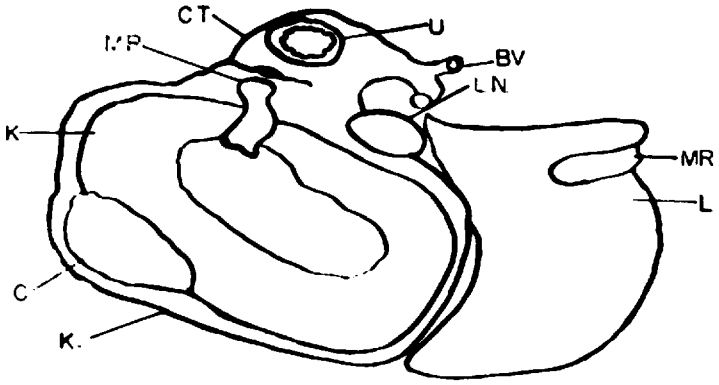

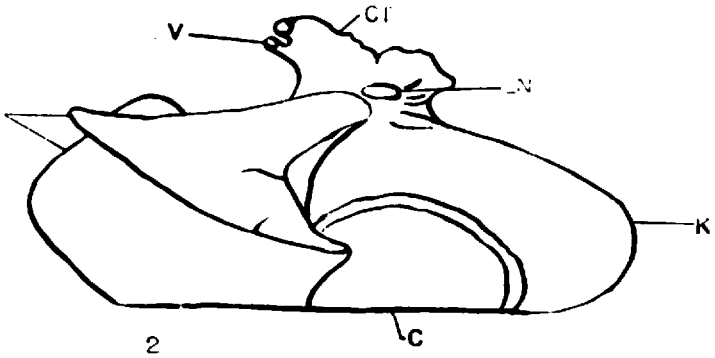

2

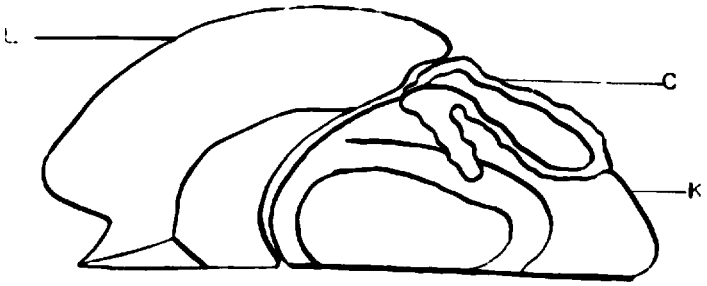

3

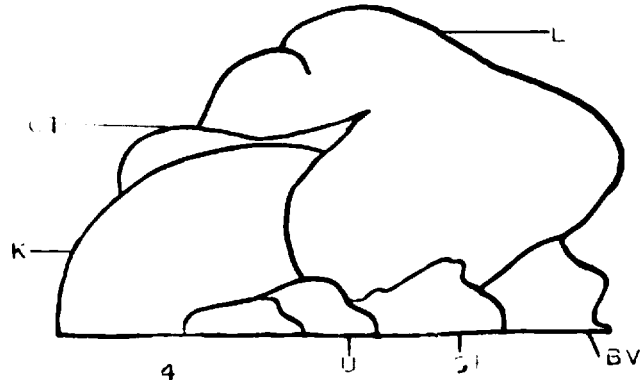

4



5

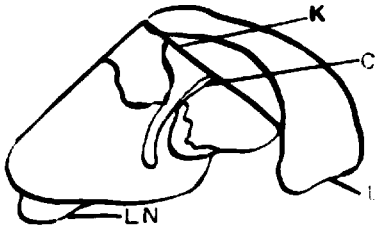

6

Plate II

Fig. 1. Slide 39. Note the escape tunnel extending through the liver.

Fig. 2. Slide 40. Note the path deviation into the liver lobe.

Fig. 3. Slide 44.

Fig. 4. Slide 57. Note path extending away from the hilus of the kidney in the fibrous connective tissue.

Fig. 5. Slide 66. Note the deviating path was abandoned and the path continued to the body cavity.

Fig. 6. Slide 75. Note the escape path in the pelvis of the kidney.

Fig. 7. Slide 82. Note path in the pelvic region.

Fig. 8. Slide 88. Note that the path is coming from the posterior portion of the kidney and still appears in the pelvic region.

Fig. 9. Slide 94.

Fig. 10. Slide 100.

Plate II.

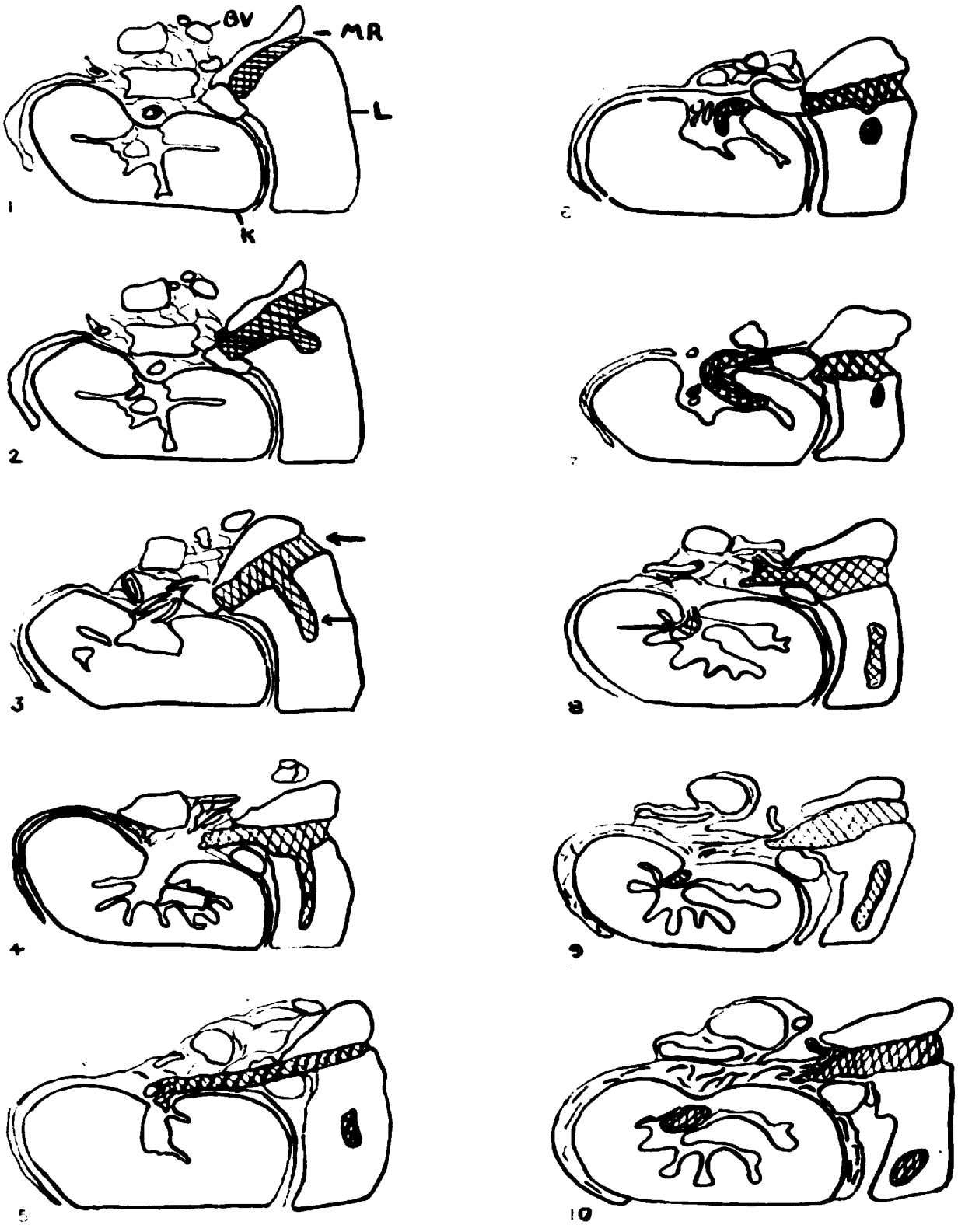

Plate III

Fig. 11. Slide 110. Note that the path in the liver has begun to disappear and the path in the kidney persists.

Fig. 12. Slide 116.

Fig. 13. Slide 132.

Fig. 14. Slide 146.

Fig. 15. Slide 150.

Fig. 16. Slide 166. Note that the path in the liver has disappeared and that the cut of the kidney is in the region of the connective tissue of the cavity wall located near the surface in the posterior dorso-lateral region. Note that the path still persists in the parenchyma of the kidney.

Fig. 17. Slide 174. Note that the sectioning has reached the lumen of the cavity and that there is an area of compact tissue near the cavity.

Fig. 18. Slide 195.

Fig. 19. Slide 200.

Fig. 20. Slide 210.

Plate III

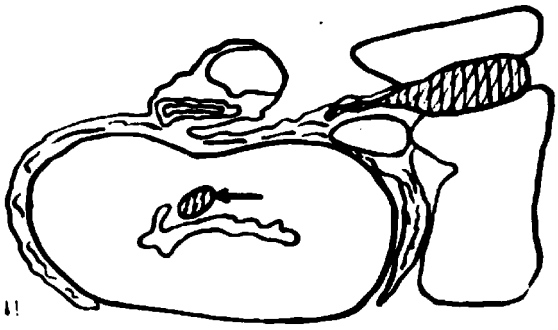
11


16

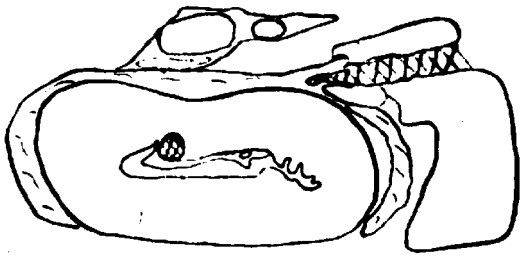


17


15


18


14


19

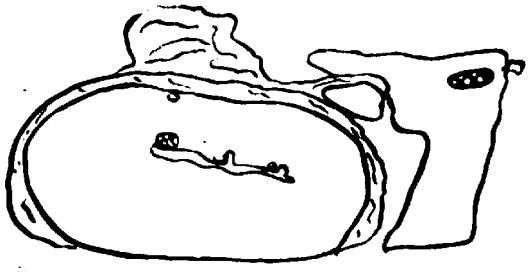
8


20

Plate IV

Fig. 21. Slide 223. Note that the path is turning away from the cavity and that the cavity is lined by heavy scar tissue.

Fig. 22. Slide 242. Note that the path is approaching its beginning at the cavity and that there are blood vessels nearby.

Fig. 23. Slide 250. Note the beginning of the escape path at the cavity in the kidney.

Fig. 24. Slide 258. Note that the path leading away from the cavity has begun to disappear.

Fig. 25. Slide 261. Note the penetration path leading from the kidney capsule to the cavity. Note that the scar tissue lining of the cavity is continuous with the lining of the penetration path.

Fig. 26. Slide 266.

Fig. 27. Slide 283.

Fig. 28. Slide 302.

Fig. 29. Slide 309.

Fig. 30. Slide 311.

Plate IV

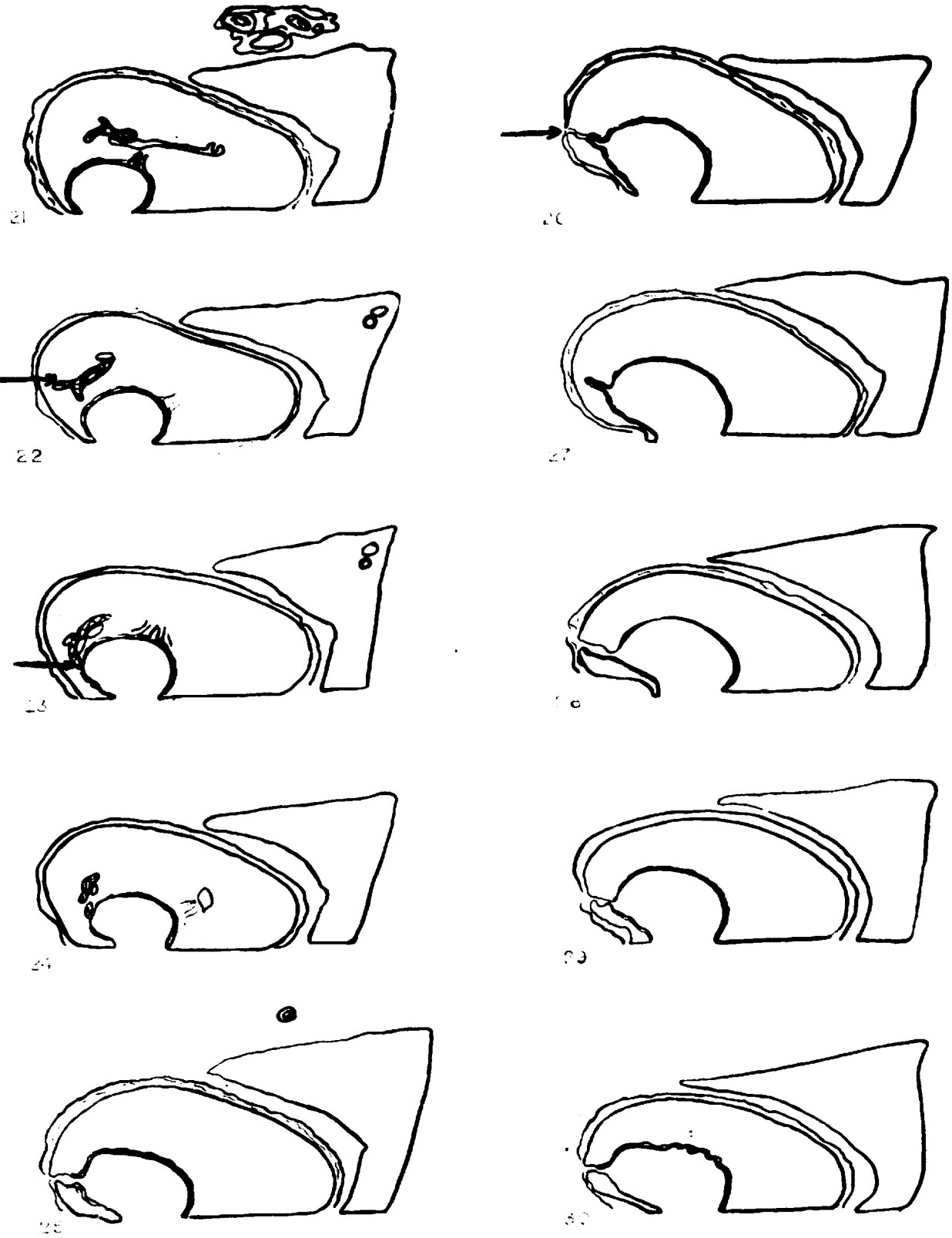

Plate V

Fig. 31. Slide 323. Note the path from the anterior portion of the kidney and the posterior penetration path which still persists.

Fig. 32. Note the anterior penetration path entering the cavity.,

Fig. 33. Slide 338.

Fig. 34. Slide 351. Note the penetration point in the kidney in the anterior pole.

Fig. 35. Slide 356.

Fig. 36. Slide 362.

Fig. 37. Slide 380.

Fig. 38. Slide 385.

Plate V



31



35



32



36



33



37



34

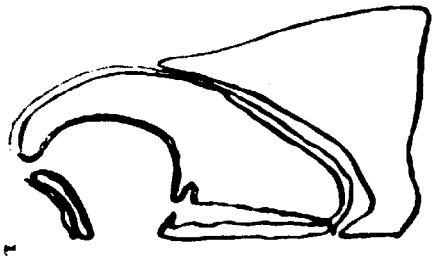

38

the first sectioning in that plane which was abandoned because of the friability of the tissue at that time.

There was doubt as to whether these tunnels leading to the cavity in the kidney from opposite poles were actually migration paths or were merely breaks caused by mechanical injury during the handling and sectioning of the tissue. This doubt was dispelled quickly by a histological examination of the paths. It was revealed microscopically that there were scar tissue linings of the cavity and tunnels and that they were continuous with one another.

The duodenum was sectioned in the same manner as had been employed for the kidney and adjacent liver. There was no pathological evidence to indicate an exit point from the duodenum into the body cavity. There was some fibrosity surrounding that portion of the duodenum which was in close proximity to the damaged kidney and liver in which the worms were found at autopsy.

The liver showed evidence of excavations and feeding tunnels. The worms were entwined in this lobe at autopsy. These tunnels showed little evidence of scar tissue. The liver, however, does not form scar tissue easily.

The uninfected kidney of this experimental animal was sectioned and stanined. A histological examination of these sections showed a low grade hypertrophy of the kidney with some evidence of glomerulo-nephritis. Some of the glomerular tufts were extremely enlarged by the swelling and proliferation of their constituent cells. The proximal convoluted tubules showed evidence of retrogressive changes in

the epithelium. There was some evidence of hydropic infiltration and fatty degeneration, but no evidence of necrosis. There was little edema and leucocyte infiltration of the interstitial tissue. The kidney was slightly larger than its infected mate; the infected kidney was 2.2 cm in length and the hypertrophied left kidney was 3.0 cm in length. The glomerular epithelium showed hyalinosis. The hypertrophy was undoubtedly brought on by the dysfunction of the infected kidney and glomerulonephritis was caused by the toxins produced in the infection.

The evidence regarding a direct migration from the stomach to the kidney is not enhanced by the evidence revealed in this case. The evidence is inconclusive. It is not known whether this happened to be a chance migration and meeting with the kidney during the feeding or a means of migration usually used by the larval kidney worms to arrive at the kidney. The chance encounter with the kidney seems to be the most plausible explanation. There is nothing to account for the worms having left the kidney where they had apparently been securely established. The location in the kidney, however, is not the usual one when a kidney is infected. That which can be ascertained is that the worms were the etiological agents of the cavity within the kidney and the tunnels which were observed, and that they could move through the tissues using the lytic powers of the penetration gland enzymes. The tissues show the reaction to the enzymes and tissue response to the infection.

Woodhead's Case I: The 30-mm Young Adult.

The following case was reported by Woodhead (1950). It is quoted here to provide a background for the report of the pathology study which I made from the infected tissue and its relation to the migration route of the kidney worm to the kidney. The slides were loaned to me by Woodhead for the express purpose of diagnosis and a study of the pathology and a possible source of information pertinent to a study of the migration route.

"Upon opening the body cavity of the dead ferret, the visceral organs all appeared in normal condition. As the intestines were moved slowly away from the right side toward the left in order to expose the right kidney, a worm was found protruding from the duodenum, adjacent to the loop in the region of the intestinal lymph node. The worm was removed and was found to have one-half of its body in the intestine. Blood was still oozing from the hole made in the intestine. The head of the worm had been forced into the body wall muscles taking a fold of the omentum along with it. In this pocket, the worm was acquiring nourishment, since the esophagus was filled with blood. The worm measured 30 mm in length. The intestinal lymph gland was diseased and contained a purulent fluid."

The ferret in this case had been fed a mixture of ground up bullheads and dog food over a period of three days. These feeding were made in the last week of July, 1945. The animal was killed three and one-half weeks subsequent to the feedings of the infective larvae. Death

from the effects of acute peritonitis and hemorrhaging from the wound caused by the worm.

Slides were prepared from the section of the duodenum through which the worm had penetrated. The sections of the duodenum were cut in such a way that they did not include the actual position of the worm when it penetrated the mucosa of the intestine. They did include that portion of the migration path which passed through the submucosa and the muscularis layer and the exit through the serosa. There was evidence of lytic action upon the tissues, but no sign of tearing or chewing. Fibrous connective tissue was found in the region of the escape portal and the path filled with a mucin substance. It was evident that there had been hemorrhaging from the blood vessels of the intestine. No necrosis was observed. The worm was aparently surrounded by a sheath of connective tissue as cross sections of the sheath appear to run parallel to the duodenum. The diseased lymph node indicated an infection caused either by the toxins produced by the infection or from the acute peritonitis resulting from the oozing of the intestinal contents into the body cavity. Microphotographic evidence is presented, prepared from the slides of this tissue.

The 30-mm young adult kidney worm is the youngest form of the parasite to be encountered in a mammalian host and reported in the literature to the date of this paper.

The case reported herein lends considerable support to the possibility that the larval kidney worm migrates directly to the kidney from the duodenum in the region

where it lies in close proximity to the hilus of the right kidney. In this case, the exit from the duodenum was made in a portion of the intestine further removed from the stomach than is ordinarily the case. The reasons for this will be discussed later.

Part III

Studies of the Migration Route to the Right Kidney in Natural Infections of Wild Mink Followed by the Pre-adult Larvae of D. renale

A study was made of the migration route of the infective larvae of D. renale in natural infections of wild mink. From preserved eviscerated wild mink carcasses lent to me by Woodhead, I was able to make additional observations concerning the migration paths. Since the intestines had been removed, a portion of the mink anatomy which was considered essential to a thorough study of the migration routes was eliminated. Some portions of the visceral organs were present in sufficient amounts to enable one to gain some additional knowledge of the migration route of the kidney worm and the pathology of the infected tissues.

All of the infected kidneys had been opened and the adult worms removed from the preserved specimens. The incisions and resultant damage to the kidneys were not found to be severe enough to interfere with the studies which had been proposed for them. The tissues were in excellent condition in spite of the long time that they had been stored. They served well for a limited study of the migration routes.

In all instances, the kidneys had been completely excavated by the parasite and the linings of the cavities were composed of a thickened pseudo-stratified transitional

epithelium. In some instances, there was evidence of calcareous infarcts in the kidney tissue. There was evidence of considerable fibrosus in almost every case with the gradient of fibrosity dependent somewhat upon the number of worms concerned in the infection, the age of the infection, and the location of the worms in the body of the host. No evidence was found to indicate the point of penetration into the kidney nor the means of gaining access to the kidney. None of the kidneys were sectioned.

Table II lists the mink which were used in these studies as well as some of the salient points concerning the infections.

Some freshly trapped wild mink carcasses were obtained from professional fur trappers during the winter of 1950-51. The portions which were to be considered were fixed and preserved for later sectioning and study after a thorough preliminary examination was made.

A wild mink which had been captured by a fur trapper was brought into these laboratories by Mr. Sini, a former student. The mink had been captured in a standard mink trap near Walled Lake, Michigan, and was received at the University of Michigan on December 20, 1950. The animal had been skinned and frozen in order to preserve the tissue until it could be delivered to these laboratories. This was a male and was assigned Specimen No. 416.

An autopsy revealed that the right kidney was

Table II. A list of the mink carcasses which were studied for D. renale infections and pathology.

Specimen No.	Collector	Date	Locality	Sex	Dioctophyma renale infections
222	Fuller	12-13-39	Mendon	Male	6 inch male in right kidney.
252	Fuller	12-27-39	Mendon	Female	Male and female in right kidney.
249	Fuller	12-27-39	Mendon	Female	2 males in right kidney.
254	Fuller	12-30-39	Mendon	Female	3 females in right kidney. 1 male in body cavity. Kidney 2.5 inches long.
318	Fuller	12-14-40	Mendon	Female	12.5-inch female in right kidney.
335	Hubbard	12-20-40	Horton	Female	2 males in right kidney, 5.5 inches long.
367	Hubbard	1-10-41	Horton	Female	1 small degenerate male 6.5 inches long in right kidney.
345	Fuller	12-26-40	Mendon	Female	Old, dry infection with cuticle of female 18.5 inches long. Bony deposits present.
295	Fuller	12-10-40	Mendon	Female	1 male 5.25 inches long in right kidney.
201	Fuller	12-10-40	Mendon	Male	2 females and 1 male in right kidney, 15.5, 17, and 8 inches long, respectively.
268	Fuller	12-7-40	Mendon	Male	7.25-inch female in blood clot in mesentery over right kidney.
147	Fuller	12-6-38	Mendon	Male	4 males and 2 females in right kidney.
416	Sini	12-20-50	Walled Lake	Male	2 males in right kidney, 7 and 8 inches long.
417	Sini	12-20-50	Walled Lake	Male	1 7-inch male in right kidney.
412	Towne	11-6-50	Sunset Point, N.H.	----	1 male and 3 gravid females in right kidney. Kidney 6.5 by 3.2 cm, poor condition.
413	Towne	11-3-50	Sunset Point, N.H.	Male	6 males and 4 females in right kidney. Kidney 6.5 by 4.5 cm. Worms in good condition, but kidney decaying. 2-celled eggs.

infected by D. renale. The kidney was opened and two young adult males were found, measuring 6 inches and 7 inches, respectively. They were removed from the kidney and fixed in Pick's Solution and preserved in Keiserling's Solution. The infected kidney was removed and fixed in a formalin solution.

The infected kidney was dehydrated in a series of increasing concentrations of alcohols and cleared in xylol. It was infiltrated with paraffin having a melting point of 50-53 degrees Centigrade and was imbedded in paraffin having a melting point of 56-58 degrees Centigrade. The purpose of having a differential in the melting points was to insure a thorough infiltration of the tissue and still maintain a condition less friable than is ordinarily the case with this type of tissue. It is usually very brittle and difficult to section on a rotary microtome.

Sections were cut at 15 micra and stained in Harris' Acid Haematoxylin and counterstained in phyloxine in 95 percent ethyl alcohol.

An examination was made of the serial sections of the infected kidney tissue relative to the migration route and the point of penetration into the kidney. Pathology of the infected tissues was studied and the following results were recorded. The kidney was completely hollowed out with little or no normal kidney tissue remaining in it. A normal histological examination of the tissue would lead one to doubt that tissue being examined was of the

kidney. The large cavity in which the worms were found within the kidney was lined in its entirety by a thickened pseudo-stratified transitional epithelium, 6 to 10 cells thick. Lying beneath this lining was a layer of smooth muscle mixed with elastic and collagenous fibers. In the few instances where there was evidence of Bowman's capsules and Malphigian corpuscles, they were degenerate and were, in most cases, being encroached upon by the subcapsular cells. The proliferation of the subcapsular cells resulted in compression of the capillary tuft. There was little evidence of any remaining collecting tubules or ducts. The whole of the medullary layers and cortical layers had been almost completely destroyed, that which still remained was crowded to the periphery of the kidney. It is evident from the condition that the infected kidney had little or no functional value as an excretory organ. The innermost layer was very papillous, that is, there were hundreds of small finger-like projections extending into the lumen of the excavation in the kidney in which the worms had localized. They were interpreted to be the remains of the calyces of the normal kidney and possibly the remnants of the pyramids and collecting tubules. Since the pelvis of the kidney in the normal condition is lined by a transitional epithelium, it is likely that the pelvic cavity enlarged because of the presence of the worms and this lining continuous and spread with the enlargement of the pelvic cavity. There

was a proliferation of the contituent cells of the lining to provide added thickness to the layer.

In a portion of the kidney distal to the hilus, and imbedded in the little remaining parenchyma, was an area of calcareous deposits. A condition of this kind was reported to be present in kidney worm infections by McNeil (1948).

The exterior of the kidney was covered by a layer of adipose tissue and some fibrous connective tissue.

Microscopical examinations were made of all of the sections in the series of this infected kidney in order to determine the region of penetration and entry into the kidney made by the larval kidney worm. The normal period of infection of mammals by the kidney worm is during the months of July and August. Therefore, it was believed that the infection in this case was of 5 or 6 months duration. That being the case, it was thought that the pathological evidence of a migration path, and the point of penetration, would likely be found in a condition in which they would be readily recognized.

Examination revealed that in the anterior region of the kidney on the side nearest the midline of the body and at a point midway between the anterior pole and the beginning of the hilus, there was a deformity in the tissue which was interpreted to be an invasion point. There was a region on the exterior of the kidney where the connective tissue covering of the kidney made an adhesion to the kidney capsule. There was an invagination

of the tissue in this region, indicating a tunneled path. Within the kidney, there was evidence of invasion in the form of small tunnels which led ultimately to the general region of the pelvis of the kidney. They were lined by scar tissue. Some fibrosus was present in the parenchyma. There was evidence of hemorrhagic infarction present in the region surrounding the point of penetration. Evidence of cytolysis and blood infiltration into the migration paths was observed. Feeding paths were in evidence throughout much of the kidney. There are no blood vessels which enter the kidney in that region, their entry point being in the hilus, therefore, what was being observed could not be confused with blood vessels. The paths had none of the histological characteristics which distinguish blood vessels.

Pictorial evidence in the form of photomicrographs of the tissues showing the pathology appears in the Photographic Appendix.

A second wild mink was received from Mr. Sini on the same day and from the same source as the mink which is discussed above. This mink was assigned Specimen No. 417. An autopsy of this animal revealed the right kidney to be infected by a male D. renale measuring 7 inches in length. The worm and the kidney were fixed and preserved in the same manner as was described in the case reviewed above.

A study of the pathology of the infected tissue was made relative to the migration route and the nature

of the infection. In this specimen which had only one parasite in the kidney, the same pathological condition of the kidney was observed, although, the total damage was not quite as extensive. This may be accounted for by the fact that there was only one worm present to cause damage. The infection may have been of a shorter duration.

More glomeruli were found in this right kidney and many of them appeared to be functional. Some of them were in a state of hyaline degeneration. Many of them were being squeezed by the proliferation of the subcapsular cells. The renal corpuscles which retained their identity were found in the outermost layer adjacent to the capsule.

The lining of the cavity in which the kidney worm was found consisted of thick pseudo-stratified transitional epithelium with hundreds of small finger-like papillae protruding into the lumen of the pelvis. In some instances, the major and minor calyces were still recognizable in spite of the fact that extreme papilliferous metaplasia was present in the same form as was described for the previous case. No collecting tubules were found which were in the normal condition of cuboidal epithelial linings. There were some breaks on the tips of the papillae in which there was evidence of cytolysis. Erythrocytes and leucocytes were found in the vicinity of the breaks indicating hemorrhage. The medullary and cortical layers were compressed into a comparatively narrow region near the periphery of the kidney. An

infiltration of collagenous and elastic types of connective tissue were scattered throughout the substance of the kidney. There was also an infiltration of lymphocytes and polymorphonuclear leucocytes. Holes which were apparently feeding paths of the adult worm were found in the tissue. Chalky incrustations or ossification deposits were absent in this case. This is frequently true when the infection is of short duration and in instances where only one worm is present. This infection was presumed to be one of rather short duration, 5 to 6 months, based upon the character of the infection and reports of earlier workers.

The pathology represents a progressive atrophy of the whole right kidney which ultimately results in the complete distruction of the functional value of the kidney and the tissues. The dysfunction of the right kidney often results in the hypertrophy of the left kidney to compensate for the increase in work which it is required to accomplish. Glomerulo-nephritis may result from the toxins produced by the infection. This may cause the left kidney to become damaged to the extent that it cannot eliminate the wastes from the body of the host. This would result in the death of the animal from uremic poisoning.

There were fibrous connective tissue strands connecting the right kidneys to the spigelian lobes of the liver in the two cases under consideration.

Adhesions of this nature were reported by McNeil (1948) in his work on the pathology of D. renale infections in the kidneys of mink. He reported that the infected kidney,

in some cases, joined the the muscles of the back by strands of connective tissue while other fibers of connective tissue sometimes linked the greater omentum and duodenum to the infected kidney. Also, in certain mink, the spigelian lobe of the liver was in direct contact with the infected kidney and joined to it by fibrous connective tissue.

The liver portions of these specimens were not preserved, therefore, no further report can be made regarding the pathology of the liver in the region of the attachment. In the normal anatomy, there is a direct connection between the liver and the right kidney, known as the ligamentum hepato-renale.

There is usually a great deal more fibrosus in the old and multiple infections. In those cases which were reported by McNeil (1948) and those cases which I have observed, the infiltration of fibrous connective tissue between the liver and kidney is much more than that which composed the ligamentum hepato-renale. There is no reason to believe that the parasite came from the spigelian lobe of the liver to penetrate and invade the kidney.

Examinations of the sectioned kidney tissue in this infection were made to determine the point of entry of the kidney worm. In the anterior portion of the kidney, slightly to the mesial side, was a region of fibrous connective tissue which extended away from the kidney to make contact with the spigelian lobe of the liver, the hepato-renale

ligament described above. There was a penetration through the capsule of the kidney and invasion paths lined by scar tissue in the cortex of the kidney. The path showed evidence of wandering, but finally ended in the pelvis of the kidney. There were signs of blood and lymph infiltration of the tissue, as well as fibrous infiltration, in the region of the migration paths. The point of penetration was where the first loop of the duodenum makes contact with the right kidney. There is normally no blood vessel which makes entry into the kidney in this region. The histology of the path is quite different from that of the blood vessels which enter and leave the kidney. Thus, there is no reason to believe that the etiology of this pathological condition could be anything other than the worm which was found in the pelvis of the kidney.

Two right kidneys of wild mink were received from Mr. R. E. Towne of Holderness, New Hampshire. The mink had been trapped by a member of the New Hampshire Department of Conservation at Sunset Point, New Hampshire. Specimen No. 412 was captured on November 6, 1950, and Specimen No. 413 was taken on November 3, 1950. The right kidneys which were infected by D. renale were removed from the carcasses and stored in water for shipment to these laboratories. The kidneys were received on November 14, 1950, and since they had been shipped in water, the kidney tissue was in very poor condition, unsuitable for any pathological examination.

The kidneys were opened shortly after their arrival. In the kidney of Specimen No. 412, there were 3 adult female D. renale and one male. All worms were dead, but in a turgid condition, vivid scarlet in color. The female worms were examined and were found to be gravid with a great supply of eggs, the majority of which were in the two-celled condition. These eggs were washed in water and washed again in a one percent formalin solution and finally washed in water. The eggs were stored at 5 degrees Centigrade in boiled, areated, and filtered water.

Specimen No. 413 was in a bad state of degeneration and decay. The worms, although they were dead, were in a fair state of preservation. The worms had lost their vivid red color and were a rust-brown. There were 4 females and 6 males in this right kidney, the largest multiple infection from a single right kidney to be encountered to this date. The females ranged from 11 to 16.5 inches in length and the males were from 7-to 8 inches long. The females were found to be gravid and the eggs were treated in the same way as were those from Specimen No. 412. The worms were fixed in Pick's Solution and preserved in Keiserling's Solution.

It was interesting to note the increase in size of the kidneys. The average size of the uninfected kidney of a wild mink is approximately 2.5 cm long and 1.5 cm thick. The right kidney of Specimen No. 413, which was very soft and putrid, containing 10 worms, measured

6.5 cm by 4.5 cm. The right kidney of Specimen No. 412 which was turgid and contained 4 worms measured 6.5 cm by 3.2 cm.

There were several small, stellate calcareous deposits imbedded in the little that remained of the parenchym of the kidney. The extreme papilliferous metaplasia could be seen in both kidneys. Little more than the capsule remained.

Ten mink carcasses were received from a commercial fur trapper in Benld, Illinois, during the trapping season of 1950-51. All were frozen and shipped to these laboratories during the months of December and January. They were autopsied and found free of any sign of infections by D. renale.

Part IV

Summary of Dioctophyma renale Infections in Animals Studied at the University of Michigan

Table III represents a summary of the infections by D. renale in mammals studied at the University of Michigan Department of Zoology from the first reported incidence. A total of 442 animals was studied and autopsied. The total of the animals may be subdivided into the following kinds: 429 mink, most of which came from the southern counties of Michigan; 7 ferrets which had been fed infective larvae of D. renale in experimental infections; 5 cats which had been fed experimental infective larvae; 1 dog. Of the animals studied, 43 were infected by the kidney worm, 9.2 percent. There were 84 D. renale adults recovered, 46 males for 54.76 percent and 38 females for 45.24 percent. Multiple infections were encountered in 18 cases, of these, 13 cases had both sexes present. There were 72 worms found in right kidneys of the hosts; 85.72 percent of the worms found in these infections. In the left kidney, 4 worms were found, 4.75 percent of the total number of worms. The remaining 9.53 percent were divided as follows in regards to their location in the final host at the time of autopsy: 4 worms free in the body cavity, 1 in the omentum, 1 partially emerged from the duodenum, 2 among the folds of the liver. Of 23 ranch-raised mink included in the total, 4 were infected. These were the mink that offered clues to the intermediate hosts and the ultimate solution of the life cycle of the kidney worm.

Only those animals where infections occurred are listed in the table. Information is furnished concerning the place of localization of the parasite at the time of autopsy. Also shown are data concerning the numbers of worms found and the numbers of each sex present in the infected animals. The Specimen Numbers assigned to each animal were designated by the workers at the time of autopsy and run serially from the date of the first animal examined in the laboratories in 1932 to the last in 1951.

Table III. Summary of D. renale infections in animals studied at the University of Michigan Department of Zoology.

Specimen No.	Males	Females	Totals	Localization in the Final Host
Wild mink				
1	2	1	3	Left kidney
56	1		1	Body cavity
57		1	1	Right kidney
103	3	2	5	Right kidney
136		1	1	Right kidney
146		1	1	Right kidney
147	4	2	6	Right kidney
176	1		1	Right kidney
194	2	1	3	Right kidney
201	1	2	3	Right kidney
203		1	1	Right kidney
213	1		1	Right kidney
214		1	1	Right kidney
221	1	1	2	Right kidney
222	1		1	Right kidney
239	1	1	2	Right kidney
249	2		2	Right kidney
252	1	1	2	Right kidney
254	1	3	4	Right kidney (3), Body Cavity (1)
262		1	1	Right kidney
268		1	1	Mesentery over right kidney
295	1		1	Right kidney
318		1	1	Right kidney
319		1	1	Right kidney
331	2		2	Right kidney
335	2		2	Right kidney
345		1	1	Right kidney
360		1	1	Right kidney
367	1		1	Right kidney
383		1	1	Right kidney
412	1	3	4	Right kidney
413	6	4	10	Right kidney
416	2		2	Right kidney
417	1		1	Right kidney
Ranch mink				
376		1	1	Body cavity
380	1		1	Right kidney
400		2	2	Right kidney
402	2	1	3	Right kidney
Dog				
411	1		1	Body cavity
Experimental Infections in ferrets.				
Case I	1		1	30 mm, head in mesentery, tail in duodunum
Case II	1		1	Left kidney
Case III	1		1	Right kidney
Case I (1949)	1	1	2	Among liver lobes, right kidney deformed.
Totals	46	38	84	

Discussion

Many investigators have postulated theories regarding the migration routes of the larvae of D. renale in the body of the mammalian host, the penetration of the kidney, and the normal localization of the parasite in the final host. The evidence for the suggested routes was based upon observations of natural infections. The interpretations of the observations may have been faulty due to the fact that little was known about the life cycle of the kidney worm. The larval stages were completely unknown to many of the early investigators, and speculations were based upon past experience with other nematode larvae. Little effort was made to study the pathology of kidney worm infections prior to the studies made by McNeil in 1942.. None of the theories of the migration route were founded upon experimental evidence. The source of infective larvae and their portal of entry into the body of the final host were unknown, although some workers suspected that the infective larvae were introduced into the body of the mammalian host by the ingestion of raw fish which served as an intermediate host. Thus, having little or no evidence regarding the portal of entry into the final host, no clues to the migration route to the kidney could be ascertained. The various theories and arguments as proposed by the early investigators will be presented and discussed in the light of evidence which has been revealed in more recent research.

Fish as the Second Intermediate Host of the Larvae of D. renale.

Balbiani (1869) described a worm, 92 cm long, taken from the body cavity of a dog. He stated that dogs, cows, horses, bison, and man served as the final hosts for the kidney worm. He suggested that fish might be the intermediate host. Ciurea (1921) reported an infection by D. renale in an experimental dog that he was using for an investigation on Opisthorchis. The dog was seven months old and had been laboratory reared and fed. Among many other fish from the Danube River, it was fed 14 specimens of Idus idus L. from November 4, 1913, to December 11, 1913. The dog died on March 13, 1914, without having exhibited any symptoms of illness. An autopsy of this animal revealed a female D. renale, 63 cm long and 7 mm in diameter. He believed that the fish, Idus idus L., fed to the dog on several occasions were the source of the infection. He formed his opinion on the following basis. Certain ichthyophagus aquatic birds were infected by nematodes of the genus Eustrongylides Jagerskiöld, nematodes of the same family as D. renale, by eating Idus idus L. If this idea were accepted, then the source of infections by D. renale in man in Germany, Prussia, and in the fishermen of the Danube River who consumed Idus idus L. in almost raw condition, could be accounted for. In further support of his hypothesis, Ciurea reported that an examination of the fish in question revealed many small nematodes moving with apparent ease through the muscles. These worms were interpreted to be

the larvae of D. renale. Lutz (1924) took issue with the theory that a fish served as the intermediate host. He believed that such animals as cattle and horses in which D. renale had been reportedly found did not eat fish.

The above theories concerning the fish as an intermediate host serve to point out that the portal of entry into the body of the final host and the source of infection were matters of considerable speculation with little basis in fact. Woodhead (1945) reported that fish served as the intermediate host and confirmed the ideas of some of the earlier workers. Although Ciurea achieved an infection by the kidney worm in one of his experimental animals, his contention that Idus idus L. was the intermediate host is not necessarily true. Any one of the many different kinds of fish which were fed to the dog may have contained the infective larva. It is not disputed that Idus idus L. may be a suitable intermediate host. The small nematode larvae that Ciurea described in the muscles of the fish do not fit the characters of the larval D. renale as described by Woodhead (1950). Ciurea describes the larval nematodes as follows: the body cylindrical and of a nearly uniform size, measuring 1.715 mm long by 0.068 mm in diameter; the anterior end truncated and bearing four small protuberances; the posterior end a little pointed; the cylindrical esophagus occupying more than one-quarter of the total body length and connecting with the intestine by means of a bulb; the genital outline in the form of a reinforced refractile corpuscle. The

infective larvae of D. renale were described as follows: body cylindrical and of nearly uniform diameter, measuring 10 mm long; pointed at the tail and with little head differentiation; esophagus occupies nearly one-half of the total body length and connects with the intestine with a fold of the intestine overlapping the posterior end of the esophagus for a fairly straight junction; anus terminal. The differences are self-evident and little further justification is necessary for the contention that the larvae described are not the same. Ciurea's report was interesting, however, from an entirely different standpoint. It suggested to later investigators the length of time necessary for the infective larva to develop to the adult stage and laid the groundwork for future investigations.

Since horses have been known to eat anything, Lutz' theory may be omitted from the discussion with the observation that the cases from horses are few in number and may be considered accidental. A horse may swallow a small infected fish while drinking water from a stream. The same idea may apply to all cases of kidney worms being found in non-fish-eating mammals.

Migration of the Pre-adult Larvae of D. renale Through the Uro-genital System to the Right kidney of Mammalian Hosts.

The earliest speculation regarding the migration route of D. renale was made by Stratton in 1843. He suggested the method of entry into the body of the final host was made through the uro-genital system. Sonsino (1897) suggested that the larvae entered the final host through

the uro-genital aperture, gaining access to the peritoneal cavity by passing through the funnels of the fallopian tubes.

The first and most obvious question to ask in rebuttal to this argument would be for a reasonable explanation of the presence of kidney worms in male animals. The fallopian tubes, if any are present in male animals, are in the form of mere remnants and serve no useful purpose. They would not lend themselves well to a migration of the infective D. renale larvae. Woodhead (1950) has shown conclusively that the parasites are ingested with food taken by the mammalian host, therefore, the idea of a migration through the uro-genital system may be discounted. Their contention of a uro-genital migration had some justification since the eggs of D. renale are found in the urine. Adult worms are found in the pelvis of the kidney in many instances, therefore, it is quite possible that young adults could be forced into the ureter and other portions of the uro-genital tract. Fragments of cuticles may also be carried from the kidney to other parts of the urinary system, but these facts cannot be construed as indicating a part of the migration route in the light of the evidence revealed in more recent research.

Migration of the Pre-adult Larvae of D. renale Through the Liver and Body Cavity to the Right Kidneys of the Mammalian Hosts.

Ejsmont (1936) postulated the theory that the migration through the liver was the cause of the high percentage of right kidney infections and was the usual method of reachi

the right kidney. He believed all other localizations to be abnormal. Stefanski, Strankowski, and Nagorski (1936) supported Ejsmont's theory of migration through the liver, but concluded that localizations in the body cavity of the host were also normal. Lukasiak and Strankowski (1935) expressed the opinion that a final molt took place in the kidney of the mammalian host. They reported several infections by the kidney worm in which the parasite had localized in regions other than the right kidney. Stefanski and Strankowski (1936) reported an instance of the penetration of the right kidney of a dog by an adult kidney worm. The worm was a large female found partially looped among the lobes of the liver and with the anterior portion in the right kidney, which appeared to be normal in all other respects. The left kidney showed no signs of hypertrophy. There were signs of migration throughout the body cavity in the form of coagulated blood, cysts on the surface of the liver, and disintegrating eggs. The anterior 13 cm of the worm was in the pelvis of the kidney and the remaining 55 cm of the body length was jutting into the body cavity. The canal into the kidney was 4 cm long and 1 cm in diameter. The point of penetration was 5 cm from the anterior apex of the kidney. The reporting authors assumed that in as much as the worm had completed its stay in the abdominal cavity, it was in the process of entering the kidney, its site of final residence. On June 3, 1927, Lukasiak discovered a similar case in which the perforation was discovered near the urinary duct. The

anterior 4 cm of the parasite was within the right kidney of the dog. There was a large number of massed eggs inside the kidney. Lukasiak and Strankowski (1935) reported another parallel case concerning a kidney worm which had made a hole, 8 mm deep and 6 mm in diameter, in the right kidney of a dog. Another case was reported by these authors concerning an adult female kidney worm in a dog. The right kidney was normal with the exception of a hole, 10 mm deep and 2 mm wide, leading to the interior. They cited another case which was similar in all respects to those mentioned above. Stefanski and Strankowski (1936) were of the opinion that the larvae, upon ingestion by a mammal suitable to their further development, penetrated the blood vessels of the stomach and were carried to the liver where they were filtered out by the small capillaries. They underwent a tremendous increase in size then left the liver to complete their development in the body cavity, and penetrated the kidney by hollowing out the thickness of the organ only after they had completed the last molt. Lukasiak and Strankowski (1935) suggested that the penetration of the kidney as mentioned above could be a secondary entry of the parasite into the kidney following a rupture of the renal capsule which had permitted its escape into the body cavity. They believed that the frequency of the adult worms in the abdominal cavity was not in accord with the necessity for the parasite to shed its eggs outside the body of the host. They believed that a successful migration in so far as a continuance of the species was concerned could not end in the body cavity.

It is quite possible for the host animal to be eaten, and it is quite likely that the eggs could remain viable until the death of the host. The eggs would then be afforded an opportunity to be washed from the body into water in which they could continue their development and have access to the first intermediate host.

Lukasiak and Strankowski (1935) believed that the localization in the body cavity, in spite of its frequency, was only accidental and the result of the rupture of the renal capsule. The presence of the parasite in the body cavity, they believed, involved a lesion at the time of its entry into the kidney. They had found excavations of the parenchyma caused by adult kidney worms. The parasite, having entered the kidney, left traces of its migration path on the liver and mesenteries. They stated that these traces often showed the point of copulation during the stay in the abdominal cavity. Lukasiak (1930) reported that fertilized eggs were found in the peritoneum and that the females were already in the kidney at the time of autopsy of the host. Lukasiak and Strankowski (1935) reported that they had never found young forms in the kidney. The youngest, a female, 13 cm long, was found in the kidney.

Ejsmont (1936) provided many arguments in opposition to those of the Polish authors. He pointed out that the cases of the entry into the kidney by the adult worm were repetitious. He stated that there were actually only two

cases of the kind they reported, and by repeating the descriptions of these, without making reference to the original reports, caused one to believe that there were many more cases than was actually true in which a parallel situation existed. This resulted in more consideration being given to the evidence than should have been accorded it. Ejsmont accounted for the presence of the adult worms making entry into the kidney by the supposition that they were delayed forms that had lost their way in migration and had not penetrated the kidneys in the usual way. He believed that the young forms were often found in the pelvis of the kidney without any evidence of a penetration from the outside. He did not report making any study of the pathology of the kidneys in order to determine a pathway. He believed that the larval kidney worms entered the kidney when they were very small and left no evidence of an entry point. He pointed out that there were many larvae known to be present in the liver. His theory of migration may be summarized as follows: the larva entered the blood stream in the stomach wall or in the intestinal wall and was filtered out of the blood by the small capillaries in the liver; it underwent a single molt in the liver and migrated from the spigelian lobe of the liver directly into the kidney. He believed that the high percentage of kidney worms in the right kidney was due to the topographical relationship between the liver and the right kidney. Any worms which failed to make the transition between the two organs developed as body cavity forms.

I find many points of disagreement with the theories and arguments as presented by the authors mentioned above. Most of them accepted the idea of a migration through the blood stream. It is evident that their idea of the size of the infective larva was erroneus. A 10-mm larva would experience considerable difficulty, because of its size, in a migration to the liver of the kidney via the blood stream. The chances of there being the high percentage of infection in the right kidney would be significantly reduced if the migration were dependent upon the blood stream.

In regard to the cases of adults entering the right kidney, I believe that they represented chance encounters with the kidney in feeding migrations of body cavity forms.

Lukasiak (1930) reported the presence of fertilized eggs in the body cavity with females present in the right kidney. There is no reason to believed that those particular females were responsible for the eggs found in the body cavity. There may have been a simultaneous infection of both the kidney and the body cavity by different worms. An instance of this type has been reported in the past. The female worm or worms, as the case may be, could have shed eggs, died and disintegrated in the body cavity, accounting for the presence of the eggs and the absence of worms. Some accounting must be made for the fact that the eggs were fertilized and no male was present in the kidney. There should be evident signs of a penetration of the kidney left by an adult female worm, which often reaches a length of a meter in dogs. Pathology of this kind would be difficult

to overlook if the tissues were examined carefully and in complete detail.

Included in the theories stated above was the statement that many young forms were found in the liver. It is my opinion that the worms referred to as kidney worm larvae were actually larval forms of Ancylostoma, Ascaris, or Strongyloides.

Migration of the Pre-adult Larvae of D. renale to the Right Kidneys of the Mammalian Hosts Via the Blood Stream.

Stefanski and Strankowski (1936) suggested briefly the possibility that the infective kidney worm larvae entered the blood stream and were carried to the kidney where they were filtered out by the capillaries, and remained indefinitely. They abandoned this hypothesis when they found it to disagree with their 'migration through the liver' hypothesis.

The question of migration through the blood stream has been previously discounted in this paper, based upon the relatively large size of the infective larva.

Migration of the Infective Larvae of D. renale to the Right Kidneys of the Mammalian Hosts Directly from the Duodenum.

It seems likely that the high percentage of infections in the right kidneys of the Mustelidae, the group of mammals that contains the definitive host, has some significance, and is greater than would be expected by chance meeting in the feeding migration throughout the body cavity.

It is believed that the topographical relationship of the first loop of the duodenum and the right kidney accounts, in part, for the high incidence of infections of the latter. In mammals, in general, and in the Mustelidae

in particular, the first loop of the duodenum is in the form of a tight, abrupt turn back upon itself, forming a kind of trap. This trap-like bend in the duodenum is so situated that it lies adjacent to and in close contact with the anterior portion of the kidney that is not covered by the spigelian lobe of the liver. The loop lies in the curvature of the kidney formed by the hilus. It is in this region that the migration through the intestinal wall is believed to take place. The migration is continued directly through the kidney capsule and into the kidney.

The number of successful migrations through the duodenum in the region of contact with the right kidney is dependent upon several factors. The first factor is the amount of food present in the stomach of the mammalian host at the time of ingestion. If there should be a large amount of food in the stomach, it is possible that the excystment would take place and an opportunity afforded to the larva to make a migration through the stomach wall. A migration through the wall of the stomach would result in a body cavity form. If the migration were begun through a region of the stomach which is covered by the lobes of the liver, the worm would be found among the folds of the liver or entwined through them. Worms have never been found entirely within the liver. The liver is lacking a tough capsule, therefore, the worm is not confined as it is in the kidney. In kidneys from which adult worms are removed, there is a thickening of the capsule by tough fibrous and granular tissue. There is often calcification and ossificati

which serve to restrict the parasite to the kidney. The source of food for the body cavity forms is believed to be blood from the vessels of the body wall. There is seldom much evidence of hemorrhaging in cases where body cavity forms have been encountered. A second factor to be considered, concerning the beginning point of migration, is the age of the larva at the time of ingestion. An older form may not be as active or there may be a reduction of the facility of the penetration glands which would result in a penetration being made through other parts of the digestive tract. These penetrations would result in body cavity forms. A third factor considered in the migration from the digestive tract is the case of the stomach of the host being nearly empty at the time of ingestion and excystment of the larva. In cases of this type, the chances are that the penetration would be made in the region of the duodenum adjacent to the hilus of the right kidney. and the migration would be into the right kidney. Chitwood (1941) suggested that the instinct for burrowing was lost by some nematodes after the third molt. This factor may account for some of the body cavity forms. The number of molts has not been determined for D. renale.

The case of the 30-mm larva was quoted as evidence for the fact that migrations are made through the duodenum. The case was the result of an experimental feeding reported by Woodhead (1950). The larva began its migration through the duodenum in the region of the first lymph node. A portion of the omentum was carried by the parasite into the body

wall to form a pocket. Having attained a position where it was receiving an adequate supply of blood, the larva remained until the resultant peritonitis caused by the seepage of blood and intestinal contents killed the ferret. The posterior portion of the worm was still in the duodenum, indicating that the worm had made the penetration.

Evidence was found which substantiates the theory of migration into the right kidney from the first loop region of the duodenum. The pathology of the infected right kidneys from two wild mink, Specimen Numbers 416 and 417, revealed the points of migration into the right kidney. The migration paths were found in the mesial portion of the kidney, on the side nearest the midline of the body of the mink and in the region which makes contact with the first loop of the duodenum, midway between the anterior apex of the kidney and the hilus. There was evidence of hemorrhagic infarction. The pathology of these migrations was discussed in detail earlier in this paper.

The following case is reported as additional evidence to support the theory that a migration is made into the kidney in the region of direct contact between the kidney and the duodenum. The case was reported by Graham and Mark (1949). "A year old English bulldog showed symptoms observed initially on February 4, 1949. There was haematuria, marked frequency of urination and convulsive shivering. The dog failed to respond to symptomatic treatment and was hospitalized on February 16th with a tentative diagnosis of haemorrhagic cystitis. The animal was anemic (Hb 8.9 gms.), showed a

palsy-like convulsion of the head and was obviously in considerable pain. Examination of the urine sediment revealed Dioctophyma renale eggs. Following transfusion, a nephrectomy of the right kidney was performed. It contained a female worm measuring 86 centimeters. The anterior pole of the kidney was perforated; the capsule thickened, outpouched and perforate. Areas on the serosa of the abdominal viscera were covered with granulation tissue. Recovery was uneventful." The symptoms have a marked similarity to those which I found for Ferret No. One, an experimental infection. It should also be noted that a perforation was reported in the anterior region of the kidney.

All of the evidence revealed by my investigation indicates that the probable route of migration of the larval kidney worm in the body of the mammalian host is by the most direct method. The larval worm is ingested by the final host. An emergence is made from the cyst in the stomach. The larva is passed through the pyloric sphincter into the duodenum. The worm is very active at this point because the change in temperature from its previous location in the fish. It may also be very active because of the change in the pH of its new environment and because it is released from the cramped spaces of its limiting cyst. This activity was observed when the larvae were excysted in artificial gastric juice which was warmed by the heat from a small electric light bulb. When cooled the larvae became inactive. The abrupt turn

Explanation of Plate VI

Diagram of the migration of the infective larva to the right kidney in numerical stages.

1. Ingestion of the cyst of D. renale.
2. Excystment of D. renale larva in the stomach.
3. Passage of the larva through the pyloric sphincter.
4. Entry of larva into duodenum.
5. Point of migration through the duodenum wall.
6. Migration into the right kidney.
7. Place of final localization in the right kidney.

The arrows on the stomach wall indicate points of penetration and the possibility of body cavity infections.

Key to Labels

S. -- Stomach

L. -- Liver

PS. -- Pyloric sphincter

SL. -- Spigelian lobe

D. -- Duodenum

RK. -- Right kidney

LK. -- Left kidney

U. -- Ureter

VC. -- Vena cava

Plate VI

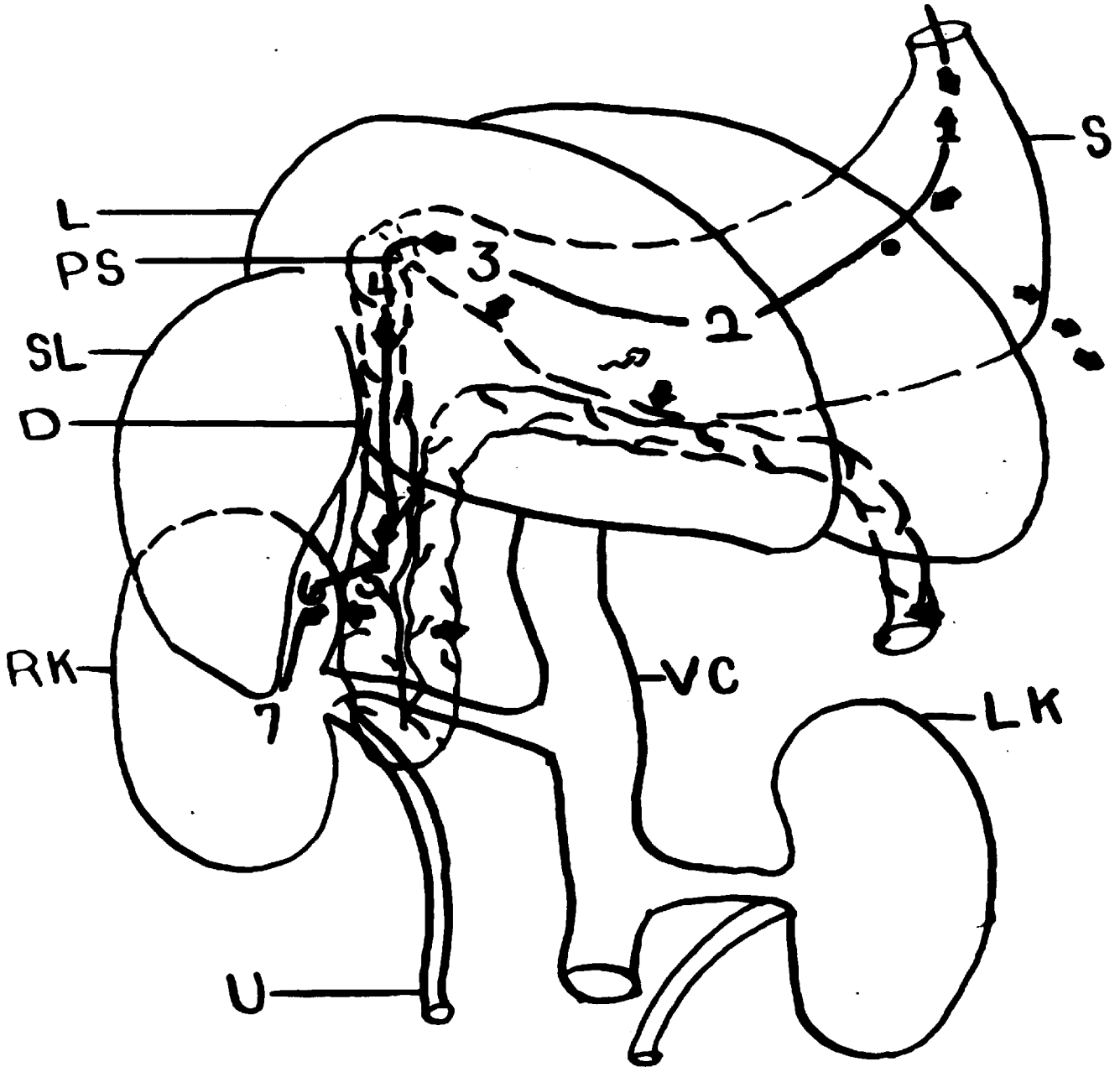

Plate VI. Diagramatic sketch of the visceral anatomy of the Mustelidae showing the topographical relationships of the organs and the steps in the migration route of the pre-adult larva of D. renale to the right kidney.

in the duodenum, in the region of the right kidney, forms a kind of barrier to further passage. The worm migrates into the portion of the kidney which lies adjacent to the duodenum and continues its development within the confines of the right kidney. Plate VI is a diagramatic sketch of the anatomy of a typical Mustelid in the region where the migration occurs. The probable migration route is numbered in the consecutive phases. The diagram serves to indicate the topographical relationships of the various organs of the viscera.

D. renale Migration in Dogs Versus Mink.

In mink, the percentage of right kidneys which are infected by the kidney worm is much higher than infections in the right kidney of dogs. Lukasiak (1930) reported that 24.4 percent of dogs examined with kidney worm infections had body cavity forms. Riley (1916) reported 44 percent body cavity forms in cases reported from North America. Records of mink and other Mustelidae which were infected by D. renale and autopsied at the University of Michigan indicated that of 84 worms found, 11 were in organs other than the right kidney, 11.9 percent. There were 42 parasitized animals and 8 of them had kidney worms in organs other than the right kidney, 14.2 percent. Of these, 3 had some signs of injury to the right kidney.

I believe that the difference in percentages of kidney worms found in the right kidneys of dogs and mink can be traced directly to the fact that the topographical relationships between the visceral organs of the dog and

the relationships of one organ to another in the Mustelidae are different. In mink, the relationship of the duodenum to the right kidney is much more intimate than it is in dogs. The bend which forms the barrier in the duodenum of mink is much more cramped and effective as a block to the passage of the larvae than is the case in dogs. Less chance may be afforded to the larvae to make intimate contact with the wall of the duodenum in the region near the kidney of the dog. This may be the result of the larger diameter of the duodenum of dogs. The larger stomach provides the larvae with a greater opportunity to make a penetration through the wall of the stomach and migrate into the body spaces and lobes of the liver before it is forced into the duodenum. All these factors may contribute to the reduction of the number of kidney worms found in the right kidneys of dogs.

An Unusual Kidney Worm Migration in a Ferret.

The nature of the infection of the right kidney in the case of the experimental Ferret No. Two offers little evidence for a solution of the migration route. The pathology of the infected kidney is different from a kidney in which the parasite has taken a pelvic residence as a final localization. The invasion of the kidney had apparently been made from opposite poles. The residence period was spent in the parenchyma of the kidney as opposed to the usual pelvic localization. The invasions may have originated in the adjacent duodenum, but there was no immediate evidence to indicate the origin of the migration paths.

The direction of the migration paths through the kidney and exit through the liver were determined by the difference in the diameters of the tunnels. The larvae were 10 mm long at the time of their introduction into the final host, and measured 10.3 and 17.8 cm long, respectively, when they were recovered at autopsy. This rapid growth took place in 55 days. The time that the worms spent in the kidney was ample for an appreciable growth. I believe that the worms were the etiological agent for the pathological condition of the right kidney.

Cytolysis in Migration.

It was established by Hoeppli, Feng, Hsü, and others that there were cytolytic enzymes present in the head and esophageal glands of nematodes. If this is true for D. renale, it would explain the ability of the larvae to penetrate the duodenum and migrate through the various visceral organs. The larva has no teeth, stylet, or muscular apparatus for chewing or tearing and, therefore, must depend upon lytic action for migration through the tissues.

In studies of the infected tissues, evidence of cytolysis was present in the form of tunnels and excavations in the affected organs with no evidence of chewing or tearing. There were signs of cytolysis in the pelvic mucosa. It is still unknown how long the glands remain as functional penetration organs in the migrating larvae. Stefanski and Strankowski (1936) suggested the strong lytic action of the esophageal gland enzyme as the

mechanism for the penetration of the kidney. The paths of entry into the kidney which were discovered in this investigation have indicated lytic action.

Immunity to D. renale.

An immunity to further infections when the mammalian host is infected is suggested by the fact that in cases of multiple infections, the worms are all of the same age and size commensurate with their sex. Since this is true, the immunity must be established shortly after the entry of the parasite. Attempts to infect an animal which was already infected have failed.

Why D. renale Migrate to the Kidney.

The reason for the migration to the kidney is one of speculation. Fülleborn (1929) reported thermotaxis among some nematodes. Larval worms were attracted to a heat source by this tropism. It is unknown whether there is a sufficient gradient of heat differential among the various visceral organs to account for the migration to one organ as opposed to another. The threshold of sensitivity to temperature is a matter of speculation. There may be some organotropism, chemotropism, or noise tropism such as is exhibited by certain mosquitos searching for blood vessels in the skin. Instinct may be considered, a difficult thing to use or explain in a scientific argument. There may be inherited characteristics that cause an organism to behave in a definite pattern from which there is little or no deviation. All of these offer interesting opportunities for speculation and further research.

Summary

The evidence found in this investigation provides considerable support to the theory of probable migration of larval D. renale in the body of the mammalian host from the duodenum in the region where it makes contact with the right kidney. A migration is made through the duodenum and a penetration of the kidney is made through the duodenum on the side nearest the midline of the body of the host at a point in the anterior portion of the kidney between the hilus and the anterior apex. Migrations into two right kidneys were found to be in the regions described above.

The pathology of the migration indicates a lytic action upon the tissues which are invaded, with little evidence of mechanical injury such as chewing or tearing. There is a resultant production of scar tissue and granulation tissues. In the regions of migration into the kidneys, there is evidence of hemorrhagic infarction, connective tissue production, and cytolysis.

The pathology of the infected right kidneys reveals extreme papilliferous metaplasia, thickened pseudo-stratified epithelium in the pelvic cavity in which the parasites are found at autopsy. The parenchyma is found to be excavated and tunneled, and, in some instances, nearly lacking. The glomeruli, if any remain, are found in the little remaining medullary and cortical layers in the periphery near the kidney capsule. The glomerular tufts are compressed

by the encroaching subcapsular cells which are, in some cases, completely obliterating any sign of the normal glomeruli. The kidney capsule is composed of thickened fibrous connective and granular tissue.

The pathology of the hypertrophied left kidney shows glomerulo-nephritis, hyaline disintegration, hemorrhagic infiltration, and enlargement of the glomeruli as well as enlargement of the kidney as a whole.

The larvae are infective during the months of July and August and non-infective in May and June.

Bibliography

Balbiani, E. G. 1869b. (Strongle géant trouve dans le péritoine d'un chien) (Secretary's abstract) Compt. Rend. Soc. Biol., Paris, v. 20, 4. s., v. 5 : 227-228.

_____1869c. Researches sur le développement et la propagation du Strongle géant. Compt. Rend. Acad Sc., Paris, v. 69 (21). Nov. 22 : 1091-1095.

_____1874. (Oeufs des Strongles géants recueillis dans le péritoine d'un chien) (Secretary's abstract) Compt. Rend. Soc. Biol., Paris, v. 26, 6. s., v. 1 (1), Jan. - Apr. : 125.

Barthelmy, A. 1858a. Etudes sur le développement et le migrations d'un nématöide parasite de l'oeuf de la Limace grise. Ann. Sc. Nat. Zool., 4. s., v. 10 (1) : 41-48.

*Bartholinus, T. 1670a. Sanguis verminosus. Misc. Acad. Nat. Curios., v. 1 : 147-149.

*Bremser, J. G. 1819a. Ueber lebende Würmer in lebenden Menschen. Ein Buch für ausübende Aerzte. Mit nach der Natur gezeichneten Abbildungen auf vier Tafeln. Nebst einem Anhange über Pseudo-Helminthen. 284 pp., Wein.

Brown, H. W., Sheldon, A. J., and Taylor, W. W. 1940. The occurrence of Dioctophyme renale in dogs of North Carolina. J. Parasitol. 26 Suppl. : 16.

*Caesalpinus. 1519-1603.

Cameron, T. W. M., Parnell, I. W., and Lyster, L. L. 1940. The helminth parasites of sled dogs in northern Canada and Newfoundland. Canad. J. Res., 18 : 325-332.

Chitwood, B. G., and others. 1940. An introduction to nematology. Sect. I, (3) : 125-240. Monumental Printing Co., Baltimore, Md.

Ciurea, I. 1921a. Sur la source d'infestation par l'Eustrongle géant, (Eustrongyle gigas Rud.). Compt. Rend. Soc. Biol., Paris, v. 85 (21), 23 Juillet : 532-534.

*de Clamorgan, J. 1583.

Collet-Meygret, G. F. H. 1802a. Mémoire sur un ver trouve dans le rein d'un chien. J. de Phys. Paris, v. 55 : 458-464.

Dunne, H. W. 1940. A case of Dioctophyma renale in a dog. Vet. Student, 2 : 115-116.

Ejsmont, L. 1936a. Dépendance causale entre la localisation du Strongle géant, Dioctophyme renale, et le évolutives dans l'hôte définitif. (French text) Roczn. Prac. Nauk. Zrzesz. Asyst. Uniw. J. Pilsudsk. Warszawie, Wydz. Wet., v. 1 (2) : 473-485.

Erickson, A. B. 1944. Helminths of Minnesota Canidae in relation to food habits and a host list and key to species reported from North America. Am. Midland Natur., v. 32 : 358-372.

_____1946. Incidence of worm parasites in Minnesota Mustelidae and host lists and keys to North American species. Am. Midland Natur., v. 36 : 494-509.

Fülleborn, F. 1929c. On the larval migration of some parasitic nematodes in the body of the host and its biological significance. J. Helminth., v. 7 (1), : 15-26.

*Goeze, J. 1782. Versuch einer Naturgeschichte der Eingewedewürmer thierischer Körper. 471 pp. Blankenburg.

Graham, G. L., and Mark, J. H. 1949. Giant kidney worm, Dioctophyma renale in a dog. J. Parasitol., v. 35, No. 6 (2) : 15.

Graves, E. F. 1937. Dioctophyme renale in mink. J. Am. Vet. Med. Assoc., v. 90, n.s., v. 43 (4) : 531-532.

Janicki, M. J. 1934b. Contribution la biologie Dioctophyme renale (Goeze, 1782). Mem. Acad. Polon. Sc. et Lett., Cracovie Cl. Math. et Nat., s. B: Sc. Nat. (6) : 279-285.

*Klein, J. T. 1755a. Tentamen herptologie, cum perpetuo-commentario: accessit J. A. Unzeri observatio de taeniis, Latine reddita cum dubiis circa eandem. 72 pp. Leidae et Gottingae.

Lukasiak, J. 1930a. Anatomische und Entwicklungsgeschichtliche Untersuchungen an Dioctophyme renale (Goeze, 1782), (Eustrongylus gigas Rud.). Arch. Biol. Soc. Sc. et Lett. Varsovie, v. 3 (3) : 1-100.

_____1932. Nerkowiec olbrzymi (Dioctophyme renale) Czasopismo, Przyrodnieze, livr. 1-2, 6 pp.

Lukasiak, J., and Strankowski, M. 1935. Kilka rzadkich

przypadków Dioctophyme renale (Goeze, 1782). W worganizmie psa. Quelques sac interessants de Dioctophyme renale (Goeze, 1782) trouvé dans le cavité abdominale du chien. (Polish text; French summary) Wiadom Wet., (174) Rok 17, v. 14 : 7-19.

Lutz, A. 1901a. Ueber Befund von Eustrongylus gigas in einen neuen Wirte. Zentralbl. Bakteriol., 1. Abt., v. 29 (6), 25 : 256-257.

McNeil, C. W. 1948. Pathological changes in the kidney of mink due to infection with Dioctophyma renale (Goeze, 1782), the giant kidney worm of mammals. Tr. Am. Micr. Soc., v. 67 (3) : 257-261.

Meyer, M. C., and Witter, J. F. 1950. The giant kidney worm, (Dioctophyma renale), in mink in Maine with a summary of North American records. J. Am. Vet. Med. Assoc., v. 114 (878) : 367-369.

Moore, M. C., and Schooley, M. A. 1939. Dioctophyme renalis in a dog. Vet. Med., v. 34 : 452-453.

Morse, E. V. 1945. Verminous ascites in a dog. Cornell Vet., 35 : 281-282.

Patterson, E. E. 1936. Another specimen of Dioctophyme renale. J. Am. Vet. Med. Assoc., v. 88 : 184.

Randall, R. 1944. Giant worms in the kidney of a dog. Bull. U. S. Army Med. Dept., (72) : 9-10.

*Redi, F. 1684. Osservazioni interno agli animali viventi che si trovano negli animali viventi. 2 p. 1 : 253 pp. Firenze.

Riley, W. A., and Chandler, W. L. 1916. Occurrence of a giant nematode on the liver of a dog. Cornell Vet., v. 6 : 209-212.

*Rudolphi, C. 1802. Beschreibung des Strongylus gigas Beitr. Z. Anat. u Physiol. d. Thiere, Bremen, 1. Heft : 115-116.

Sealander, J. A. 1943. Notes on some parasites of mink in southern Michigan. J. Parasitol., v. 29 : 361-362.

*Sonsino, P. 1897. Di alcuni eliminti raccolti e osservati di recenti in Pisa. Atti. Soc. tosc. disc. nat., Pisa proc. verb., v. 10 : 253-259.

Stefanski, W. 1928. Quelques précisions sur les caractères specifiques de Strongle géant dans le rein droit du chien. Ann. Parisitol. Humaine et Comp., v. 6 (I) : 93-100.

Stefanski, W., and Strankowski, M. 1936. Sur un cas de pénétration du Strongle géant dans le rein droit du chien. Ann. Parasitol. Humaine et Comp., v. 14 (1) : 55-60.

Stefanski, W., Strankowski, M., and Nagorski, F. 1936. Nowy przypadel wystepowania nerkowea olbrzymiego (Dioctophyme renale) w. jamie piersiowej u kota. Wiadom. Wet., (191) : 219-224.

Stratton, T. 1843. On the existance of entozoa in the shut cavities of living animals. Edinb. Med. and Surg. J. (156), v. 60 (3) : 261-262.

Underwood, P. C., and Wright, W. H. 1934. A report of the giant nematode, Dioctophyme renale, from a dog with a

summary of American records. J. Am. Vet. Med. Assoc., v. 85 : 256-258.

*Wallisneri, A., and Hartmann, P. J. 1685.

Wislocki, G. 1919. Observations of Dioctophyme renale in dogs. J. Parasitol., v. 6 : 94.

Woodhead, A. E. 1941. The life cycle of Dioctophyma renale, the giant kidney worm of mammals. J. Parasitol., v. 27 Suppl. : 25.

_____1945. The life history of the giant kidney worm, the giant kidney worm of man and many other mammals. J. Parasitol., v. 31 Suppl. : 12.

_____1950. The life history of the giant kidney worm, Dioctophyma renale (Nematoda), of man and many other mammals. Tr. Am. Micr. Soc., v. 69 (1) : 21-46.

Woodhead, A. E., and McNeil, C. W. 1939. Dioctophyma renale, the giant kidney worm, occuring in mink from the southern counties of Michigan. J. Parasitol., v. 25 Suppl. : 23.

* Those references listed above which are preceded by an asterisk have been cited in the text of this paper, but were not actually seen in the original published form. They were cited from Lukasiak (1930) and McNeil (1948).

Photographic Appendix

Explanation of Plates

The following photographs are included in order to provide some pictorial evidence of the findings reported in the text of the paper. All of the photographs are original unless otherwise credited.

The photographs which appear on the first two plates were taken during the autopsy of Ferret No. I. The photographs appearing on Plate IIIa and two of those that appear on Plate IVa show the migration path into the right kidneys of wild mink, Nos. 416 and 417. One photograph on Plate IVa, and all of the photographs on Plate Va, show the path of migration through the duodenum made by a 30-mm larva which was found by Woodhead (1950) in an experimentally infected ferret. I made the study of the infected tissues. Plates VIa, VIIa, VIIIa, IXa, and Xa show the pathology of the migration and localization of the worm.

Through the courtesy of Dr. Verne B. Kniskern, the photographs of a typical right kidney infection are included on the last two plates.

Plate I.

Fig. 1. Photograph taken at the autopsy of Ferret No. I showing the young female kidney worm free in the body cavity as it appeared when the abdomen was opened.

Fig. 2. The liver lobes have been moved to show the worm literally laced through the lobes of the liver and to show the deformity of the right kidney in the form of a blister-like cyst which may be observed on the lower distal side. Ferret No. I.

Plate Ia



Fig. 1.



Fig. 2.

Plate II.

Fig. 3. The small male kidney worm entwined in the median lobe of the liver of Ferret No. I. Very little of the body other than the anterior end and the tail were exposed.

Fig. 4. The 7-inch and 4-inch female and male kidney worms as they appeared in a relaxed condition after being removed from the body cavity of Ferret No. I.

Plate IIa



Fig. 3.



Fig. 4.

Plate III.

Fig. 5. Migration into the right kidney of a wild mink, in the anterior region midway between the hilus and the apex of the kidney. Note the tunnels and connective tissue. Evidence of hemorrhage may be seen. Mink No. 417. 100 X.

Fig. 6. Invasion of right kidney of wild mink No. 416. 100 X.

Fig. 7. Penetration of the right kidney of wild mink No. 417. 200 X.

Plate III.



Fig. 5.



Fig. 6.



Fig. 7.

Plate IV.

Fig. 8. Migration out of the duodenum of an experimentally infected ferret. A 30-mm D. renale pre-adult was found one-half emerged from the duodenum through this hole by Woodhead (1950). Note the path through the muscularis layer and partly in the submucosa. 200 X.

Fig. 9. Migration into the right kidney of wild mink No. 416. 200 X.

Fig. 10. Another section of the migration path shown in the figure above. 200X.

Plate IV.



Fig. 8.



Fig. 9.



Fig. 10.

Plate V.

Fig. 11. Migration through the duodenum of an experimentally infected ferret in which a 30-mm kidney worm was found. 200 X.

Fig. 12. Another section of the same tissue. 200 X.

Fig. 13. Another section of the same tissue. 100 X.

Plate V.



Fig. 11.



Fig. 12.



Fig. 13.

Plate VI.

Fig. 14. Papilliferous metaplasia in the cavity of the right kidney of a wild mink in which D. renale were found. Note the reduction of the regions of the parenchyma and the thickened lining. Mink No. 416. 100 X.

Fig. 15. Papilliferous metaplasia lining the cavity in which D. renale were found in the right kidney of a wild mink. Note the compression of the parenchyma of the kidney and the absence of glomeruli. Note the layer of adipose tissue covering the kidney. Mink No. 416. 100 X.

Fig. 16. Same pathology as described above as found in wild mink No. 417. 100 X.

Plate VI.



Fig. 14.



Fig. 15.



Fig. 16.

Plate VII.

Fig. 17. Papillae lining the cavity in which the kidney worm was found, showing the thickened epithelium, pseudo-stratified transitional type. Mink No. 417. 200 X.

Fig. 18. Glomeruli of an infected right kidney showing the glomeruli near the periphery of the kidney and the destruction of part of the field. Mink No. 417. 200 X.

Fig. 19. The same glomeruli enlarged to show the pathology of degeneration. 400 X.

Plate VII.



Fig. 17.



Fig. 18.



Fig. 19.

Plate VIII.

Fig. 20. Glomeruli which were being encroached upon by subcapsular cells with a resultant compression of the capillary tuft and eventual atrophy of the functional unit of the kidney. Mink No. 417. 400 X.

Fig. 21. Glomeruli of the same infected kidney which at the time of autopsy had not yet been totally destroyed, but shows signs of degeneration. Mink No. 417. 860 X.

Fig. 22. Enlargement of the pseudo-stratified transitional epithelium which lines the cavity in the right kidney in D. renale infections. Mink No. 417. 860 X.

Plate VIII.



Fig. 20.



Fig. 21.



Fig. 22.

Plate IX.

Fig. 23. Glomeruli of an uninfected, but hypertrophied, left kidney of a ferret which was experimentally infected by two larval D. renale. The young adults were recovered among the lobes of the liver, but had been within the right kidney. Note the enlargement and degeneration. Ferret No. I. 400 X.

Fig. 24. Enlargement of one of the glomeruli shown in the section of tissue shown in the figure above. 860 X.

Plate IXa



Fig. 23.



Fig. 24.

Plate X.

Fig. 25. A portion of the infected right kidney of Ferret No. I. showing the portal of entry into the posterior pole of the kidney and the excavation in the parenchyma. 40 X.

Fig. 26. Tunneling in the parenchyma of the kidney in the region of the excavation in the parenchyma. Note the lining is not the typical transitional epithelium found in the pelvic infections. Ferret No. I. 40 X.

Plate X.



Fig. 25.



Fig. 26.



Fig. 27.

Plate XI.

Fig. 28. A photograph of the right kidney of an experimentally infected ferret. Note the apparent lack of parenchyma and the distention of the kidney capsule. Note the proximity of the first loop of the duodenum to the right kidney. The topographical relationships have been partially distorted since the intestines were moved slightly to the left to expose the right kidney.

Fig. 29. The same kidney excised to show the kidney worm within the kidney pelvis. Note the thickness of the kidney wall, which shows the lack of any remaining parenchyma.

Plate XIa



Fig. 28.



Fig. 29.

Plate XII.

Fig. 30. The kidney worm removed from the kidney shown in the previous photograph.

Plate XIIa



Fig. 30.